



GLOBAL JOURNAL OF MEDICAL RESEARCH

Volume 11 Issue 2 Version 1.0 July 2011

Type: Double Blind Peer Reviewed International Research Journal

Publisher: Global Journals Inc. (USA)

Online ISSN: 0975-5888

Evaluation of Pattern of Magnetic Resonance Images of Lumbo-Sacral Spine in Cameroon - A Pioneer Study

By Dr. Felix U. Uduma, Dr. Pierre Ongolo, Dr. George Assam,
Dr. Pius Fokam, Dr. Mathieu Motah

University of Uyo, Nigeria

Abstract - Rationale : Low back pain is a common debilitating disease with negative effect on productivity. Magnetic resonance imaging (MRI) with its excellent soft tissue contrast and absence of bone artefact is the current modality used in evaluating the possible aetiologies of low back pain. MRI availability in Central Africa is recent, with only two existing machines including the newly installed one in Polyclinic Bonanjo, Douala.

Aim : To evaluate lumbo-sacral spine MR images with elucidation of possible causes of low back pain.

Methodology : A pioneer prospective study of patients who were referred to Department of Radiology, Polyclinic Bonanjo, Douala, Cameroon for MRI of the lumbo-sacral spine from June –November, 2009 was done. Equipment used was 0.3Tesla Hitachi AIRIS 11. Sagittal, coronal and axial images were acquired. When indicated T1W-Gd-DTPA and STIR were adjunctive sequences used. Patients with either claustrophobia or having MRI incompatible medical implants were excluded.

Results : 48 Patients with age range 20-79 years with mean age of 49.5 were studied. Males were 29(60.4%) and females were 19 (39.6%). The commonest aetiology of low back pain was disc hernia 16(33.3%) with 62,5% occurring at L4/L5 disc level while 25% was at L5/S1. Gender difference decreases with age.

Conclusion : Thus disc herniation is the commonest cause of low back in Cameroon, often accompanied by spondylosis.

Keywords : Lumbo-sacral spine, MRI, Low back pain

GJMR Classification : NLMC Code : WE 725



Strictly as per the compliance and regulations of:



Evaluation of Pattern of Magnetic Resonance Images of Lumbo - Sacral Spine in Cameroon - A Pioneer Study

Dr. Felix U. Uduma^α, Dr. Pierre Ongolo^Ω, Dr. George Assam^β, Dr. Pius Fokam^ψ, Dr. Mathieu Motah^γ

Abstract – Rationale : Low back pain is a common debilitating disease with negative effect on productivity. Magnetic resonance imaging (MRI) with its excellent soft tissue contrast and absence of bone artefact is the current modality used in evaluating the possible aetiologies of low back pain. MRI availability in Central Africa is recent, with only two existing machines including the newly installed one in Polyclinic Bonanjo, Douala.

Aim : To evaluate lumbo-sacral spine MR images with elucidation of possible causes of low back pain.

Methodology : A pioneer prospective study of patients who were referred to Department of Radiology, Polyclinic Bonanjo, Douala, Cameroon for MRI of the lumbo-sacral spine from June –November, 2009 was done. Equipment used was 0.3Tesla Hitachi AIRIS 11. Sagittal, coronal and axial images were acquired. When indicated T1W-Gd-DTPA and STIR were adjunctive sequences used. Patients with either claustrophobia or having MRI incompatible medical implants were excluded.

Results : 48 Patients with age range 20-79 years with mean age of 49.5 were studied. Males were 29(60.4%) and females were 19 (39.6%). The commonest aetiology of low back pain was disc hernia 16(33.3%) with 62,5% occurring at L4/L5 disc level while 25% was at L5/S1. Gender difference decreases with age.

Conclusion : Thus disc herniation is the commonest cause of low back in Cameroon, often accompanied by spondylosis.

Keywords : Lumbo - sacral spine, MRI, Low back pain

I. INTRODUCTION

Low back pain is a common referral in routine MRI practice and also a common integral part of the clinical history of patients who present for spinal magnetic resonance imaging (MRI) [1] Imaging serves to bolster the notion that low back pain (LBP) is nothing more than the symptom of an underlying disease.[2]., However, determining the cause of back pain is complicated as it is often multi-factorial and anatomical abnormalities are common in the spine which may not

necessarily translate into clinical symptoms [3]. LBP is associated with a wide range of clinical disorders. The commonest group is mechanical disorders, which occurs in more than 90% of all episodes of back pain. [1]. 10% of the remaining patients with back pain have symptoms related to systemic illness like cancer, inflammatory back disease including sacroiliac arthritis or infection [1]

The use of plain radiographs to evaluate patients who have low-back symptoms is indicated when the symptoms have persisted for more than four to eight weeks and are associated with pain at night or at rest[4]. These radiographs are used primarily to rule out infection, malignant lesion, fracture, and inflammatory conditions [4]. Negative results may help to reassure the patient that no major pathological condition exist [4]. But conventional radiography alone cannot conclusively assess the soft tissues of the spine. Thus newer technologies have been quickly adopted with the hope that they will improve our understanding of the physiopathology of the disease and assist us in alleviating patients' pain and discomfort [5]. Such technology is MRI, which is the gold-standard and preferred imaging modality for evaluation of most of the spinal lesions. This is because of its superiority in soft tissue contrast, non-invasiveness, multi-planar imaging capabilities and lack of productions of ionizing radiations] [3,6,7]. The high resolution of MRI for soft tissues allows elucidation of the morphology of the inter-vertebral disc, the nerve roots, the contents of the central spinal canal, foraminae and the facet joints [3]. Coronal and sagittal acquisitions can easily be made unlike computed tomography (CT) that needs reconstruction to reproduce similar images. CT imaging may be unwarranted and may also be objectionable for younger women, since it may unnecessarily exposes patients to ionizing radiation[8] The current guideline designate MRI as the first choice of investigation of herniated nucleosi pulposi and suggested CT as the alternative in the evaluation of lumbar back pain if MRI is contraindicated or unavailable[9]. Besides herniated disc, the direct evaluation of nerve roots by MRI has been considered an important asset to facilitate decision making in patients with back pain [9]. The presentation of lesions in LBP involving various lumbar

Author^α : Department of Radiology, Faculty of Clinical Sciences, University of Uyo, Nigeria. Correspondence : P O BOX 6092, ABA, NIGERIA. E-mail : felixuduma@yahoo.com

Author^Ω : Department of Radiology, University of Yaounde, Cameroon.

Author^β : Department of Radiology, Polyclinic Bonanjo, Douala, Cameroon.

Author^ψ : Orthopedic Unit, Department of Surgery, University of Buea, Cameroon.

spinal structures as well as sacroiliac joint often overlap and are clinically indistinguishable, necessitating evaluation by MRI[1]. Magnetic resonance imaging (MRI) is increasingly requested for people with LBP and has diverse utility in evaluating spinal lesions connected to LBP [3]. It has an acknowledged role in diagnosing serious spinal pathology, planning surgical management in cases of radiculopathy and spinal stenosis [3]. MRI has been tested as a screening tool to assess the risk of people in different occupations developing LBP [3] MRI plays a useful role in patients with early disease, by its superior ability to directly image changes in articular cartilage [1]. It has revealed lumbar disc abnormalities in up to three-quarters of asymptomatic subjects, including those with no previous history of LBP, sciatica or neurogenic claudication [3] MRI of the spine is useful for detecting occult compression of the spinal cord or cauda equina in patients with skeletal metastases and back pain, allowing treatment to be instituted before the onset of neurological complications. [3]. It is also the technique of choice on evaluation of bone metastasis as it is sensitive to early marrow changes that precedes osteoblastic response in the bone matrix of some malignancies [10].

However, low specificity limits the diagnostic utility of MRI scans[2] It cannot be used to predict back pain which are insensitive to anatomical changes that might correlate with new symptoms[2] Imaging can also lead to the identification of pathology unrelated to a patient's LBP[or find patho-anatomical abnormalities that have little or no correlation with patient symptoms[8]. The current role of MRI in back pain is encapsulated in the RCR (Royal College of Radiologists) guidelines and the joint clinical practice guidelines from the American College of Physicians and the American Pain Society.[3] The guidelines discourage routine imaging in patients with non-specific LBP and counsel reserving its use for cases in which severe or progressive neurological deficits are present or serious underlying conditions are suspected[3].

II. AIMS

To analyse the MRI findings of the lumbo-sacral spine so as to evaluate the commonest pathologies in low back pain in Cameroon.

III. MATERIALS AND METHOD

a) Patients

Forty-eight patients with an age range 20-79 years with low back pain underwent MR imaging during a period from June, 2009 to November, 2009. All patients were evaluated in detail by clinical and spine examination prior to MRI lumbo-sacral region. The eligibility criteria included (a) the chief complaint of

LBP- encompassing idiopathic, mechanical, inflammatory, infective, post operative causes, others and not merely to mechanical or inflammatory group. This was done intentionally to include a large cohort referred for MRI lumbar spine. (b) there was no contraindications to MR imaging (e.g. pacemaker, aneurysmal clips, foreign body in globe etc).

b) MRI Protocol

MR imaging was performed at our hospital, using 0.3 Tesla Hitachi AIRIS 11 MRI machine, and spine phased-array coil. Technical factors used were T1W, T2W, STIR. Sagittal acquisitions were used in screening while axial and coronal were used to evaluate the neural foramina. This was followed by T2 STIR images acquired in oblique coronal and sagittal planes. Enhanced T1W images with Gadolinium pentate dimeglumine were used in cases of intra-spinal mass lesion or to evaluate herniated disc lesions where T2W images were degraded.

Technical specifications included a slice thickness of 3 and 4 mm for sagittal and axial sequences, respectively; a field of view of 26 and 20 cm for the sagittal and axial images, respectively; and a matrix of 192 by 256. The T₁- and T₂ weighted axial sequences were stacked slices extending from the inferior aspect of L3 through the inferior aspect of S1.

c) Data Collection and Results

Forty-eight patients with an age range 20-79 years with mean age of 49.5 years with low back ache underwent MR imaging during a period from June, 2009 to November, 2009. Quantitative results were analysed using SSPS PC.

Males were 29(60.4%) and females 19(39.6%). Males to female ratio of the studied population was 1.5:1. The patients referred were not from a single clinical specialist source, but from multiple specialties like orthopaedics, paediatrics, rheumatology, neurology, neurosurgery and general medicine. The highest number of studied cases belonged to 50-59 year age range with 31.25%, and male to female ratio of 1:1.14. The second highest studied range is 40-49 years (29%) with male to female ratio of 1:0.4. The commonest pathology is disc hernia, 16 cases (33.3%) with male to female ratio of 3:1. Spondylosis without any evidence of disc hernia was high with 12 cases (25%). 62.5% of herniated disc occurred at L4/L5 disc level followed by 25% at L5/S1 disc level. At L4/L5 level male to female ratio is 4:1 while it is 1:1 at L5/S1

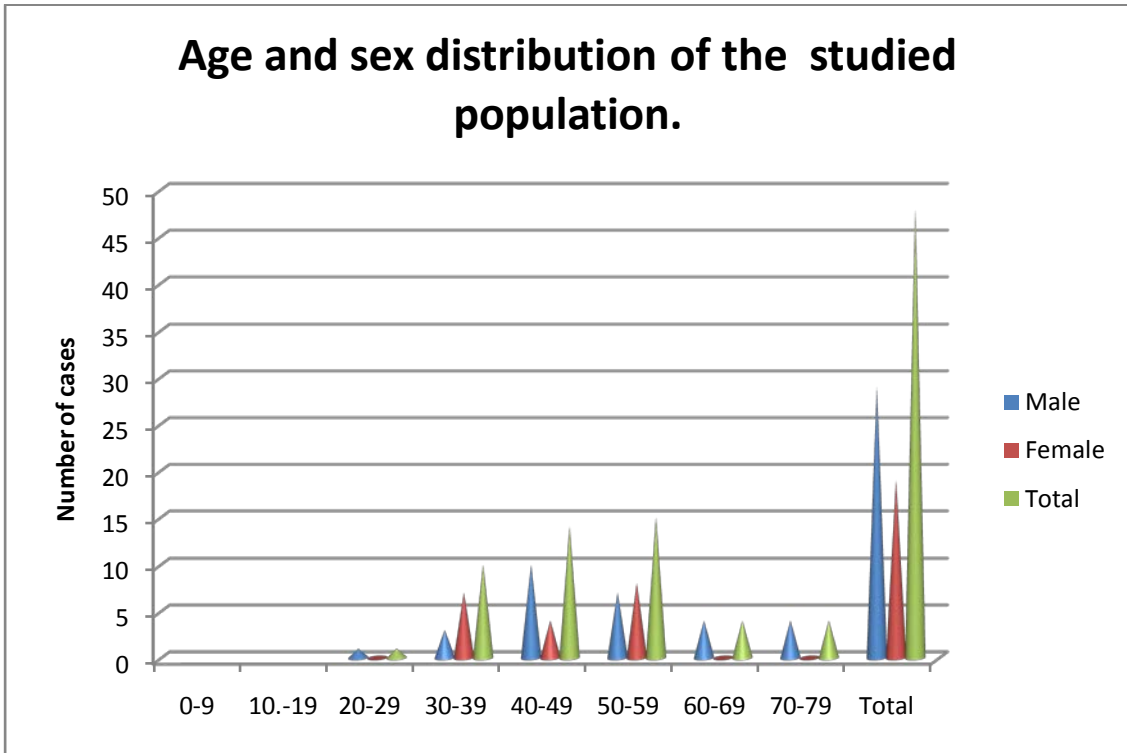


Fig. 1

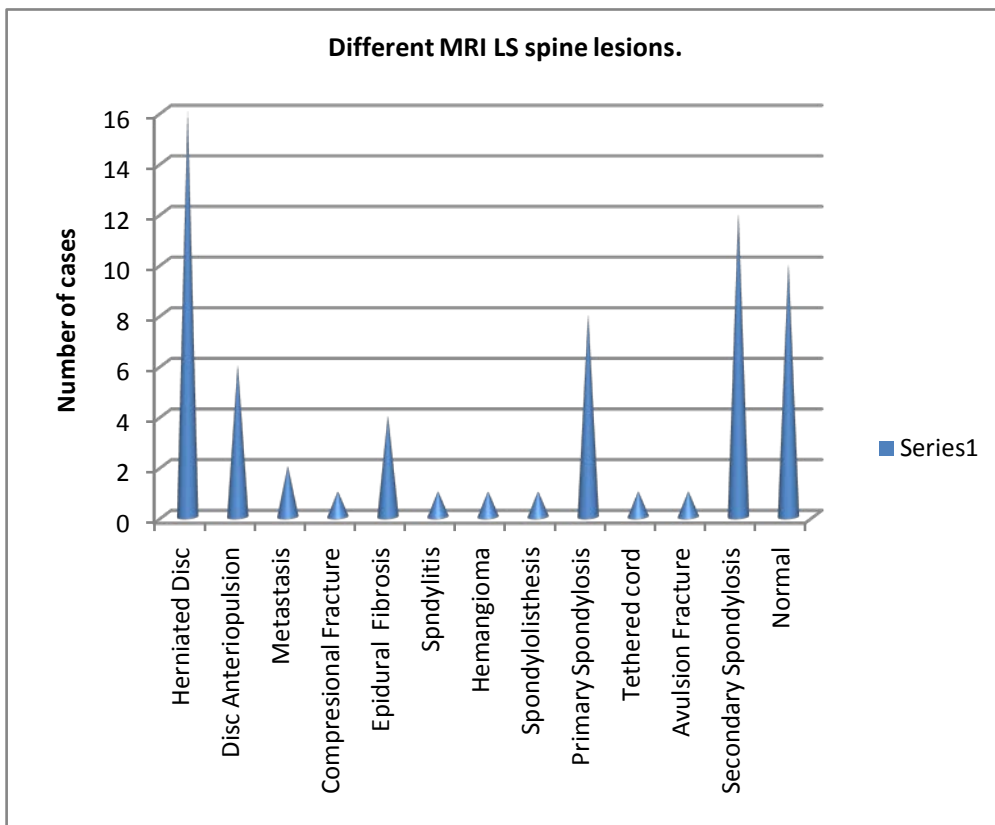


Fig. 2

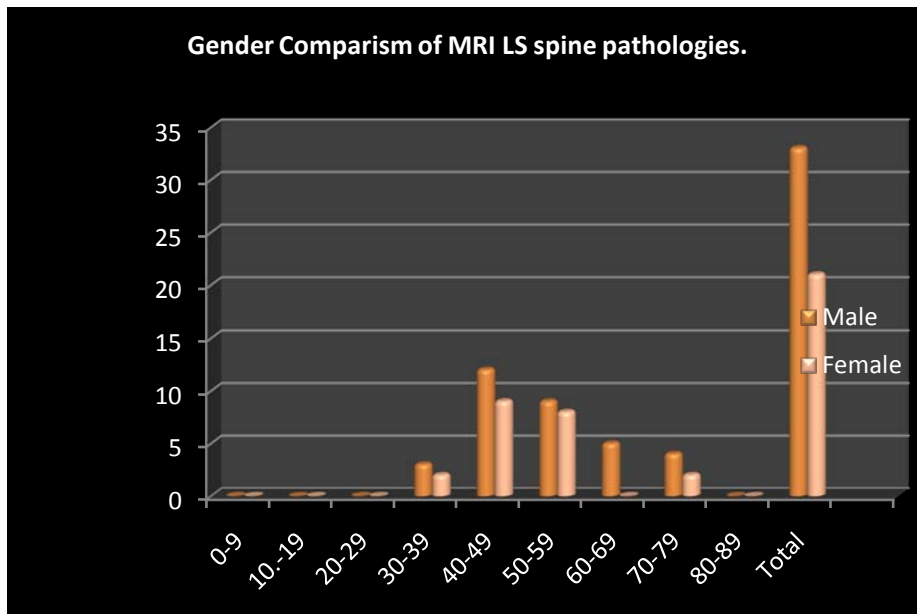


Fig. 3

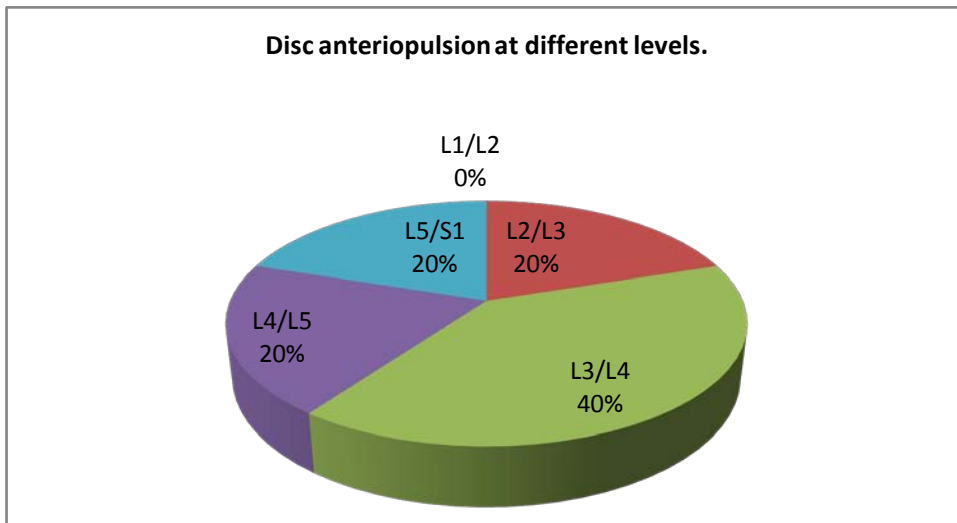


Fig. 4

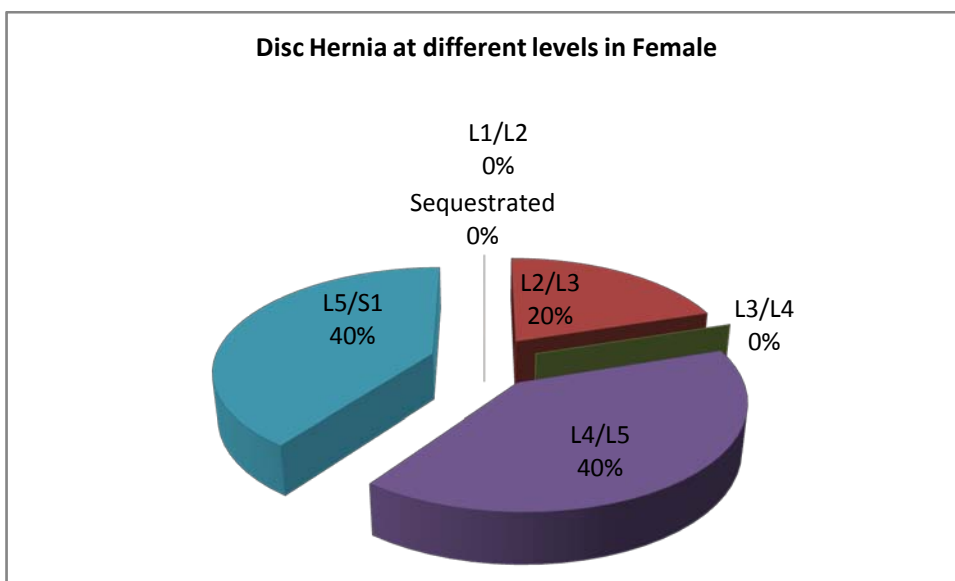


Fig. 5

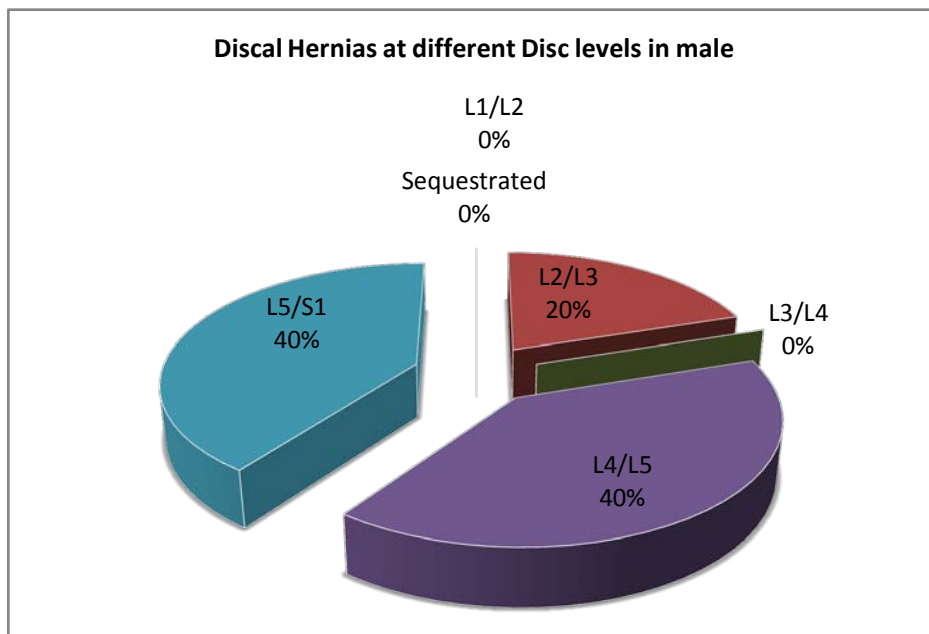


Fig. 6

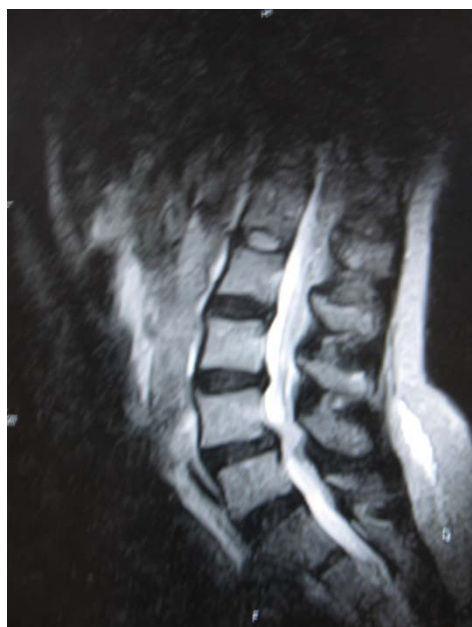

Fig. 7 : Mid - sagittal T1W MRI showing L3/L4 disc hernia.

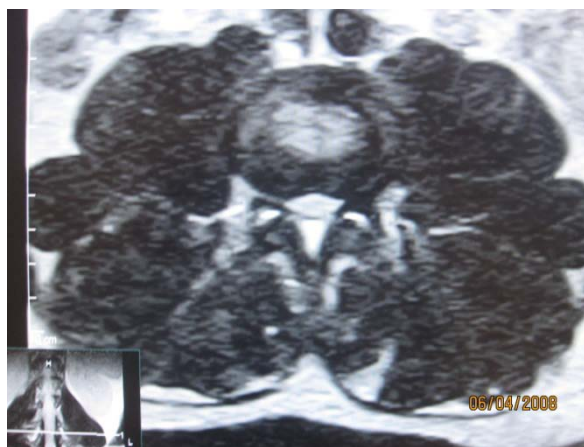

Fig. 8 : Axial T1W showing Lumbar stenosis and left nerve root compression



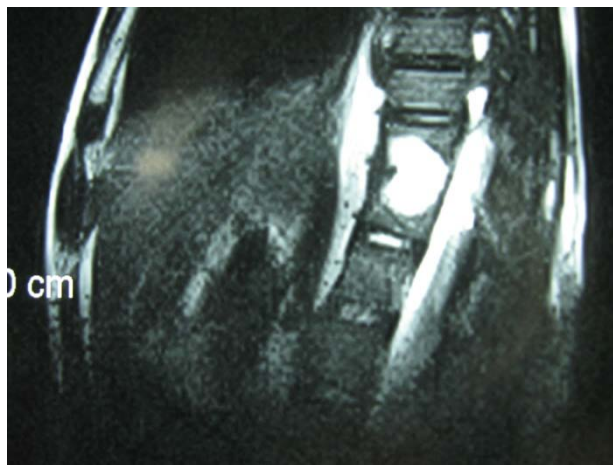


Fig. 9 : Midsagittal T2W MRI showing hyperintense lesion

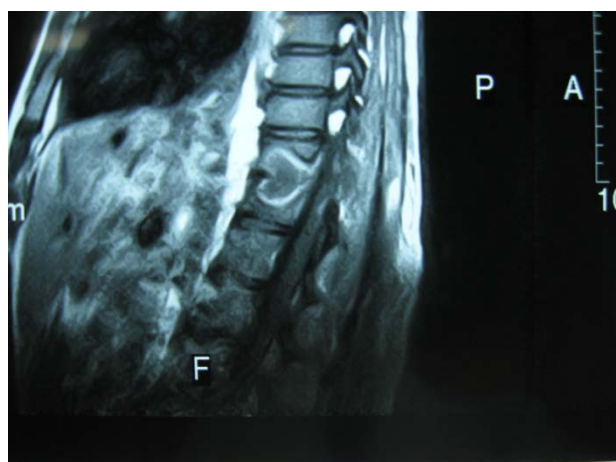


Fig. 10 : Mid-sagittal Enhanced T1W MRI showing ring enhancement of the above Spondylo-discitis affecting two contiguous vertebrae of Spondylo-discitis

IV. DISCUSSION

Low backache is a common clinical presentation in medical practice and MRI centres [1]. It has been observed that in any 12-month period in USA, 15% to 20% of the population has an episode of lumbo-sacral pain.[1,4]. In a larger context, the prevalence of back pain over the course of lifetime in the entire population of industrialised societies is more than 70 percent.[4,11]. For example, the lifetime prevalence of LBP is approximately 80 percent in Americans [11]. LBP is second only to the common cold as the reason patients cite for seeking medical care [11].

This pioneer prospective MRI study is paramount because of paucity of such documentations in central African region. Our centre is the second MRI centre in Central African region and the earlier machine in another centre had broken down without any documentations of MRI findings related to LBP. MRI defines the lumbo-sacral spine diagnosis with high specificity allowing the most approximate therapeutic decisions [9].

Back pain is the most frequent cause of limitation of activity among individuals who are less than forty-five years old.[4]. Our largest studied population with low back pain, 31.25% was in the 50-59 age range with male to female ratio of 1:1.14. This is followed by 29% in the 40-49 age range with male to female ratio of 1:0.4. This agreed with high incidence of low back pain in the work force with attendant negative impact on productivity and economy [1]. Annually, back symptoms occur in 50% of working age adults in USA [1]. Each year, there are approximately 500,000 Workers' Compensation and personal-injury cases dealing with low-back pain [4]. In this study, detected number of pathologies outweigh the number of studied population. This is because multiple pathologies can exist in one patient.

a) *Disc Lesions :*

The high signal intensity of the cerebrospinal fluid and epidural fat in T2W sequence makes T2W sequence the most useful in evaluation of discal lesion, which is dominant pathology as in our study [9]. The commonest pathology in this study is disc hernia with 16 cases (33.3%) with male to female ratio of 3:1. 10 cases (62.5%) of herniated disc occurred at L4/L5 disc level followed by 4 cases (25%) at L5/S1 disc level. At L4/L5 level male to female ratio is 4:1 while equal male to female ratio is seen at L5/S1 level. This predominance of disc herniation at L4/L5 and L5/S1 levels is supported by previous study [12] The reducing gender difference is accounted for by the increasing degeneration, laxity, demineralisation and desiccation with ageing in both sexes [9]. This is corroborated by the articular facet degenerative changes seen in almost all cases of disc herniations shown as height reduction and subluxation of the ligamentum flavum of the facet joints[9,12].

Disc herniation can be used to describe a wide spectrum of abnormalities involving disk extension beyond the interspace, from a bulge to a frank extrusion and sequestration; [11]. The terms used to classify disks were defined as follows: normal, no disk extension beyond the interspace; bulge, circumferential symmetric extension of the disk beyond the interspace (around the end plates); protrusion, focal or asymmetric extension of the disk beyond the interspace, with the base against the disk of origin broader than any other dimension of the protrusion; and extrusion, more extreme extension of the disk beyond the interspace, with the base against the disk of origin narrower than the diameter of the extruding material itself or with no connection between the material and the disk of origin[9,11]. Sequestered disc are free disc fragment which may migrate below or above the interspace [6]. On MRI examination of the lumbar spine, many people without LBP have disk bulges or protrusions but not extrusions, thus discovery by MRI of bulges or protrusions in people with LBP may frequently be coincidental [11]. There is a hypothesis that the prevalence of extrusions in people with symptoms of LBP may be substantially higher than in people without symptoms [11]. Sequestered or free fragment has high T₂W signal because their increased water content produces an increase in signal intensity [6]. When it is behind the parent disc, it is round in configuration but oblong on further separation [6]. Annular defects or fissure which can be demonstrated by MRI as decreased signal on the T₂-weighted image may be a fore-runner to disc hernia and are frequently asymptomatic[11] But any pain, possibly results from leakage of the contents of the nucleus pulposus into the epidural space, with related nerve irritation[11]. The reported prevalence of posterior radial tears at autopsy in asymptomatic people is 40 percent for those between the ages of 50 and 60 years and 75 percent for those between 60 and 70 [11].

In our study, no distinction was made between disc protrusion and extrusion, rather cases where there is protrusion of disc anteriorly and behind anterior longitudinal ligament was considered separately and termed disc anteropulsion. 6 cases (12.5%) anteropulsions were seen. Using MRI in 67 people without symptoms, Boden et al. found herniated disks in 20 percent of the people less than 60 years old and in 36 percent of those 60 years of age or older [11]. But our study included symptomatology criterion and discovered 60% of patients 60 years and above had disc hernia. Low back ache is one of the most common causes of morbidity in elderly patients and could be due to multiple aetiologies like degenerative-inflammatory lumbar spinal pathology [2,13] Multiple levels of disc hernia was seen in 56.25% of our patients. MRI examination of 41 women without symptoms showed that 54 percent had a disk bulge or herniation at one or more disk spaces, although only L3-4, L4-5, and L5-1 levels were examined [11].

b) *Lumbar Stenosis :*

MRI is the preferred investigation for confirming lumbar disc herniation, nerve root entrapment, radiculopathy, and spinal canal stenosis [3]. Lumbar spine stenosis (LSS) is subdivided into relative and absolute LSS according to the anterior-posterior diameter of the spinal canal (physiological value is 22–25 mm) [7]. Relative LSS is when spinal canal measures 10–12 mm in diameter and usually asymptomatic. Whereas absolute LSS (spinal canal < 10 mm in diameter) is often symptomatic and is associated with absence of free subarachnoid space [7]. The lateral recess can also be considered in LSS definition (physiological diameter is 3–5 mm) and stenosis is considered if it has a diameter of < 2 mm [7]. 32(66.66%) of our studied population had lumbar stenosis. LSS can be mono-segmental or multi-segmental, and unilateral or bilateral. Patho-anatomically, stenosis can be classified as central, lateral or foraminal. This is often the sequelae of degenerative disc hernia [7]. Herniated disc is classified into central, centro-lateral and lateral, the commonest is centro-lateral. [6]. Laterally herniated discs and smaller focal disc herniations may be difficult to diagnose with only sagittal imaging. Axial imaging will help and has become a routine examination protocol to assess the degree of lateral, neural canal, nerve root and cord involvement [12]. Depending on the extent of the degeneration, central, lateral and foraminal stenosis can occur alone or in combination. The L4–5 spinal discs are most frequently affected by LSS, followed by L3–4, L5–S1, and L1–2[7]. This highest occurrence of lumbar stenosis at L4/L5 is noted in our study with disc hernia being the predominant culprit. The frequency of degenerative LSS diagnosis has risen over time, as a result of increasing lifespan and demand for a better

quality of life, awareness of the disease, and the availability of advanced imaging techniques. [7].

Multiple factors can contribute to the pathogenesis of spinal stenosis, and these can act synergistically to exacerbate the LSS [7]. Central stenosis results from degeneration and protrusion of the disc, which leads to ventral narrowing of the spinal canal [7]. Foraminal stenosis is a consequence of disc degeneration, with further reduction of the height of the intervertebral space, leading to narrowing of the recess and intervertebral foramina, exerting strain on the facet joints [7]. Such an increase in load leads to facet joint arthrosis, hypertrophy of the joint capsules and the development of expanding joint cysts (lateral stenosis), which in combination propagate spinal instability [7]. Central stenosis is further contributed by the reduced height of the segment and the ligamenta flava forming creases, which exert pressure on the spinal dura from the dorsal side [7]. Concomitant instability due to loosened tendons (for example, the ligamenta flava) further propagates pre-existing hypertrophic changes in the soft tissue and osteophytes, creating the characteristic trefoil-shaped narrowing of the central canal. [7]

The clinical features of the condition are heterogeneous, and often, include neurogenic claudication which comprises limping or cramping lumbar pain that radiates into the legs primarily during walking [7]. Degenerative LSS can ultimately lead to the compression of individual nerve roots, the meninges, the intraspinal vessels, and, in exceptional cases, the cauda equine [7]. Nerve root compression triggers localized inflammation, which affects the nerve root's excitatory state. [7]—In addition, two interdependent vascular mechanisms are hypothesized to assist in the development of neurogenic claudication in LSS: reduced arterial blood flow resulting in ischemia, and venous congestion with compression of the nerves and secondary perfusion deficiency [7]. — Conversely, compressive radiculopathy can cause autonomic dysregulation and impaired circulation in the legs [7]. The extent of compression is increased by hyperextension or hyperlordosis of the lumbar spine, because these postures cause additional narrowing of the spinal canal. [7]. Where as hyperflexion abrogates lordosis, resulting in a widening of the spinal canal [7]. The development of cauda equina syndrome, which comprises sacral hypesthesia, loss of tendon reflexes in the lower limbs and incontinence, as a result of LSS is only found in exceptional cases [7] In cases of lateral recess stenosis or foraminal stenosis, isolated radiculopathy can occur [7].

c) Epidural Fibrosis :

Epidural fibrosis and recurrent or persistent disc herniations are the two most common causes of failed back syndrome, seen in 10-40% of post surgical

patients[6]. Pre- and post-enhancement T1W images are very sensitive in this differentiations since fibrosis enhances and recurrent disc does not[6]. 6.25% of our studied population had epidural fibrosis.

d) Spondylosis :

It is well known that magnetic resonance imaging is the most sensitive imaging method for the evaluation of spinal degenerative pathology, even in the initial stages of the disease [14]. Many authors have believed that a degenerated disc is the most likely source of chronic, disabling LBP (discogenic pain, internal disc disruption [4]

Degeneration of the lumbar spine occurs in three phases : dysfunction (progressive tearing of the annulus fibrosus, degeneration of the nucleus pulposus, and arthropathy of the facet joints), instability (laxity of the facet joints, ligaments, and discs), and restabilization (formation of osteophytes and hypertrophy of the facet joints [4]. 18(37.5%) of our studied population had spondylosis. Spondylosis was subdivided in our study into primary or secondary with a ratio of 1:1.57. Secondary spondylosis is predated by a pre-existing aetiologies like mechanical impact on a vertebra, spondylolysis and spondylolisthesis. [6,12] This is commonest in the lumbo-sacral spine[12]. MRI features of spondylosis are disc cartilage loss in height with T2W hypointensity of dessication, T1W linear signal void of vacuum phenomenon in the disc cartilages, osteophytosis, end-plate sclerosis, marrow changes sometimes schmorl's nodules.[6,7]. MRI accurately delineates the cardinal features of spondylosis, like changes in joint space width and symmetry, presence of erosions, subchondral edema, spondylophytes, sclerosis, cysts and ankylosis [1]. MRI sensitivity of end-plate changes for discogenic pain is low[3] Furthermore, Comparative studies between MRI and CT in the evaluation of sensitivity and specificity of MR for the detection of cortical erosions and subchondral sclerosis when compared to CT images were 100 and 94.3%, respectively[1]. .

e) Spondylolisthesis

Whenever a spinal disc vertebrae slips to the front or the back of the spine in comparison to the other vertebrae it is termed "spondylolisthesis"[15]. It is commonest at L4 on L5[16] When the vertebrae goes forward in the spine it is known as "anterolisthesis" and whenever the vertebrae goes backward in the spine it is known as "retrolisthesis" [15,16]. Both anterolisthesis and retrolisthesis are spinal defects that can cause the patient pain in the back. [15] There are five types of the condition. These are dysplastic spondylolisthesis, pathologic spondylolisthesis, traumatic spondylolisthesis, degenerative spondylolisthesis, and isthmic spondylolisthesis [15] _ Type 1 - (dysplastic spondylolisthesis) is congenital and due to dysplasia of

the neural arch with adolescent symptomatology. Type 1 is when there is a defect in the facet formation of a vertebra that lets it slip to the front [15] Type 2 is isthmic spondylolisthesis due to defect in pars inter-articularis following stress fracture [16,]. Type 3 is Degenerative spondylolisthesis and due to degeneration of pars inter-articularis [15]. When there are tumors or other abnormalities in the bone itself of the vertebra then it is called pathologic spondylolisthesis. [15].

When there is trauma to a specific vertebra or any type of vertebra injury sustained then it is termed traumatic spondylolisthesis. The injuries are typically to the facet joints or to the pedicle of the bone formation. [15]. All these manifest in five grades of advancement of spondylolisthesis, Grade 1 - 25% of the body of the vertebra has slipped, Grade 2 - 50% of the body of the vertebra has slipped; Grade 3 - 75% of the body of the vertebra has slipped, Grade 4 - 100% of the body of the vertebra has slipped; Grade 5 - The body of the vertebra has fallen off completely [15,16]. Presenting symptoms and signs are back pain, nerve root compression and spinal stenosis. Spondylolisthesis is corroborated by visualization in MRI of spondylolysis. But it may be difficult because MRI is insensitive to sclerosis which usually outlines or corticate the lysis in pars inter-articularis [16]. This difficulty is averted by conventional radiography or computed tomographic studie [16].

f) Vertebral Trauma

Vertebral trauma may present as avulsion or compressional fractures. 2.08% of our studied population had compression fracture and another 2.08% had avulsion fracture. Compression could be spontaneous, traumatic or osteoporotic. Osteoporosis increases steadily with age, ranging from 20% for 50year old women to 65% for older women [17]. 50% of spinal traumas occur in the thorax, lumbar and sacral and the other 50% in cervical vertebra [17] For the stability of spinal fractures, there are three functional columns of the spine. Anterior column is made up of anterior half of both the vertebral body, disc and anterior longitudinal ligament [6]. Middle column is the posterior half of vertebral body/disc and posterior longitudinal ligament. Posterior column contains the neural arch and ligaments. Disruptions of two or more ligaments results in unstable fracture [17].

g) Spondylo-Discitis

Spondylo-discitis is seen in 2/100,000 per year, most common in patients older than 65years, diabetes mellitus or immunocompromised[18]. Such rarity is evidenced in this study with detection of only a case (2.08%). This aptly demonstrated the characteristic ring enhancement and involvement of two adjacent vertebrae. Spondylo-discitis presents as T1W low signal intensity in at least two adjacent vertebrae with sub-ligamentous or epidural soft tissue masses, bony cortical erosion and narrowed disc [18]

h) Vertebral Neoplasm

The metastatic bony lesion seen in our study which occurred in the 6th and 7th decades of life agreed with other studies [10]. Primary origin of vertebral metastasis are lungs (31%), breast (24%), GIT(9%), Prostate (8%) , lymphoma (6%), melanoma (4%) unknown(2%), kidney (1%), others including multiple myeloma (13%). Primary routes are nutrient artery, retrograde spread through Batson plexus (Valsalva manoeuvre) and inter-vertebral foramina [10]. About 70% of symptomatic metastasis found are contiguous segment involvement[10]. Vertebral metastasis seen in this study was from prostate. Metastasis from cancer of prostate affects the red marrow bones with 90% skeletal like spine, pelvis, ribs and skull. [10] Messiou et al in their study of osseous metastasis from prostate, found 70.9% osteoblastic and 29.1% as either lytic or mixed. This skeletal metastasis are diagnosed with conventional radiography or ^{99m}Tc-MDP scintigraphy. Imaging of metastasis to the bones from cancer of the prostate involves a cascade of studies, starting with ^{99m}Tc-MDP, backed up by plain x-ray correlation and followed by MRI, CT or even PET/CT. Scintigraphy can detect 10% change in bone mineral turnover whereas 50% change is needed for x-ray detection[10]. Scintigraphy can reveal bone metastasis 18months before plain x-ray. But scintigraphy is often not suitable for assessment of therapeutic response due to Flare phenomenon resulting from under-estimation [10]. This is substituted by PSA (prostatic surface antigen) and MRI. This is detected as low T1W signal contrasting with the high signal of marrow fat. The conspicuity is better shown with STIR sequence [10]. Most of the lesions are localised at anterior portion of the vertebral body (60%) while 30% infiltrate the pedicle or lamina with small percentage affecting both intra-dural or intra-medullary involvement suggesting poor prognosis. The outcome of metastasis of cancer of prostate to the spine and associated structures are uniformly bleak with median survival duration of 10months [10]

i) Miscellaneous Causes

Facet arthropathy, sciatica, sacro-iliitis, Bastrup's disease, compression of the nerve roots/spinal cord by osseous spurs or soft tissue structures, posterior vertebral compartment syndrome and intra-spinal lipoma are often overlooked source of LBP [1,2,3,11,13,19,20,21],. Myelo - CT and MRI are extremely useful in myelographic stop (the upper extension of the cord lesion) definition [19]. Fat suppression causes rescaling of signal intensities and categorises cartilage as the brightest structure [1]. This additive effect along with the darkened appearance of fat in adjacent soft tissues, sacral, iliac and lumbar marrow, renders improved visualization of structures and increases the conspicuity of lesion, thereby

improving pickup rate of sacroiliitis.[1] There are two fat suppressed sequences that are available: T1-weighted with fat suppression (T1FS) and fast short tau inversion recovery (Fast STIR) sequences. These are superior to T1 and T2 images, in demonstrating the changes of sacroiliitis[1]. MRI of the lumbar spine can clearly depict Bastrup's disease, interspinous bursal fluid, and an associated posterocentral epidural cyst. [13]. In 1929, Brailsford described arthritic joints between the spinous processes on radiological assessment and noted that "such patients have pain in the back when standing erect which is relieved by bending forward [13]. In 1933, Christian Bastrup, a Danish radiologist described in detail the clinical and radiological features of the syndrome. It manifests clinically as localized midline lumbar tenderness and pain on spinal extension that can be relieved by spinal flexion, local anaesthetic injection and excision of part of the involved spinous processes [13]. Radiologically, the disorder is characterized by close approximation and contact of the adjacent spinous processes (kissing spines) and resultant enlargement, flattening and reactive sclerosis of apposing interspinous surfaces [13]. Hypertrophy of the tips of the spinous processes may occur in the elderly persons especially in those with an occupational history of long periods of back flexion. This condition heretofore arises from chronic postural hyperlordosis and regional loss of discal spacings. [13].

Synonyms of Bastrup's disease are Bastrup's syndrome, Machete's syndrome, Arthrosis interspinosa, diarthrosis interspinosa, kissing osteophytes, kissing spine, kissing spinous disease, osteoarthritis processus spinosi vertebrarum lumbalum, osteoarthritis interspinalis [13].

Posterior vertebral compartment syndrome is a non-radicular low back pain, arising from changes of the posterior elements/perispinal tissues of the lumbar spine (i.e., the "posterior vertebral compartment"). They include: facet joint pathology (e.g., osteoarthritis, joint effusion, synovitis and synovial cysts), spondylolysis, spinal/perispinal ligamentous degenerative-inflammatory changes and perispinal muscular changes [2]. T2-weighted sequences with fat saturation, and when indicated the use of contrast-enhanced T1-weighted images with fat saturation, permit the visualization of degenerative-inflammatory changes of the posterior elements of the lumbar spine that in most cases would have been overlooked with conventional non-fat suppressed imaging.[15]

Sacroiliac joint lesions accounts for a small but significant number of LBP [1]. Easy detectability of sacroiliitis highlights the diagnostic value and utility of adding a single 'fat suppressed' sequence of the lumbo-sacral region in the coronal plane [1]. This adds marginally to the scan time but increases the yield of identifying incidental or manifest sacroiliac involvement in all cases referred for MRI for LBP [1].

Treatment of LBP could be pharmacological or non-pharmacological. Non-pharmacological interventions include, intensive interdisciplinary rehabilitation interventions—therapeutic exercise, soft-tissue manual techniques, acupuncture, movement re-education techniques, spinal manipulation, cognitive-behavioural therapy, or progressive relaxation.[8]. Morphological abnormality detected on MRI can be augmented with provocative discography to elicit pain response and this will assist in prediction of patients who will benefit from operative stabilization through precise lesion site localization. [4]

LBP is one of the most common causes of physician visits in the United States with an enormous socioeconomic burden [5] The estimated cost of medical care for patients with LBP exceeds \$8 billion annually [11]. Over the past 30 years the rate of disability claims related to low back pain has increased by 14 times the rate of population growth¹. [11]

V. CONCLUSION

The commonest cause of low back pain is disc hernia. Disc hernia in turn is most prevalent at L4/L5 disc level. Multiple pathologies were seen in some patients with common accompaniment being spondylosis and lumbar stenosis.

ACKNOWLEDGEMENT : Mrs Muna R, Tadze A. M, Aseh C, Manga H, Lilkan L. *The authors reported no potential conflict of interest relevant to this article*

REFERENCES RÉFÉRENCES REFERENCIAS

1. Sreedhar CM, Sree Ram MN, Alam A, Indrajit IK, Shanmuganandan K. Sacroiliitis in routine Mri for low back ache. Indian J Radiol Imaging [serial online] 2006 [cited 2011 Apr 28]; 16:643-9. Available from: <http://www.ijri.org/text.asp?2006/16/4/643/32288>
2. *Vogin, G. D.*, Radiographs as good as MRI for most patients with low back pain, *JAMA*. 2003; 289:2810-2818, 2863-2864
3. Sheehan, N.J. Review, Magnetic resonance imaging for low back pain indication and limitation. *Postgrad Med J*. 2010; 86: 374-378 DOI: 10.1136/and 2009.110973
4. Hanley, E.N., David, S.M. Current Concepts Review- Lumbar Arthrodesis for the treatment of back pain. *The Journal of bone and joint surgery*. 1999, 81: 716-30
5. Roudsari, B, Jaryik, J G, Lumbar spine MRI for low back pain: indications and yield. *AJR Am J Roentgenol*. 2010 ;195(3):550-9.
6. Runge VM, *Magnetic Resonance Imaging*, J B Lippincott, Philadelphia 1992:173,183

7. Eberhars S, Harald, P, Randolph, K, Vieri F, et al, Lumbar spinal stenosis: syndrome , diagnostics and treatment. *Nature Reviews Neurology* 2009,5L 392-403 . doi:10.1038/nrneurol.2009.90
8. William, R. VanWye, P.T.Non-specific low back pain: Evaluation and Treatment, *The Journal of Family Practice.*2010,59 (8):445-448
9. van Rij JC, Klemetso N, Reitsmai JB, Bossuyt PM et al. Observer variations in the evaluation of Lumbar herniated disc and root compression : spinal CT compared with MRI. *British Journal of Radiology*, 2006,79:372-377.
10. Messiou C, Cook G, de Souza NM, Imaging Metastatic Bone Disease from Carcinoma of the Prostrate , *British Journal of Cancer*,2009, 101:1225-1232
11. Jansen, M.C.,Brant-Zawadzki, M.N.,Obuchowski, N.,Modic M.T., Malkasian, D.,Ross, J.S. Magnetic Resonance imaging of the lumbar spine in people without back pain. *NEJM.*1994,331 (2): 69-73
12. Boleago-Durami B, Fiesco-Gomez L E, Degenerative disease of the lumbar spine , clinical and Magnetic Resonance Imaging, *Cir Ciry*, 2006, 74 ((2): 101-105
13. G. K. Kota, N. K. Shyam Kumar & R. Thomas : Baastrups Disease An Unusual Cause Of Backpain: A Case Report . *The Internet Journal of Radiology.* 2005 Volume 4 Number
14. D'Aprile,, P. Tarantino, A, Jinkins, J.R, Brindicci, D The value of fat saturation sequences and contrast medium administration in MRI of degenerative disease of the posterior/perispinal elements of the lumbosacral spine. *European radiology.* 2007; 17 (2) : 523-31. DOI : 10.1007/s00330-006-0324-0
15. Samuels, T.5 types of Spondylolisthesis, Associated content 17/7/2009 http://www.associatedcontent.com/article/1933002/5_types_of_spondylolisthesis.html
16. Irani Z, Patel JN Spondylolithesis , *eMedicine Radiology:(Assessed on 15/5/2010)* <http://emedicine.medscape.com/article/396016-overview>
17. Reiter GI, Vertebral fracture updated 13/4/09
18. Hopkinson N, Stevenson J, Benjamin SA, Case assessment a sturdy of Septic discitis. *Clinical microbiological features.* *Oxford Journal of Medicine*,2001,94: 465-470
19. Kretzschmar, K. Degenerative diseases of the spine. The role of myelography and myelo-CT. *European journal of radiology.* 1998; 27 (3) : 229-34
20. Gozzi,G, Pozzi Mucelli, R., de Morpurgo, P.L., Sabella,, M., Bortolotto, P., Bellis, G.B. Evaluation of expansive myelo-vertebral pathology using different radiologic modalities, magnetic resonance excluded.*La Radiologia medica.* 1988; 75 (6) : 577-83.
21. Brown E, Matthes JC, Bazan C 3rd, Jinkins JR. Prevalence of incidental intraspinal lipoma of the Lumbo-sacral spine as determined by MRI. *Spine (Phila Pa 1976).* 1994 19 (7) : 833 -6.





This page is intentionally left blank