



GLOBAL JOURNAL OF MEDICAL RESEARCH

Volume 11 Issue 1 Version 1.0 May 2011

Type: Double Blind Peer Reviewed International Research Journal

Publisher: Global Journals Inc. (USA)

Online ISSN: 0975-5888

# A Composite Study of Coeliac Trunk in 30 Adult Human Cadavers - its Clinical Implications

By Ambica Wadhwa, Sandeep Soni

*Punjab Institute of Medical Sciences, Jalandhar*

**Abstracts** - Variations of origin and course of arteries of different organs are not only of anatomical and embryological interest but also of practical and clinical importance when these variations can be the agents of pathological conditions, or in surgery when knowledge of them can result in more accurate treatment. With the development of techniques of arteriography, the knowledge of arteries and of their variations has acquired a special importance for correct interpretation of the different, and sometimes very complicated roentgenographic pictures. Anatomical variations involving the visceral arteries are common. However though variations in coeliac trunk are usually asymptomatic, they may become important in patients undergoing diagnostic angiography for gastrointestinal bleeding or prior to an operative procedure. Recognition of variations enables clinicians to distinguish features which merit further investigations or treatment from those which do not. Clinical implications of variations in this artery have been stressed upon.

**Keywords:** *Coeliac trunk, Gastric artery, Hepatic artery, Splenic artery.*



*Strictly as per the compliance and regulations of:*



© 2011 Ambica Wadhwa, Sandeep Soni. This is a research/review paper, distributed under the terms of the Creative Commons Attribution-Noncommercial 3.0 Unported License <http://creativecommons.org/licenses/by-nc/3.0/>, permitting all non-commercial use, distribution, and reproduction in any medium, provided the original work is properly cited.

# A Composite Study of Coeliac Trunk in 30 Adult Human Cadavers – its Clinical Implications

Ambica Wadhwa<sup>α</sup>, Sandeep Soni<sup>Ω</sup>

**Abstract-** Variations of origin and course of arteries of different organs are not only of anatomical and embryological interest but also of practical and clinical importance when these variations can be the agents of pathological conditions, or in surgery when knowledge of them can result in more accurate treatment. With the development of techniques of arteriography, the knowledge of arteries and of their variations has acquired a special importance for correct interpretation of the different, and sometimes very complicated roentgenographic pictures. Anatomical variations involving the visceral arteries are common. However though variations in coeliac trunk are usually asymptomatic, they may become important in patients undergoing diagnostic angiography for gastrointestinal bleeding or prior to an operative procedure. Recognition of variations enables clinicians to distinguish features which merit further investigations or treatment from those which do not. Clinical implications of variations in this artery have been stressed upon.

**Keywords:** Coeliac trunk, Gastric artery, Hepatic artery, Splenic artery.

## I. INTRODUCTION

Anomalous blood vessels are always interesting from a purely scientific point of view, especially since they so often shed light on obscure problems of phylogeny and ontogeny. They may also be of considerable significance from a clinical or a surgical standpoint [1]. Anatomic variations involving the visceral arteries are common. While vascular anomalies are usually asymptomatic, they may become important in patients undergoing diagnostic angiography for gastrointestinal bleeding or prior to an operative procedure or transcatheter therapy [2]. The unusual embryological development of the ventral splanchnic arteries can lead to considerable variations in the origin of coeliac trunk. Close relation of short coeliacomesenteric trunk with median arcuate ligament and the tight tendinous ring around the aortic opening can cause compression of the trunk which may lead to post prandial periumbilical pain and surgical intervention in such a case may be associated with the risk of ligating the wrong vessel or severing an essential organ sustaining artery, danger of ischaemia, gangrene, leakage and bleeding from the site of repair

[3]. since there is no anastomosis between the hepatic arteries, an injury to the hepatic artery during operation would result in hepatic damage with serious morbidity. Therefore, preoperative information on the anatomical features of the hepatic arteries is very important in hepatobiliary surgery [4]. Knowledge of the approximate level at which the splenic artery arises from the coeliac axis and its course should also be of help in defining the superior margin of the field when the splenic pedicle is to be treated in splenectomized Hodgkin's disease patients [5]. The purpose of the present study is to give a composite account of the celiac trunk with regard to its origin, vertebral level, sexwise distance from aortic bifurcation, length, branches and its variations encountered. The clinical implications of these variations are subsequently discussed.

## II. MATERIAL AND METHODS

The material for this study comprised of 30 well embalmed adult human cadavers of known sex obtained from the Department of Anatomy, Govt. Medical College, and Amritsar. They were serialized from 1-30 with suffix 'M' for male and 'F' for female. The abdominal cavity was opened by a cruciform incision passing through the whole thickness of the anterior abdominal wall. Flaps were reflected. The abdominal viscera i.e. stomach, intestines liver, pancreas and spleen were systematically removed according to Cunningham's Manual of Practical Anatomy [6]. The abdominal aorta was cleaned along its whole length and the origin of various branches was traced. The coeliac trunk was identified and its branches were cleaned. The coeliac trunk was studied with respect to the following parameters:

1. Vertebral level of origin.
2. Diameter of the artery.
3. Length of the artery.
4. Distance between origin of coeliac artery and the aortic bifurcation.
5. Branching pattern.

*About<sup>α</sup> - Deptt. Of Anatomy, Punjab Institute of Medical Sciences, Garha Road, Jalandhar. Ph. 09876005162*

*E-mail – ambicasoni02@yahoo.com*

*About<sup>Ω</sup> - Deptt. Of Chest & TB, Punjab Institute of Medical Sciences, Jalandhar*

### III. RESULTS AND DISCUSSION

Anatomical variations involving the visceral arteries are common. However though variations in coeliac trunk are usually asymptomatic, they may become important in patients undergoing diagnostic angiography for gastrointestinal bleeding or prior to an operative procedure [2].

#### a) Origin:

##### i. Vertebral level

In the current study of coeliac trunk, it was arising from the aorta at the level of intervertebral disc between T12 and L1 in 22 cases (73.3%) and upper 1/3rd of L1 vertebra in 8 cases (26.6%). The findings were comparable to the study of Moncada et al [7] and Hofman and Watson [8] who concluded that the vertebral level ranged from upper third of T11 to L2 vertebra with a mean level opposite upper third of L1 vertebra. Slight variability in the vertebral level suggests that treatment planning for carcinoma stomach, pancreas and hepatobiliary tree should be individualised as the nodes at risk lie adjacent to this vessel.

##### ii. Distance from aortic bifurcation

Cauldwell and Anson [9] defined the coeliac-bifurcation interdistance to represents the linear extent of abdominal aortic segment. In the present study the mean distance of origin of coeliac artery from the aortic bifurcation was 12.8cm with a range of 9.5cm to 12.8cm.

##### iii. Diameter at origin

The range of diameter was found to 7 mm to 14 mm with a mean of 11.5 mm, the findings comparable with the range of 8 mm to 16 mm given by Moncada et al [7].

##### iv. Length

The length of this artery ranged between 8mm and 21 mm with the maximum number of cases i.e. 17(56.6%) falling between 10mm to 13mm. Michels [10] in his study has given the range of length between 8mm to 40 mm. Cavdar et al [3] reported that a long coeliac trunk is always associated with a varied origin of left gastric artery from aorta, hepatic or splenic artery. However, they also reported one case in which a long coeliac trunk (43mm), the longest reported in literature gave origin to left gastric artery. Similar observations were made in the present study in 2 cases (6.6%) (17 M, 21 M) where the length of the artery was 20 mm and 21 mm respectively and the left gastric artery was arising from the splenic artery.

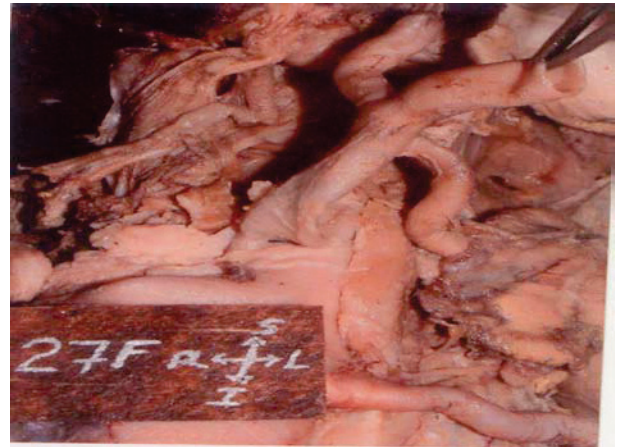


Figure 1– Length of coeliac trunk is more than normal.

Table 1- Incidence of length of coeliac trunk

Range of Length (mm)	Number of cases	Percentage
8 – 10	3	10.0
10 -12	9	30.0
12 -14	8	27.0
14 -16	2	6.6
16 -18	6	20.0
18 -20	0	0
20 -22	2	6.6
TOTAL	30	100

#### b) Branching pattern

According to Moncada et al [7], 89% of the coeliac arteries divide into left gastric, common hepatic and splenic arteries but variations in the arrangement are quite common. Vandamme and Bonte [11] in their angiographic study showed that only 86% of coeliac trunk showed the classical trifurcation whereas Michels [10] stated this percentage to be only 55%.

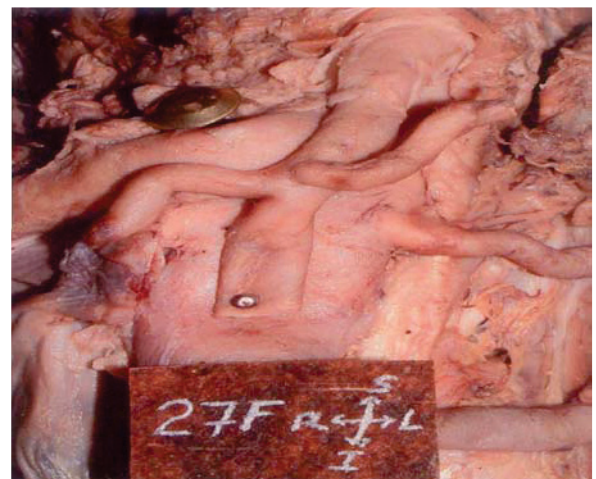

Figure 2- Typical trifurcation of coeliac trunk into left gastric artery, common hepatic artery and Splenic artery.

Author & Year	No. of subjects examined	Coeliac axis complete	Celiac axis incomplete	Coeliaco-mesenteric trunk	Celiac axis absent
Rossi & Cova (12)	102	86 (84.5%)	12 (11.7%)	2 (1.96%)	2 (1.96%)
Descomps (13)	50	44 (87.4%)	6 (12%)	0	0
Picquand (14)	50	41 (82%)	7 (14%)	1 (2%)	1 (2%)
Rio Branco (15)	50	45 (90%)	2 (4%)	1 (2%)	2 (4%)
Lipschutz (16)	83	60 (72.2%)	21 (25%)	2 (2.4%)	0
Eaton (17)	206	186 (90.2%)	19 (9.2%)	1 (0.6%)	0
Present Study	30	28 (93.3%)	2 (6.6%)	0	0

*Table - 2 Comparison of incidence of mode of origin of branches of coeliac trunk.*

Present study was thus in near agreement with the study of Eaton [17] but no case of coeliaco-mesenteric trunk was found although there was approximation of the celiac and superior mesenteric artery in 2 cases (16 M, 20 M) without loss of their topographical integrity as they emerged from the aorta. This close relation with a large median arcuate ligament of the diaphragm may cause compression syndrome of coeliac trunk leading to post-prandial periumbilical pain [3].

Lipshutz [16] gave a detailed account of coeliac trunk based on the mode of origin and distribution of gastric, splenic and hepatic arteries and classified his findings into 4 types.

**Type I:** (75% cases) coeliac axis was the common trunk of origin for the gastric splenic and hepatic arteries.

**Type II:** (15% cases), the hepatic and splenic artery arose from the coeliac trunk but left gastric artery had a varied origin either from hepatic artery or directly from abdominal aorta.

**Type III:** (6% cases), the gastric and hepatic arteries took origin from celiac axis, but the splenic artery was a separate branch from abdominal aorta.

**Type IV:** (4% cases), coeliac axis was the trunk of origin for gastric and splenic arteries, but hepatic artery occurred as a separate branch directly from abdominal aorta.

*Table 3- Comparison of the mode of origin of branches of coeliac trunk*

Author	Year	No. of specimens	Type I	Type II	Type III	Type IV
Rossi & Cova (12)	1904	55	48	6	0	1
Picquand (14)	1910	50	37	5	3	4
Descomps (13)	1910	50	28	16	0	5
Rio Branco (15)	1912	50	30	15	3	1
Lipschutz (16)	1917	83	41	21	3	12
Eaton (17)	1917	206	140	47	10	9
Present study	2004	30	28	2	0	0

In the present study, type I coeliac axis was found in 28 cases (94%) and type II coeliac axis was found in 2 cases (6%) cases in which the left gastric artery arose from the abdominal aorta. According to Eaton [17] knowledge of type II coeliac trunk decreases the risk of error and inadvertent ligation of other structures. Additionally, it is necessary to recognize this abnormality during diagnostic angiography and prior to transcatheter intervention. Knowledge of variations in the level of origin of splenic artery, its calibre and course is helpful in defining the superior margin of the field when splenic pedicle is to be treated in splenectomized hodgkin's disease patients [18].

## REFERENCES RÉFÉRENCES REFERENCIAS

- 1) Dawson AB and Reis JH. An anomalous arterial supply to suprarenal, kidney and ovary. Anat Rec 1922; 23-24: 161-167.
- 2) Ray CE, Gupta AK, Shenoy SS. Left gastric artery arising from the superior mesenteric artery. Angiology, 1998; 49: 1017-1021.
- 3) Cavdar S, Sehirli U, Pekin B. Celiacomesenteric trunk. Clinical Anatomy 1997; 10: 231-234.
- 4) Nagino M, Hayakawa N, Kitagawa S, Dohke M, Nimura Y. Right anterior hepatic artery arising from the superior mesenteric artery: a case report. Hepatogastroenterol 1993; 40: 407-409.
- 5) Kao GD, Whittington R, Coia L. Anatomy of the celiac axis and superior mesenteric artery and its significance in radiation therapy. J Radiol Oncol 1992; 25: 131-34.
- 6) Romanes GJ. Cunningham's manual of practical anatomy. In: the abdomen 15<sup>th</sup> Edn, Vol 2, Oxford University Press, New York, Tokyo 2000; 142-53.





- 7) Moncada R, Reynes C, Churchill R, Love L. Normal vascular anatomy of the abdomen on computed tomography. *Radiol Clin North Am* 1979; 17(1): 25-37.
- 8) Hofman S and Watson R. Porta hepatis irradiation. *Int J Radiat Oncol Biol Phys* 1978; 4: 333-336. Cited by Kao GD, Whittington R, Coia L. Anatomy of the celiac axis and superior mesenteric artery and its significance in radiation therapy. *J Radiol Oncol biol phys* 1992; 25: 131-34.
- 9) Cauldwell EW and Anson BJ. The visceral branches of the abdominal aorta: Topographical relationships. *Am J Anat* 1936; 73: 27-57.
- 10) Michels NA. Embryology, topographic relations and development anomalies, observations on the blood supply of the liver and the gall bladder. In : Blood supply and anatomy of the upper abdominal organs. Pitman Medical Publishing Co. Ltd., London 1955; 25: 140.
- 11) Vandamme JPJ and Bonte J. The branches of the celiac trunk. *Acta Anat* 1985; 122: 110-14.
- 12) Rossi G and Cova E. Studio morfologico delle arterie dello stomaco. *Arch Ital di Anat e di Embryol* 1904; 3: 485-526. Cited by Cauldwell EW and Anson BJ. The visceral branches of the abdominal aorta: Topographical relationships 1943; 73: 27-57.
- 13) Descomps P. Le trone coelique. Steinheil, Paris 1910. Cited by Vandamme J.PJ and Bonte J. The branches of coeliac trunk. *Acta Anat* 1985; 122: 110-114.
- 14) Picquand G. Researches sur l'anatomie du trone coeliaque et de ses branches. *Bibliogr anat* 1910; 19: 159-201. Cited by Cauldwell EW and Anson BJ. The visceral branches of the abdominal aorta: Topographical relationships. *Am J Anat* 1943; 73: 27-57.
- 15) Rio Branco P. Essai sur l'anatomic et la medecine operatoire du trone coeliaque et de ses branches de l'artere hepatique en particulier G. Steinheil. Paris 1912, 828. Cited by Cauldwell EW and Anson BJ. The visceral branches of the abdominal aorta: Topographical relationships 1943; 73: 27-57.
- 16) Lipshutz B. A composite study of the coeliac axis artery. *Ann Surg* 1917; 65: 159-169.
- 17) Eaton PB. The coeliac axis. *Anat Rec* 1917; 12-13: 369-374.
- 18) Rosenblum JD, Boyle CM, Schwartz LB. The mesenteric circulation: Anatomy and Physiology. *Surg Clin North Am* 1997; 77(2): 289-305.

# GLOBAL JOURNALS INC. (US) GUIDELINES HANDBOOK 2011

---

[WWW.GLOBALJOURNALS.ORG](http://WWW.GLOBALJOURNALS.ORG)