



GLOBAL JOURNAL OF MEDICAL RESEARCH: I  
SURGERIES AND CARDIOVASCULAR SYSTEM

Volume 14 Issue 4 Version 1.0 Year 2014

Type: Double Blind Peer Reviewed International Research Journal

Publisher: Global Journals Inc. (USA)

Online ISSN: 2249-4618 & Print ISSN: 0975-5888

## Laparoscopy at Sebokeng Hospital with Emphasis on Trauma

By I Bombil, MD, FCS (SA), A Maraj, MBChB, W S Lunda, MD, MMED Fam Med,  
H.Dip.Surg, J Thomson, MBBCh & B Puttergill, MBBCh

*University of Witwatersrand, South Africa*

**Abstract-** Advances in minimal access surgery has revolutionized the practice of surgery over the past two decades. In some areas, laparoscopy has become the standard of care as in cholecystectomy. Laparoscopy in trauma however has been trailing behind, supposedly because of the fear of missing injuries in unpredictable trauma setting. There are reports in the literature about the benefit of laparoscopy in trauma, but we do not have local data in South Africa. We therefore endeavour to assess the place of laparoscopy in trauma by performing this audit of our laparoscopy practice at Sebokeng Hospital, South Africa.

**Objective:** Review of the practice of Laparoscopy at Sebokeng Hospital with special emphasis on trauma to identify the indications of laparoscopy in the management of selected injuries.

**Methods:** Retrospective review of data from all laparoscopic procedures performed between November 2011 and October 2012 at Sebokeng Hospital. Parameters evaluated included demography, mechanism of injury, procedure and intra-operative findings.

**GJMR-I Classification:** FOR Code: WF 350



*Strictly as per the compliance and regulations of:*



# Laparoscopy at Sebokeng Hospital with Emphasis on Trauma

I Bombil, MD,FCS (SA)<sup>α</sup>, A Maraj, MBChB<sup>σ</sup>, W S Lunda, MD, MMED Fam Med, H.Dip.Surg<sup>ρ</sup>, J Thomson, MBBCh<sup>ω</sup> & B Puttergill, MBBCh<sup>¥</sup>

**Abstract-** Advances in minimal access surgery has revolutionized the practice of surgery over the past two decades. In some areas, laparoscopy has become the standard of care as in cholecystectomy. Laparoscopy in trauma however has been trailing behind, supposedly because of the fear of missing injuries in unpredictable trauma setting. There are reports in the literature about the benefit of laparoscopy in trauma, but we do not have local data in South Africa. We therefore endeavour to assess the place of laparoscopy in trauma by performing this audit of our laparoscopy practice at Sebokeng Hospital, South Africa.

**Objective:** Review of the practice of Laparoscopy at Sebokeng Hospital with special emphasis on trauma to identify the indications of laparoscopy in the management of selected injuries.

**Methods:** Retrospective review of data from all laparoscopic procedures performed between November 2011 and October 2012 at Sebokeng Hospital. Parameters evaluated included demography, mechanism of injury, procedure and intra-operative findings.

**Result:** A total of 390 laparoscopic procedures were performed. Majority were emergency 77.9% (304/390) topped by appendicectomy 54.9% (167/304) whilst trauma represented 13.8% (42/304) of all emergencies.

Cholecystectomy was the most common elective procedure 74.4% (64/86). Of the trauma cases, 40 were available for analysis; the patients were predominantly male (36/40) and stable penetrating trauma was the most common indication (34/40) for surgery. Laparoscopy was successfully completed in 65% (26/40) of the patients. The remaining cases benefited from conversion 17.5% (7/40), laparoscopy assisted mini-laparotomy 15% (6/40) and laparoscopy guided referral to tertiary Hospital 2.5% (1/40).

**Conclusion:** Laparoscopy is applicable in trauma in carefully selected cases obviating the need for unnecessary laparotomy with its related early and long term complications.

## I. INTRODUCTION

Technology has rapidly revolutionized the practice of medicine in the past two decades. Minimal access surgery is evolving gradually and in some procedures, it has become the standard of care as in laparoscopic cholecystectomy<sup>1,2,3</sup>.

Author <sup>α</sup> <sup>σ</sup> <sup>ω</sup> <sup>¥</sup>: Department of Surgery, Sebokeng Hospital and the Faculty of Health Sciences. University of Witwatersrand, Johannesburg, South Africa. e-mail: bombil@telkomsa.net

Author <sup>ρ</sup>: Department of Surgery, Sebokeng Hospital. Sedibeng District, Gauteng, South Africa.

Laparoscopic appendicectomy, the most common emergency general surgical operation has made significant progress over the past few years<sup>4</sup>. But trauma is lagging behind supposedly due to the fear of missing injuries in a somewhat unpredictable trauma scenario<sup>5,12</sup>. While this concern is genuine in a complex case, it should not defer the surgeon from attempting laparoscopy because in selected patients, laparoscopy can reduce the rate of negative and positive but non-therapeutic laparotomies in trauma<sup>6,7</sup>. There is also an added potential benefit of decreasing the incidence of adhesive bowel obstruction and formation of incisional hernia; the most common late complications of laparotomy. Acquisition of skills coupled with sound clinical judgment are paramount for laparoscopy in trauma to gain ground in common surgical practice<sup>5</sup>. The feared complication of missed bowel injury may render the laparoscopic approach counter-productive considering its associated high morbidity and even mortality. Therefore a systematic standardized approach is needed during laparoscopy to lessen the risk of missing bowel injury and a low threshold for conversion should be encouraged in the setting where laparoscopic visualization is challenging or sub-optimal<sup>12</sup>. We do not have published data about our local experience of the use of laparoscopy in trauma. This study will endeavour to give an overview of our laparoscopic practice at Sebokeng hospital with emphasis on trauma. Sebokeng hospital is a regional hospital in South Africa with registrar training program. We believe it is crucial to familiarize the prospective surgeons with laparoscopic exposure in all fields of surgery to keep up with the advancing technology. This entails adjustment in the mind-set and procurement of the necessary skills to adapt to the changes of practice and to overcome the learning curve.

## II. OBJECTIVE

Review of the practice of Laparoscopy at Sebokeng Hospital with special emphasis on trauma to identify the indications of laparoscopy in the management of selected injuries.

## III. METHODS

Audit of all abdominal surgical operations performed between November 2011 and October 2012

at Sebokeng Hospital, a regional hospital with a Registrar training program. A subgroup of trauma patients treated with laparoscopy was analysed. Parameters included are demography, mechanism of injury, procedure (laparoscopic or laparoscopy-assisted procedures, converted cases) and intra-operative findings. Unstable penetrating trauma were excluded, preference given to emergency laparotomy. Ethic approval was obtained from the Human Ethic Committee of the University of the Witwatersrand.

#### IV. STATISTICS

This is a descriptive study using mean, proportion by ratio or percentage.

#### V. RESULTS

A total of 851 abdominal surgeries were performed (436 emergencies and 415 electives) both for trauma and non-trauma. 54.1% (461/851) of procedures were laparotomies and 45.8% (390/851) of the procedures were performed laparoscopically. Of the laparoscopic cases 77.9% (304/390) were emergencies and 22.0% (86/390) were elective. The elective group was mainly cholecystectomy 74.4% (64/86) while hernias (inguinal, incisional) represented the remaining 25.5% (22/86). Appendicectomy topped the list in the emergency group: 54.9% (167/304). Exploratory laparoscopy contributed 26.3% (80/304) for various pathologies (bowel obstruction, pelvic inflammatory disease, abdominal tuberculosis, pancreatitis) and 13.8% (42/304) were due to trauma. Repair of perforated peptic ulcer occurred in 4.9% (15/304). Of note, appendicectomy and cholecystectomy covered 59.2% (231/390) of all laparoscopies.

Of the 42 trauma cases, 2 were excluded due to missing data and 40 cases were available for analysis. The mean age was 31.6 years (14-62) and there were 36 males and 4 females with male to female ratio of 9:1. Indications for laparoscopy were divided as follow:

##### a) *Stable (most common): 37 cases*

- i. *Penetrating: 34 cases divided as*
  1. Thoracoabdominal stab (suspected diaphragmatic injury): 7 cases
  2. Intra-abdominal organ injury suspected without clear clinical evidence of acute abdomen: 27 cases
    - Stab: 25: - Disembowelment: 8 cases (6 omentum, 2 small bowel)
    - No disembowelment: 16 (penetrating injury: suspected perforating injury)
    - Knife impacted in the abdomen: 1
    - Gunshot: 2. (no disembowelment)
- Blunt: 3 cases.
  - 2 delayed (acute abdomen): 1. Small bowel injury
  - 2. Pancreatic injury

- 1 acute: Diaphragmatic injury
- b) *Unstable (uncommon): 3 cases.*
  - i. *Penetrating: None (exclusion criteria)*
  - ii. *Blunt: 3 acute cases (polytrauma): 03 (non-therapeutic exploration).*

#### VI. FINDINGS

1. Thoracoabdominal: 7 penetrating stab wounds (3 negative and 4 diaphragmatic injury repaired), one blunt (repair diaphragmatic injury).
2. Abdominal: 25 Stabs (8 non-therapeutic, 6 negative explorations, 6 converted, 5 laparoscopy assisted).
3. Abdominal: Two gunshots of which one non-therapeutic (isolated liver injury) and the second case converted (ascending and transverse colon injury).
4. Abdominal: 6 blunt cases: One converted (small bowel injury with peritonitis), one pancreatitis (secondary to pancreatic injury: delay case, patient transferred to tertiary hospital for further management), one diaphragmatic repair and 3 non-therapeutic (minimal blood due to grade 1 liver injury) of which two were transferred to orthopaedic surgery for further management of multiple long bone fracture and one died due to the severity of injury (severe head injury, pelvic fracture, multiple long bones).

65% (26/40) of the procedures were completed laparoscopically. 15% (6/40) were laparoscopy-assisted, 17.5% (7/40) were converted and in 2.5% (1/40) laparoscopy had guided decision for referral.

#### VII. DISCUSSION

The main intention at this stage was not to accomplish a laparoscopic repair of intra-abdominal pathologies but to avoid unnecessary laparotomy (negative exploration or positive but non-therapeutic finding) or to guide a laparoscopy-assisted minimally invasive open repair. The exception was in the cases of an isolated diaphragmatic injury which were repaired laparoscopically.

##### a) *Stab*

Thoracoabdominal: Unless there are obvious herniation, thoracoscopy or laparoscopy is the preferred procedure to perform to rule out diaphragmatic injuries. None of the investigations (Ct scan, ultrasound, contrast study) are sensitive enough to pick up diaphragmatic injury nor specific enough to rule it out<sup>8,9</sup>. In our practise, missed diaphragmatic hernias present later with complications thereof, often with dire consequences. Four of the seven patients with thoracoabdominal stab had diaphragmatic injury that were repaired laparoscopically.

Twenty one laparotomies were prevented because of exploratory laparoscopy. In these patients with penetrating stab wounds to the abdomen; the

clinical pictures were not clear cut early on; usually there is tenderness around the stab with no obvious peritonitis. The main aim of ultrasound and Ct-scan in trauma is to diagnose the presence of intraperitoneal fluid; their roles become even less defined when we consider hollow viscus perforation for which the sensitive and specific is not adequate enough to diagnose or exclude a minor bowel injury<sup>9,10</sup>.

Practising selective conservatism may be dangerous for a nick in the bowel may manifest as peritonitis after 48 to 72 hours (mucous plug preventing early spillage of bowel content). Some surgeons advocate wound exploration under local anaesthesia<sup>11</sup>. If the wound is penetrating then laparotomy is performed (fig.1). With this approach, all our patients would have had unnecessary laparotomy. One patient had a self-inflicted stab in the left upper quadrant with impacted knife; the laparoscopic exploration revealed through and through left liver lobe laceration with no other injury (fig.2). Under vision the knife was removed and there was no evidence of significant bleeding. A drain was left in situ. If a laparotomy was performed instead, it would have been positive and non-therapeutic.

Six cases were converted, when laparoscopic exploration was positive and the magnitude of injury precluded a safe laparoscopic repair, then conversion was preferable to minimize the chance of missing an injury or performing inadequate laparoscopy repair because advanced laparoscopy skills is required to perform intracorporeal suturing. An example of such case was a patient with right flank stab, the clinical picture was not remarkable and the reason for exploration was to rule out a possible retroperitoneal injury (colon, ureter). When the laparoscopic exploration was almost completed as a nontherapeutic procedure; there was a sudden massive bleed. The conversion revealed a transected left common iliac vein that was ligated. Likewise, 6 patients had an isolated bowel injury on laparoscopic exploration necessitating a mini-laparotomy to exteriorise the injured bowel and to perform a safe open repair. With advanced skill in laparoscopy all these cases could possibly have benefited from laparoscopic repair.

#### *b) Gunshot*

Most gunshots will still qualify for exploratory laparotomy but in certain cases such as stable patients without evidence of peritonitis where intra-abdominal injury is unlikely, laparoscopy can help decide whether there is an injury which does not require further management. We had one such case of a gunshot wound to the right upper quadrant who was shot from behind with the bullet palpable under the skin anteriorly. Exploratory laparoscopy showed a liver injury through segment 8 with minimal oozing and no evidence of bowel injury (fig.3). A drain was inserted and the patient

was discharged on day 2 uneventfully (positive finding but non-therapeutic). In the second case, there were two gunshot wounds (right upper quadrant and right flank) and on laparoscopic exploration, a transverse colon injury was detected and the laparoscopic approach was abandoned. At laparotomy an additional injury was found in the ascending colon; a right hemicolectomy was performed.

#### *c) Blunt injury (acute presentation)*

In exceptional cases of polytrauma (blunt abdominal trauma, fracture pelvis and long bone, severe head injury) (fig.4, 5, 6) with hemodynamic instability, laparoscopy was quickly done to ascertain whether the abdomen was the cause of instability (in which case immediate conversion would have been done) obviating the need for laparotomy and redirecting the focus elsewhere (pelvic or long bone fractures and thoracic injuries). These are resuscitation cases and in setting, there is no time to wait for a radiologist to perform a sonar (FAST) or abdominal Ct-scan, the patients were rushed to operating room with the intention to perform a quick diagnostic laparoscopy to rule out the abdomen as the cause of instability. In all three cases, laparotomy was averted because laparoscopy revealed only very minimal blood in the peritoneal cavity (non-therapeutic). Two patients survived and were transferred to Orthopaedic department after initial ICU care. The third one demised due to severity of head injury and associated pelvic and multiple long bones fracture. Of the two survivors, one of the patients had a diagnostic laparoscopy combined with the insertion of an external fixator (C CLAMP) to stabilise the pelvic bone.

#### *d) Blunt (delayed presentation)*

We had two cases of acute abdomen following assaults. In the first case, we discovered bowel content but the source could not be assessed properly because of the inflammatory response and conversion was necessitated. The second patient showed evidence of pancreatitis (saponification) with no other obvious injury. The procedure was terminated and Ct-scan showed double fracture of the pancreas (fig.7). The patient was referred to hepatobiliary unit where laparotomy was performed for definitive management. In this case the laparoscopy obviated the need for two laparotomies. It is important to understand that exploratory laparoscopy can miss retroperitoneal injury, so the mechanism of injury combined with clinical picture should not be overlooked.

From this study, 65% of unnecessary laparotomy were avoided, 15% of patients benefited from mini-laparotomy because of laparoscopic guidance, 17.5% of patients had appropriate decisions made during laparoscopy to proceed to immediate laparotomy (conversion) and in 2.5% the decision was made to abandon the procedure and to prompt special



investigation (CT-Scan) which directed referral to the hepatobiliary unit.

This preliminary study shows that in carefully selected cases, there is a room for laparoscopic exploration; it is not expected to handle complex trauma cases but to identify scenarios where a less aggressive approach can be applied. We did not have any missed injury in this study; not because the surgeons involved had the best laparoscopic technique; but because appropriate decision making was performed i.e. to continue laparoscopically, to change the approach to laparoscopy-assisted mini-laparotomy or to convert to open procedure altogether. By so doing, we understood the best indication of each approach in a given situation. There are cases which were immediately selected for laparotomy that are not part of this study.

We did not perform the breakdown of the 461 cases of laparotomy which were mainly due to trauma but suffice to say that in term of proportion, the 42 cases of trauma laparoscopy represented an estimated 10 - 15 % of all trauma laparotomies. This emphasizes the low threshold we had to perform laparotomy rather than laparoscopy at this early phase of laparoscopy in trauma.

#### e) *Laparoscopy skill*

The skill of the laparoscopic surgeon is paramount to perform a safe laparoscopic procedure. The ability to perform intracorporeal knot tying is essential for an advanced laparoscopy. In our study, some of the converted cases (either to full laparotomy or minilaparotomy) were simple bowel injuries that could have benefited from laparoscopic repair if the surgeon could perform intracorporeal knots. We believe that as our proficiency in laparoscopy improves, more cases will qualify for this approach in future. This will be achievable if the trainees (registrars) are exposed early

and consistently to laparoscopy both for emergency and elective cases during their training.

#### f) *Instability*

Unstable penetrating trauma patients were excluded according to the exclusion criteria and patients in this category had exploratory laparotomies performed. All our laparoscopy for penetrating stabs were stable. We did not expect to perform laparoscopy on a critically ill patient. Nevertheless, in a small group (3 cases) of unstable blunt trauma, we performed laparoscopic exploration with the intention to rule out the abdominal cavity as the cause of instability rather than to perform any laparoscopic repair. This was proven to be beneficial in our setting where access to ultrasound and Ct scans are limited.

## VIII. CONCLUSION

Laparoscopy is applicable in various fields of general surgery. Certainly, there is a role for laparoscopy in carefully selected trauma cases. Laparoscopy has contributed to the prevention of unnecessary laparotomy in two-thirds of our cases and in the remaining cases it guided the management towards a minimally invasive surgery (mini-laparotomy) and prompted special investigation that assisted in the decision making. Only 17.5% required conversion. Indeed there is a role for laparoscopy in trauma mainly at this early stage to reduce preventable laparotomy rather than to embark in the repair of complex injuries.

## IX. RECOMMENDATION

We believe this pilot study will provide the general and trauma surgeon with some evidence to consider laparoscopy in very carefully selected trauma settings rather than to have a nihilistic approach.

#### *Converted: 7 cases*

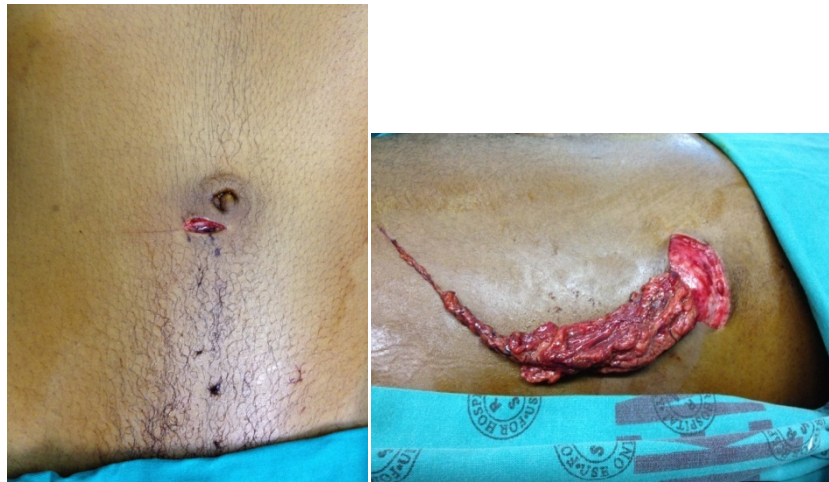Mechanism	Injury	Action
Stab thoracoabdominal	Diaphragm+stomach through and through	Repair diaphragm+stomach
Stab thoraco abdominal	Spleen grade 4 injury	Splenectomy
Stab abdominal	Colon+small bowel	Repaired
Stab abdomen	Small bowel	Repaired
Gunshot abdomen	Ascending,transverse colon and small bowel	Right hemicolectomy+ repair bowel
Stab abdomen	Common iliac vein injury	Ligated
Delayed stab	Small bowel	Repaired

#### *Laparoscopy completed: 26 cases*

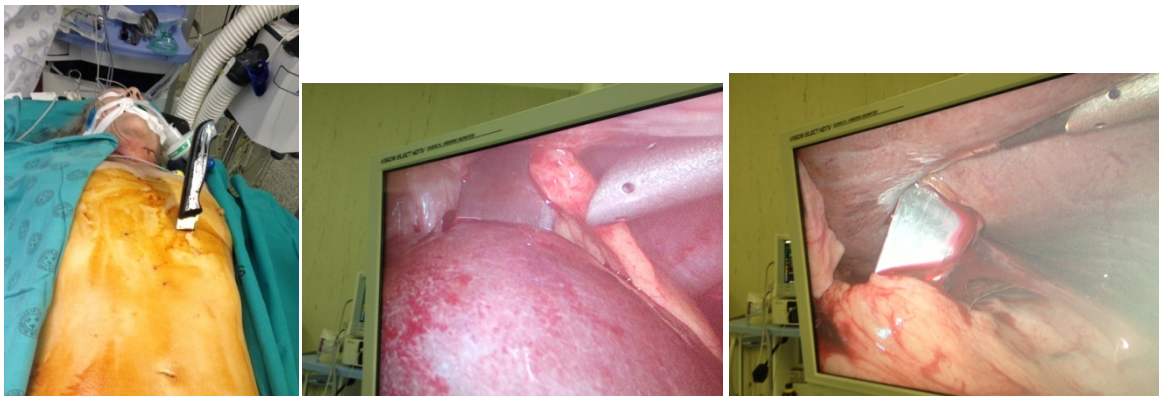
Number	Mechanism	Injury	Action
4	Stab thoracoabdominal	Diaphragm	Repaired
1	Stab abdomen	Small bowel	Repair
3	Blunt abdomen	Liver	Non-therapeutic
2	Stab abdomen	Omentum bleeding	Hemostasis
6	Stab abdomen	Negative	Nil
1	Gunshot abdomen	Liver through and through	Non-therapeutic
1	Blunt abdomen	Diaphragm	Repaired
8	Stab abdomen	Omentum (6), liver(1), spleen (1)	Non-therapeutic

*Laparoscopy assisted repair: 6 cases*

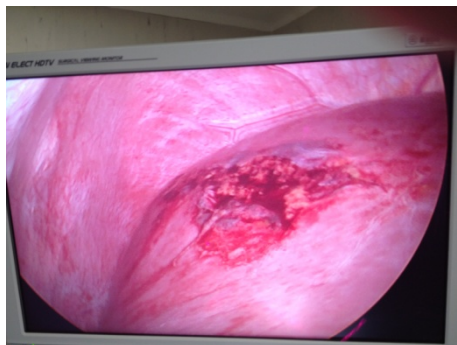
Number	Mechanism	Injury	Action
4	Stab abdomen	Small bowel	Repair through mini laparotomy
2	Stab abdomen	Sigmoid colon	Repair through mini laparotomy



*Figure 1* : Penetrating abdominal stab. 1a. No disembowelment (negative laparoscopy); 1b. Omentum sticking out (laparoscopy guided hemostasis)



*Figure 2* : Impacted knife with non-therapeutic laparoscopy. 2a. Left upper quadrant stab, 2b. Anterior liver (left lobe), 2c. Posterior liver (left lobe)



*Figure 3* : Gunshot liver right lobe (segment 8). Non therapeutic laparoscopy

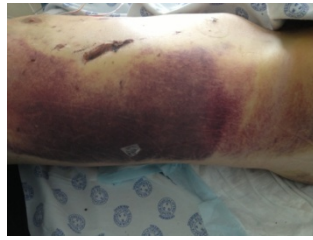

Figure 4 : Blunt trauma. Massive contusion right flank. Non-therapeutic laparoscopy prevented unnecessary laparotomy

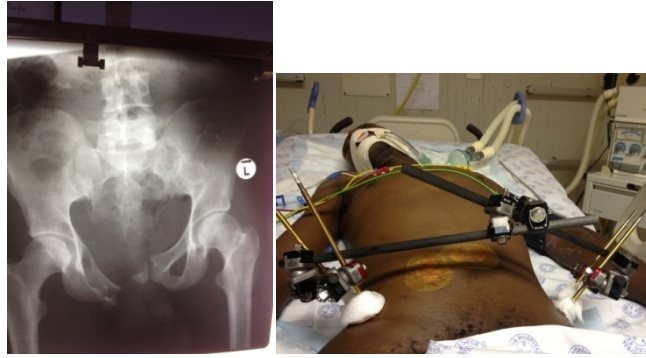


Figure 5 : a: Open book fracture; b: External fixator (C clamp) after a non-therapeutic laparoscopy

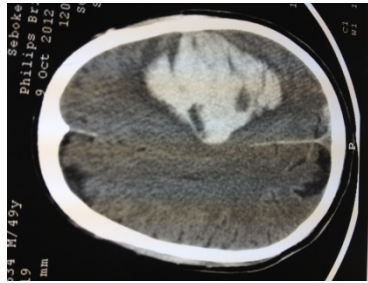


Figure 6 : Massive intracerebral bleed contributed to the severity of polytrauma patient with non-therapeutic laparoscopy

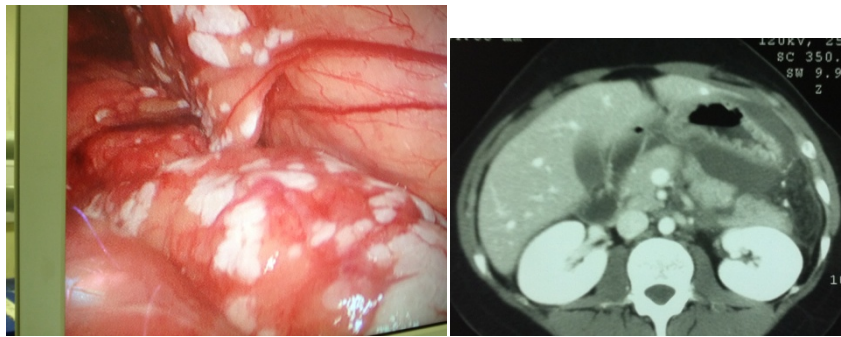


Figure 7 : a: Exploratory laparoscopy: Saponification prompted a ct-scan abdomen; b: Ct-scan: Double fracture of pancreas





## REFERENCE RÉFÉRENCES REFERENCIAS

1. Genc V; Sulaimanov M; Cipe G; Basceken SI; Erverdi N; Gurel M; Aras N; Hazinedaroglu SM. What necessitates the conversion to open cholecystectomy? A retrospective analysis of 5164 consecutive laparoscopic operations. *Clinics (Sao Paulo)*. 2011; 66(3):417-20 (ISSN: 1980-5322). Department of Surgery, School of Medicine, Ankara University, Ankara, Turkey.
2. Ghnnam W; Malek J; Shebl E; Elbeshry T; Ibrahim A. Rate of conversion and complications of laparoscopic cholecystectomy in a tertiary care center in Saudi Arabia. *Ann Saudi Med*. 2010; 30(2):145-8 (ISSN: 0975-4466). Department of General Surgery, Mansoura Faculty of Medicine, 1 Elbahr Street, Elgomhoria, Mansoura, Egypt.
3. Ballal M; David G; Willmott S; Corless DJ; Deakin M; Slavin JP Conversion after laparoscopic cholecystectomy in England. *Surg Endosc*. 2009; 23(10):2338-44 (ISSN: 1432-2218). Department of Surgery, Mid Cheshire Hospitals NHS Foundation Trust, Leighton Hospital, Middlewich Road, Crewe, CW1 4QJ, UK.
4. Wei B; Qi CL; Chen TF; Zheng ZH; Huang JL; Hu BG; Wei HB. Laparoscopic versus open appendectomy for acute appendicitis: a metaanalysis. *Surg Endosc*. 2011; 25(4):1199-208 (ISSN:1432-2218).Department of Gastrointestinal Surgery, The Third Affiliated Hospital of Sun Yat-sen University, Guangzhou 510630, China.
5. O'Malley E; Boyle E; O'Callaghan A; Coffey JC; Walsh SR. Role of laparoscopy in penetrating abdominal trauma: a systematic review. *World J Surg*.2013;37(1):113-22(ISSN:1432-2323).Graduate Entry Medical School, University of Limerick, Castletroy, Limerick, Ireland.
6. Mallat AF; Mancini ML; Daley BJ; Enderson BL.The role of laparoscopy in trauma: a ten-year review of diagnosis and therapeutics. *Am Surg*. 2008; 74(12):1166-70 (ISSN: 0003-1348). Department of Surgery, University of Tennessee Medical Center at Knoxville, Knoxville, Tennessee 37920, USA.
7. Johnson JJ; Garwe T; Raines AR; Thurman JB; Carter S; Bender JS; Albrecht RM. The use of laparoscopy in the diagnosis and treatment of blunt and penetrating abdominal injuries: 10-year experience at a level 1 trauma center. *Am J Surg*. 2013; 205(3):317-20; discussion 321 (ISSN: 1879-1883). Department of Surgery, University of Oklahoma College of Medicine, 920 Stanton L. Young Blvd, WP 2140, Oklahoma City, OK 73104, USA.
8. Powell BS; Magnotti LJ; Schroepfel TJ; Finnell CW;Savage SA;Fischer PE;Fabian TC; Croce MA. Diagnostic laparoscopy for the evaluation of occult diaphragmatic injury following penetrating thoracoabdominal trauma. *Injury*. 2008; 39(5):530-4 (ISSN: 0020-1383). Department of Surgery, University of Tennessee Health Science Centre, Memphis, Tennessee.
9. Zantut LF<sup>1</sup>, Ivatury RR, Smith RS, Kawahara NT, Porter JM, Fry WR, Poggetti R, Birolini D, Organ CH Jr. *J Trauma*. 1997 May;42(5):825-9; discussion 829-31. Diagnostic and therapeutic laparoscopy for penetrating abdominal trauma: a multicenter experience. Department of Surgery, University of Sao Paulo, Brazil.
10. Cherkasov M; Sitnikov V; Sarkisyan B; Degtirev O; Turbin M; Yakuba A Laparoscopy versus laparotomy in management of abdominal trauma. *Surg Endosc*. 2008; 22(1):228-31 (ISSN: 1432-2218). Surgery Number 4, Rostov State Medical University, Rostov On Don, Russia.
11. Biffi WL; Kaups KL; Pham TN; Rowell SE; Jurkovich GJ; Burlew CC; Elterman J; Moore EE. Validating the Western Trauma Association algorithm for managing patients with anterior abdominal stab wounds: a Western Trauma Association multicenter trial. *J Trauma*. 2011; 71(6):1494-502 (ISSN: 1529-8809). Department of Surgery, Denver Health Medical Center/University of Colorado, Denver, Colorado 80204-4507, USA.
12. Kawahara NT; Alster C; Fujimura I; Poggetti RS; Birolini D.Standard examination system for laparoscopy in penetrating abdominal trauma. *J Trauma*. 2009; 67(3):589-95 (ISSN: 1529-8809).Laboratory of Surgical Pathophysiology Investigation (Lim 62), Department of Trauma, Hospital das Clínicas, University of Sao Paulo Medical School, São Paulo, Brazil.





This page is intentionally left blank