



GLOBAL JOURNAL OF MEDICAL RESEARCH: J
DENTISTRY AND OTOLARYNGOLOGY
Volume 14 Issue 3 Version 1.0 Year 2014
Type: Double Blind Peer Reviewed International Research Journal
Publisher: Global Journals Inc. (USA)
Online ISSN: 2249-4618 & Print ISSN: 0975-5888

Study of Pathological Variations of Solitary Thyroid Nodule

By Abdullah Al Mamun, Zahedul Alam, Rojibul Haque & Dewan M Hasan
National Institute of ENT, Bangladesh

Abstract- Objective: To find out the incidence of malignancy in patient with solitary thyroid nodule.

Methods: This cross-sectional study was carried out with 100 solitary thyroid nodular patients who admitted in Otolaryngology & Head-Neck Surgery Department of Sir Salimullah Medical College Mitford Hospital (SSMCMH) & Bangabondhu Sheikh Mujib Medical University (BSMMU), Dhaka, from July 2011 to December 2012, where all patients were admitted through out patient department. All patients were selected as per described criteria from the Department of Otolaryngology & Head-Neck Surgery, SSMCMH & BSMMU. Diagnosed the cases by detail history, clinical examination, investigations, analysed data presented by various tables, figures.

Results: In this study mean age of the patients of solitary thyroid nodule was 35.6 ± 13.54 years and the highest frequency (38%) was within 21-30 years of age with female predominance (78%). Thyroid swelling was the common presentation in all (100%) cases, some patients also presented with other symptoms like cervical lymphadenopathy 13(13%) cases, dysphagia 1(1%), dyspnoea 1(1%), hoarseness of voice 1(1%) case & no bone metastatic found.

Keywords: solitary thyroid nodule, papillary carcinoma, follicular carcinoma, medullary carcinoma.

GJMR-J Classification: NLMC Code: WK 200, WF 490



Strictly as per the compliance and regulations of:



Study of Pathological Variations of Solitary Thyroid Nodule

Abdullah Al Mamun ^α, Zahedul Alam ^σ, Rojibul Haque ^ρ & Dewan M Hasan ^ω

Abstract- Objective: To find out the incidence of malignancy in patient with solitary thyroid nodule.

Methods: This cross-sectional study was carried out with 100 solitary thyroid nodular patients who admitted in Otolaryngology & Head-Neck Surgery Department of Sir Salimullah Medical College Mitford Hospital (SSMCMH) & Bangabondhu Sheikh Mujib Medical University (BSMMU), Dhaka, from July 2011 to December 2012, where all patients were admitted through out patient department. All patients were selected as per described criteria from the Department of Otolaryngology & Head-Neck Surgery, SSMCMH & BSMMU. Diagnosed the cases by detail history, clinical examination, investigations, analysed data presented by various tables, figures.

Results: In this study mean age of the patients of solitary thyroid nodule was 35.6±13.54 years and the highest frequency (38%) was within 21-30 years of age with female predominance (78%). Thyroid swelling was the common presentation in all (100%) cases, some patients also presented with other symptoms like cervical lymphadenopathy 13(13%) cases, dysphagia 1(1%), dyspnoea 1(1%), hoarseness of voice 1(1%) case & no bone metastatic found. In this series of solitary thyroid nodules constituted 73% firm, 6% hard and 11% cystic. Malignancy was found more in firm nodule 13(72.22%). Isotopes scanning of the thyroid gland were done to see the functional status of the nodule. We found most 96(96%) of the nodules were cold & 4(4%) were warm nodule & no hot nodule found. In our study out of 96 cold nodular goiters we found 18(18.75%) malignant & no malignant case found from rest of 4 warm cases. In our study, out of 89 solid nodule 72(80.89%) were benign & 17(19.10%) nodule were malignant and out of 11 cystic nodule 10(90.9%) were benign & 1 (9.1%) was malignant. In this study, most of the benign & malignant nodules were predominantly solid. Study showed the malignancy is significantly ($p < 0.001$) more in solid than cystic solitary thyroid nodule. Final diagnosis in this study was on the basis of histopathological reports record. Out of 100 cases, 54 cases (54%) were proven as nodular goitre & 2% were thyroiditis in non-neoplastic lesion & in neoplastic lesion we found 26(26%) was benign (follicular adenoma) and 18(18%) cases were malignant. In our study among 18 malignant cases 15 (83.33%) were papillary carcinoma,

2(11.11%) were follicular carcinoma and 1(5.55%) case was medullary carcinoma. So, papillary carcinoma was more common among all thyroid malignancies in patients with solitary thyroid nodule.

Conclusion: In our series containing 18% malignancy in solitary thyroid nodule. So significant percentage of malignancy in STN is very important though it is a small nodular lesion. It is an important message to our fellows and practitioners to get appropriate medical attention for early diagnosis & proper management to reduce the morbidity and mortality.

Keywords: solitary thyroid nodule, papillary carcinoma, follicular carcinoma, medullary carcinoma.

I. INTRODUCTION

Thyroid gland and its enlargement are known since the time of Hippocrates. Among the endocrine organs, diseases of the thyroid gland are the most common. A good number of diseases affect the thyroid gland and almost all of them presents with nodular thyroid swelling. Nodular goiter remains a problem of enormous magnitude all over the world, although exact data on incidence and prevalence are unavailable. In our country the national prevalence rate is 10-15%, which indicates, the whole country is endemic. The endemicity varies from one place to another. The highest prevalence rate in Bangladesh is in the district of Rangpur and Jamalpur, the range varies from 21-30%. Nodular thyroid disease is more prevalent than diffuse goitre. In a report from the thyroid clinic, Bangabondhu Sheikh Mujib Medical University, Dhaka 32.67% of all thyroid patients had solitary nodules¹.

The solitary or isolated thyroid nodule may be defined as a discrete swelling in an otherwise impalpable gland. It is usually a benign lesion. It is common in clinical practice. The swelling is often noticed accidentally by the patient or drawn to her attention by a family member, neighbor, or a friend. The nodule may also be encountered as an incidental finding when a patient is examined for some unrelated disease. About 70% discrete thyroid swellings are clinically isolated. Thyroid nodules are common and are among 3-4% of the adult population in the UK and USA. They are 3-4 times more frequent in women than men. A nodule may be adenoma, cyst, multinodular goiter, thyroiditis and thyroid cancer².

The importance of solitary thyroid nodule lies in the significant risk of malignancy compared with other

Author α: Assistant Registrar (MS-ENT), Dept. of ENT, 300 Bed Hospital, Khanpur, Narayanganj, Bangladesh.

e-mail: mamunmail24@gmail.com

Author σ: Professor & Director, National Institute of ENT, Tejgaon, Dhaka, Bangladesh.

Author ρ: Associate professor, Dept. of ENT & HNS, Sir Salimullah Medical College Mitford Hospital, Dhaka, Bangladesh.

Author ω: Senior Consultant, Dept. of ENT & HNS, 300 Bed Hospital, Khanpur, Narayanganj, Bangladesh.

thyroid swelling. Many studies have been published on the risk of malignancy in patients with thyroid nodules; these studies show that the risk of malignancy is low, approximately 5%, unless the patient has an underlying risk factor, such as a history of external neck irradiation³. If imaging investigations shows the nodule to be truly solitary, then the likelihood of it being malignant increases to about 5-20%⁴, of which papillary carcinoma comprises about 80%, follicular carcinoma 10% and medullary carcinoma 5%⁵, but in another study it showed papillary carcinoma comprises about 60% and follicular carcinoma 18%⁶.

Screening of large numbers of patients previously unsuspected of having goiter suggests that the incidence of the isolated thyroid nodule in the general population may be of the order of 4-7%⁷. A thyroid nodule larger than 1 cm in diameter is usually palpable. However, the detection of a nodule by palpation also depends on its location within the thyroid gland, on the structure of the patient's neck and on the experience of the examiner.

It has been estimated that palpable thyroid nodules are present in 4-7% of the population, but when examined by ultrasound, as many as 50-70% of subjects with no history of thyroid disease have been found to have incidentally discovered thyroid nodules, many of which are not palpable⁸. In addition, nodular thyroid disease is more common in the elderly, a population subgroup, which is steadily increasing⁹.

Laboratory investigations other than FNAC have limited role in finding out the nature of thyroid swelling. Isotope scan can demonstrate the functioning capacity of the nodule but cannot predict the histopathological character¹⁰.

Fine needle aspiration cytology (FNAC) is considered as the most reliable test for the diagnosis of thyroid nodules¹¹. Many investigators have tried to point out few ultrasonographic features in order to identify those lesions, which are at a higher risk of malignancy, especially in non-palpable thyroid nodules¹². Pre-operative assessment of thyroid nodules is generally performed by radio- nuclide scanning and fine needle aspiration (FNA). FNA biopsy is described as the most preferred test that has improved selection of patients for thyroid surgery. Several studies have concluded that the risk of thyroid cancer is less with multiple nodules than with solitary nodules^{13, 14} but other studies have not found any difference in risk¹⁵. It is becoming increasingly clear that high-resolution ultrasonography is better than physical examination⁹ or other imaging techniques¹⁶ in detecting thyroid nodules.

This study has been carried out to find out the relative frequency of pathological types, incidence of malignancy in solitary thyroid nodule and its age & sex variation. This study also carried out to review the existing protocol for the management of solitary thyroid nodules in our country and to assess the accuracy of

the available diagnostic modalities for appropriate selection of patients

II. METHODS

This cross-sectional study was carried out with 100 solitary thyroid nodular patients who admitted in Otolaryngology & Head-Neck surgery ward of Sir Salimullah Medical College Mitford Hospital & BSMMU, Dhaka, from July 2011 to December 2012. All patients were admitted from Out Patient Department. A detailed history was taken (including family history & history of exposure of radiation) and thorough physical examinations including general examinations, examinations of ear, nose, throat, thyroid gland, neck, hand signs, eye signs and systemic examinations were carried out. All patients were analyzed in various aspects like age, sex, occupation, mode of presentation. Routine investigations like Blood, Urine, CXR, and ECG were done. Special investigations like thyroid function test- serum T3, T4, TSH done. To detect single or multiple nodules, solid or cystic condition of nodules-USG of thyroid gland done. Preoperative FNAC of thyroid gland done to detect benign or malignant condition. X-ray neck both view done to see retrosternal extension of gland, position of trachea, patency of airway.

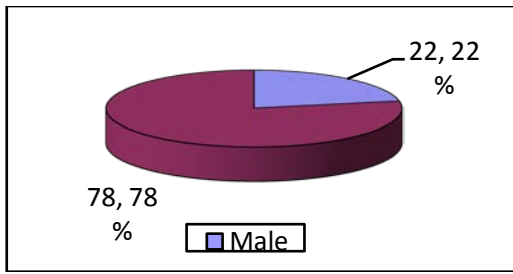
Thyroid scan done to see functional status of gland like cold, warm & hot nodule. FNAC findings were recorded & then after surgery histopathology reports were recorded & FNAC findings were compared with histopathological reports. Data were processed and analyzed by using computer based programmed SPSS-16 (Statistical Package for Social Sciences). The quantitative data were analyzed by mean, standard deviation. The qualitative data were analyzed by Pearson Chi-square (χ^2) test with 95% confidence interval to make inference.

III. RESULTS

Table 1 : Age distribution of the study subjects (n=100)

| Age group(Years) | Frequency | Percentage |
|------------------|-----------|------------|
| 10-20 | 08 | 08.0 |
| 21-30 | 38 | 38.0 |
| 31-40 | 28 | 28.0 |
| 41-50 | 14 | 14.0 |
| 51-60 | 06 | 06.0 |
| > 60 | 06 | 06.0 |
| Total | 100 | 100.0 |

Mean(\pm SD)age=35.60(\pm 13.54)yrs, 13 -75 yrs



M: F = 1: 3.54

Figure 1 : Sex distribution of the study subjects (n=100)

Table 2 : Occupational status of the study subjects (n=100)

| Occupation | Frequency | Percentage |
|------------|-----------|------------|
| Service | 14 | 14.0 |
| Business | 02 | 02.0 |
| Housewife | 68 | 68.0 |
| Others | 16 | 16.0 |
| Total | 100 | 100.0 |

Table 3 : Sex distribution in carcinoma in solitary thyroid nodule (n=100)

| Histopathological findings | Sex | | | P value |
|----------------------------|----------|----------|----------|---------|
| | Total | Male | Female | |
| Malignant | 18(18) | 06(27.3) | 12(15.4) | 0.21 |
| Benign | 82(82) | 16(72.7) | 66(84.6) | |
| Total | 100(100) | 22(100) | 78(100) | |

$\chi^2-0.94$ Values in parentheses are percentages

Table 4 : Clinical presentation of cases of solitary thyroid nodule

| Sign and symptoms | Frequency | Percentage |
|-------------------------------|-----------|------------|
| Swelling in front of neck | 100 | 100 |
| Palpable cervical lymph nodes | 13 | 13 |
| Dysphagia | 01 | 01 |
| Dyspnoea | 01 | 01 |
| Hoarseness of voice | 01 | 01 |
| Bone pain | 00 | 00 |

Table 5 : Involvement of site of solitary nodule in the thyroid gland

| Site | Frequency | Percentage |
|----------------------------|-----------|------------|
| Right lobe | 56 | 56.0 |
| Left lobe | 38 | 38.0 |
| Both lobe | 04 | 04.0 |
| Isthmus with adjacent lobe | 02 | 02.0 |
| Total | 100 | 100.0 |

Table 6 : Distribution of cases according to the histopathology report & the time elapsed after the nodule has developed

| Duration of nodule development | Histopathological findings | | Total | P value |
|--------------------------------|----------------------------|-----------------|----------|-------------------|
| | Benign n (%) | Malignant n (%) | | |
| < 1 yr | 10(12.19) | 06(33.33) | 16(16) | 0.01 ^s |
| 1-2 yrs | 14(17.07) | 10(55.56) | 24(24) | |
| 2-5 yrs | 34(41.46) | 02(11.11) | 36(36) | |
| > 5 yrs | 24(29.26) | 00(00) | 24(24) | |
| Total | 82(100) | 18(100) | 100(100) | |

$\chi^2 = 11.14$, Values in parentheses are percentages



Table 7 : Relation of thyroid scans with histopathological findings

| Histopathological study | Thyroid scan | |
|-------------------------|--------------|--------|
| | Cold | Warm |
| Benign | 78(81.25) | 4(100) |
| Malignant | 18(18.75) | 00(00) |
| Total | 96(100) | 4(100) |

Values in parentheses are percentage

Table 8 : Association of histopathological findings with the consistency of STN

| Consistency | Histopathological findings | | Total | χ^2 (P value) |
|-------------|----------------------------|-------------------|----------|---------------------------|
| | Benign n(%) | Malignant n(%) | | |
| Soft | 08(9.75) | 00(00) | 08(08) | 0.81(0.37 ^{ns}) |
| Cystic | 10(12.19) | 01(5.55) | 11(11) | 0.16(0.34 ^{ns}) |
| Firm | 62(75.61) | 13(72.22) | 75(75) | 0.04(0.99 ^{ns}) |
| Hard | 02(2.43) | 04(22.22) | 06(06) | 8.26(0.009 ^s) |
| Total | 82(100) | 18(100) | 100(100) | |

Chi-square test

Table 9 : Fine needle aspiration cytological variations of solitary thyroid nodules

| Diagnosis | Number | Percentage | |
|----------------|----------------------------|------------|----|
| Non neoplastic | Colloid nodule | 46 | 46 |
| | Thyroiditis | 02 | 02 |
| | Colloid degeneration | 6 | 6 |
| | Cellular Follicular lesion | 30 | 30 |
| Neoplastic | Papillary carcinoma | 13 | 13 |
| | Medullary carcinoma | 01 | 01 |
| | Suspicious | 02 | 02 |
| Total | 100 | 100 | |

Table 10 : Histopathological variations of solitary thyroid nodules

| Diagnosis | Number | Percentage | |
|---------------------|----------------------|------------|----|
| Non neoplastic | Nodular goiter | 54 | 54 |
| | Thyroiditis | 02 | 02 |
| Neoplastic | Benign | | |
| | Follicular adenoma | 26 | 26 |
| | Papillary carcinoma | 15 | 15 |
| | Malignant | | |
| | Follicular carcinoma | 02 | 02 |
| Medullary carcinoma | 01 | 01 | |
| Total | 100 | 100 | |

Table 11 : Results of FNAC & corresponding final histopathology

| FNAC findings | Final histopathological findings | | P value | |
|------------------------|----------------------------------|-----------|-----------|---------------------|
| | Total | Benign | | Malignant |
| Malignant cell | 84(84) | 80(97.56) | 04(22.22) | <0.001 ^s |
| Absent | | | | |
| Malignant cell present | 16(16) | 02(2.43) | 14(88.88) | |
| Total | 100(100) | 82(100) | 18(100) | |

$\chi^2 = 56.85$, *Values in parentheses are percentages.*

Table 12 : Histopathological findings of the study subjects. (n=100)

| Histopathological findings | Frequency | Percent |
|----------------------------|-----------|---------|
| Benign | 82 | 82.0 |
| Malignant | 18 | 18.0 |
| Total | 100 | 100.0 |

Table 13 : Pattern of malignancy in solitary thyroid nodule according to histopathology

| Type of malignancy | No of cases | Percent |
|----------------------|-------------|---------|
| Papillary carcinoma | 15 | 83.33 |
| Follicular carcinoma | 02 | 11.11 |
| Medullary carcinoma | 01 | 5.55 |
| Total | 18 | 100 |

Table 14 : Distribution of final benign & malignant lesion in according to preoperative solid & cystic findings

| Histopathological findings | USG findings | | Total | P value |
|----------------------------|--------------|-----------|----------|---------------------|
| | Cystic | Solid | | |
| Malignant | 01(09.1) | 17(19.10) | 18(18) | <0.001 ^s |
| Benign | 10(90.9) | 72(80.89) | 82(82) | |
| Total | 11(100) | 89(100) | 100(100) | |

$\chi^2 = 23.92$, Values in parentheses are percentages

IV. DISCUSSION

This cross sectional study was done in the department of Otolaryngology & Head-Neck surgery, Sir Salimullah Medical College Mitford Hospital and BSMMU, Dhaka from July 2011 to December 2012. For this study, 100 patients of STN were studied by detailed history, clinical examination, thyroid hormone assay, ultrasonogram, thyroid scan, FNAC and histopathological examinations.

In our study mean age of the patients of solitary thyroid nodule was 35.6 ± 13.54 years and the highest frequency (38%) was within 21-30 years of age. Whereas in the study of Islam et al. 2009, showed the majority of the patients were within 21-40 yrs of age. In a study¹⁷ they found the age range of their patients were 11-70 years of age. The youngest patient in our study was a boy of 13 years with a papillary carcinoma and the oldest patients was a man of 75 years with medullary carcinoma. The youngest patient and oldest patients of this study both had been suffering from malignant thyroid disease, the extreme of ages show less incidence of thyroid disease but has a more chance to be malignant.

In this series, out of 100 patients, male were 22 (22%) and female were 78 (78%). Male female ratio was 1: 3.54. In a study¹⁷ solitary thyroid nodules were more common in female, where male female ratio was 1:2.2. This female preponderance is reflected in all studies including the present. The cause of high male to female ratio in this series can be explained by most of the patients are from nonendemic area¹⁸. Here we may recall the findings of Kilopatric et al. who found a female to male ratio of 4:1 in nonendemic area¹⁹. It is due to

fact that thyroid disorder is female prone owing to the presence of estrogen receptors in the thyroid tissue⁶. In this study the commonest occupational group was house wife (68%).

All solitary nodules are not a single clinical entity. So it is very difficult to comments regarding the nature of solitary nodule purely on the basis of clinical ground. But hoarseness of voice, hard irregular nodule, palpable cervical lymph node, extreme of age, male sex are always suspicious for malignancy in solitary thyroid nodule²⁰. Regarding presenting complaints we have found that all of the patients with neck swelling presents within variable durations. Some patient also presented with other symptoms like cervical lymphadenopathy 13(13%) cases, dysphagia 1(1%), dyspnoea 1(1%), hoarseness of voice 1(1%) case & no bone metastatic found. Among 18 malignant cases 10(55.56%) cases presented within 2 years but out of 82 benign cases only 14(17.07%) cases presented within 2 years. It is well supported by others studies^{21,22}. Where duration of swelling prior to the presentation was from 6 months to 3 yrs¹⁷. Nodular goiter with large swelling may be associated with difficulty in respiration or rarely in deglutition which is due to pressure on trachea or oesophagus²³.

In this series we have seen that nodules were found more in right lobe than left. There is yet no reported predilection for any specific site and no reason has been put forward for such a predilection. Similar findings were noted by many authors^{24,25}. We found 56 nodules in right lobe, 38 nodules in left lobe, 4 nodules in both lobes and 2 nodules in the junctional region between isthmus and one lobe.

Firm nodules are the commonest form of solitary thyroid nodule. In this series of solitary thyroid nodules constituted 73% firm, 6% hard and 11% cystic. Malignancy was found more in firm nodule 13(72.22%). Islam et al. 2009, found majority of the nodules were firm (72.03%), others were hard(16.95%) and cystic (11.02%). Malignant lesion was more common in hard nodule (70%). Here hardness of nodule was due to malignancy and inflammatory conditions. Among 6 hard nodules, 4 were diagnosed as malignancy and 2 were diagnosed histopathologically as thyroiditis. So hardness is not conclusive but an important indication for malignancy. Hardness and irregularity, due to calcification, may simulate carcinoma⁶.

Investigations are essential to establish preoperative physical, function status and cytopathological nature of solitary nodule of thyroid²⁶.

All patients of this study have done thyroid hormone profile and show value within normal limit. Isotopes scanning of the thyroid gland were done to see the functional status of the nodule. We found most 96(96%) of the nodules were cold & 4(4%) were warm nodule & no hot nodule found. In our study out of 96 cold nodular goiters we found 18(18.75 %) malignant & no malignant case found from rest of 4 warm cases. In a study showed that on thyroid scan out of 40 patients (80%) having cold nodule & 10 patients (20%) had hot nodule²⁷. Most of the nodules were cold (66.10%) among them 25.6% cases were malignant, followed by warm (30.5%) and hot (3.3%)²⁸.

Fine needle aspiration cytology (FNAC) is a very important, highly sensitive and minimally invasive preoperative diagnostic tool²³. According to a study FNAC is a gold standard for preoperative assessment of thyroid nodules. Early and accurate diagnosis reduces surgical intervention, morbidity and mortality²⁹. In our study of FNAC of STN we found colloid nodule 46%, thyroiditis 2%, colloid degeneration 6%, cellular follicular lesion 30%, papillary carcinoma 13%, medullary carcinoma 1% & non conclusive 2%. On FNAC majority of STN were benign with being more common¹⁷. FNAC cannot distinguish between follicular adenoma and follicular carcinoma. In our study sensitivity & specificity of FNAC was 77.77% & 97% respectively. Where other study showed sensitivity and specificity of FNAC was 90% and 100%, respectively²⁹. Basharat R et al. 2011, showed sensitivity & specificity of FNAC 80% & 97.7% respectively in her study. So FNAC is an important preoperative diagnostic tool for STN.

Final diagnosis in this study was on the basis of histopathological reports record. Out of 100 cases, 54 cases (54%) were proven as nodular goitre & 2 % were thyroiditis in non-neoplastic lesion & in neoplastic lesion we found 26(26%) was benign (follicular adenoma) and 18(18%) cases were malignant. In our study among 18 malignant cases 15(83.33%) were papillary carcinoma, 2(11.11%) were follicular carcinoma and 1(5.55%) case

was medullary carcinoma. In a study 13.9% of patients of STN was found to be malignant³⁰. A study showed that 13.33% of STN were found to have malignant lesions & 86.67% were benign³¹. Papillary carcinoma was the most common malignancy (50%) found in his study. Male patients with solitary thyroid nodule showed a higher incidence of malignancy (17.65%) as compared to females (11.63%). In our study we found frequency of malignancy in case of male was 27.3% & in case of female 15.4 %. Venkatachalapathy et al. 2012, found the incidence of malignancy in their series in STN was 18%. Islam et al. 2009, in their study found 18.65% of STN to be malignant & out of them 16 (72.72%) cases were papillary carcinoma, 4 (18.18%) cases were follicular carcinoma and 2(9.1%) cases were medullary carcinoma. It showed a clear predominance of papillary over follicular and medullary carcinoma. According to Watkinson (2000), frequency of papillary carcinoma is 80% and follicular carcinoma is 10%. Some study showed that papillary carcinoma comprises about 60% of all thyroid cancer³² and follicular carcinoma comprises 18% of all malignant thyroid neoplasm⁶. So, papillary carcinoma was more common among all thyroid malignancies in patients with solitary thyroid nodule. Ultrasonography is used to establish physical characteristics of nodule like the size, echo-structure (solid or cystic), shape and number of nodule(s), and extranodular thyroid tissue. In our study of ultrasonography we found 89(89%) nodules were solid, 11(11%) were cystic. In our study, out of 89 solid nodule 72(80.89%) were benign & 17(19.10%) nodule were malignant and out of 11 cystic nodule 10(90.9%) were benign & 1 (9.1%) was malignant. In our study, most of the benign & malignant nodules were predominantly solid. Study showed the malignancy is significantly ($p < 0.001$) more in solid than cystic solitary thyroid nodule. Our study correspond with a study where he showed of cystic thyroid lesions, 4% were simple cysts, 82% were degenerating benign adenomas or colloid nodules and 14% were malignant compared with 23% of solid lesions that were malignant³³. Cathy Crenshaw Doheny also mentioned In a web journal found that a solid thyroid nodule is more likely than a cystic nodule to be malignant³⁴. More than 90% of all solid nodules, however, are benign. A study showed 9% incidence of malignancy in solid nodules & no malignancy in cystic nodules³⁵. Whereas other found incidence of carcinoma in cystic lesion $< 2\%$ ³⁶.

As this study had been carried out over a limited period of time with a limited number of patients, it could not have been large enough to be of reasonable precision. All the facts and figures mentioned here may considerably vary from those of large series covering wide range of time, but still then, as the cases of this study were collected from tertiary level hospitals in our country, this study had some credentials in reflecting the facts regarding distribution and type of malignancy in solitary thyroid nodules.

V. CONCLUSION

We have observed worldwide malignancy in STN ranging from 16-30%³⁷. We found in our series containing 18% malignancy in solitary thyroid nodule. So significant percentage of malignancy in STN is very important though it is a small nodular lesion. As small lesion of STN sometimes is overlooked so it is an important message to our fellows and practitioners to get appropriate medical attention for early diagnosis & proper management to reduce the morbidity and mortality.

REFERENCES RÉFÉRENCES REFERENCIAS

- Ala Uddin M & Joarder AH (2003). Management of thyroid carcinoma. *Bangladesh J of otorhinolaryngology*; 9(1/2): 23-37.
- Thomas V, McCaffrey (2000). Evaluation of thyroid nodule. *Cancer Control*; 7: 223-228.
- Wienke JR, Chong WK, Fielding JR, Zou KH, Mittelstaedt CA (2003). Sonographic features of benign thyroid nodules: interobserver reliability and overlap with malignancy. *J Ultrasound Med*; 22:1027-1031.
- Belfiore A, Giuffrida D, La Rosa GL, et al (1968). High frequency of cancer in cold thyroid nodules occurring at young age. *Acta Endocrinol. (Copenh)*; 121: 197- 202.
- Watkinson JC, Gaze MN, Wilson JA (2000). Tumors of the thyroid and parathyroid gland. *Stell and Maran's Head Neck Surgery, 4th edn., Butterworth Heinemann*: 458-484.
- Krukowski ZH (2004). The thyroid gland and thyroglossal tract, *Baily & Love's short practice of surgery, 24th ed. London. Hodder education*, 776-804.
- Vander JB, Gaston EA, Dawber TR (1968). The significance of nontoxic thyroid nodules: final report of a 15-year study of the incidence of thyroid malignancy. *Ann. Intern. Med*; 69: 537 -540.
- Papini E, Guglielmi R, Bianchini A, Crescenzi A, Taccagna S, Nardi F, Panuzzi C, Rinaldi R, Toscano V, Pacella C(2002). Risk of malignancy in nonpalpable thyroid nodules: predictive value of ultrasound and color-doppler features. *Journal of Clinical Endocrinology and Metabolism*; 87: 1941-1946.
- Gharib H, James EM, Charboneau JW, Naessens JM, Offord KP, Gorman CA(1987). Suppressive therapy with levothyroxine for solitary thyroid nodules: a double blind controlled clinical study. *N Engl J Med.*; 317: 70-75.
- Sattar MA, Alam MM, Haider A (2003). Clinicopathological study of solitary cold thyroid nodule. *Bangladesh JOTolaryngol*; 9(1/2): 24-27.
- Lyshchik A, Higashi T, Asato R, Tanaka S, Ito J, Mai JJ, Pellot- Barakat C, Insana MF, Brill AB, Saga T, Hiraoka M ,Togashi KL(2005). Thyroid gland tumor diagnosis at US Elastography. *Radiology*; 237: 202-211.
- Kang HW, No H, Chung JH, Min YK, Lee MS, Lee MK, Yang JH, Kim KW(2004). Prevalence, clinical and ultrasonographic characteristics of thyroid incidentalomas. *Thyroid* ; 14: 29-33.
- Brown CL (1981). Pathology of the cold nodule. *Clin Endocrinol Metab*; 10: 235- 245.
- Cole WH (1991). Incidence of carcinoma of the thyroid in nodular goiter. *Semin Surg Oncol*; 7: 61-63.
- Belfiore A, La Rosa GL, La Porta GA et al. (1992). Cancer risk in patients with cold thyroid nodules: relevance of iodine intake, sex, age, and multinodularity. *Am J Med.*; 93: 363-369.
- Solbiati L, Volterrani L, Rizzato G, et al (1985). The thyroid gland with low uptake lesions: evaluation by ultrasound. *Radiology*; 155: 187-191.
- Venkatachalapathy T S ,Sreeramulu P N, Prathima S, Kumar K(2012). A prospective study of clinical, sonological & pathological evaluation of thyroid nodule. *J Biosci Tech*; 3 (1), 474- 478.
- Inder JC, David HS (1997). Thyroid function test and there alteration by drugs. *The thyroid nodules clinical nuclear medicine*; 2(9):324-333.
- Ashraf SA, Matin ASM (1996). A Review of thyroid diseases in Bangladesh. *Journal of BCPS*. 2(1): 6-10.
- Rains AJH, Charles VM (2004). *Bailey and Love's short practice of surgery, twenty third ed. London, ELBS* :707-733.
- Cady B, Sedgewick CE, Meissner WA, (1979). Risk factor analysis in differentiated thyroid cancer. *AMJ. Surg*, 136; 107-112.
- Harmo J, Clark OH (1979). Significance of lymph node metastasis in differentiated thyroid cancer. *Cancer*; 10(6):230-37.
- Stark DD, Clark OH, Gooding GAW, Moss AA (1983). High-resolution ultrasonography and computed tomography of thyroid lesions in patients with hyperparathyroidism. *Surgery*; 94.
- Messaris G, Kyriakov K, Vasilopoulos P, and Tountas C (1974). The single thyroid nodule and carcinoma. *Br J Surg*, 61, 943.
- Gupta M, Gupta S, Gupta V. Correlation of fine needle aspiration cytology with histopathology in the diagnosis of solitary thyroid nodule. *J Thyroid Res* 2010, 2010, 379051
- Dudley H, Pories WJ (1986). *General Principles, Breast and Extracranial endocrines in Rob and Smith's Operative Surgery, 4th edn. London. Butterworth Scientific*:332-386.
- Basharat R,Hussain M, Saeed S, Hamid T(2011). Comparison of Fine Needle Aspiration Cytology and Thyroid Scan in Solitary Thyroid Nodule. *SAGE-Hindawi Access to Research Pathology Research*

International Volume 2011, Article ID 754041, 9 pages doi:10.4061/2011/754041

28. Islam R, Ekramuddaula AFM, Alam MS , Kabir MS , Hossain D, Alauddin M(2009). Frequency & pattern of malignancy in solitary thyroid nodule. Bangladesh J of Otorhinolaryngology; 15(1): 1-5
29. Chandanwale S et al. (2012). Research article: Clinicopathological correlation of thyroid nodules. Int J Pharm Biomed Sci; 3(3), 97-102
30. Khairy GA (2004).Solitary thyroid nodule:the risk of cancer & the extent of surgical therapy.East african medical journal;81(9),459-461.
31. Tarrar AM, Khan OU, Walah MS, Waqas A, Ilyas S, Raza A(2010).Solitary thyroid nodule. Professional Med J; 17(4): 598-602.
32. Shaheen OH (1997). The thyroid gland. In: Kerr AG ed. Scott-Brown's oto laryngology. 6th Ed vol-5. London, Butter worth Heinemann : 5/18/1-5/18/22.
33. Edith T. de los Santos, MD; Sedigheh Keyhani-Rofagha, MD; Jerome J. Cunningham, MD; Ernest L. Mazzaferri, MD(1990). Cystic Thyroid NodulesThe Dilemma of Malignant Lesions. Arch Intern Med.; 150(7):1422-1427
34. Dohney CC (2012). Clear answers for common questions of thyroid nodule available from <http://www.wiseGEEK.com>, accessed 10 August,2012. Thyroid nodule.com
35. Raza S, Raza H, Zahid Z (2006). FNAC in management of solitary thyroid nodule. Professional Med J; 13: 596.
36. Ergete W, Abebe D(2002). Discordance rate between thyroid FNAC & histopathology diagnosis. Ethiopian J Health Dev.; 16: 227.
37. Abdullah M (2002). Thyroid cancer: The Kuala Lumpur experience. ANZ J Surg; 72:660-4.