



GLOBAL JOURNAL OF MEDICAL RESEARCH: J
DENTISTRY AND OTOLARYNGOLOGY
Volume 14 Issue 2 Version 1.0 Year 2014
Type: Double Blind Peer Reviewed International Research Journal
Publisher: Global Journals Inc. (USA)
Online ISSN: 2249-4618 & Print ISSN: 0975-5888

A Comparative Study between IHC in Frozen Sections and Formalin Fixed Sections and their Clinical Significance- A Retrospective Study

By Dr. Minal Chaudhary, Dr. Deepali Jain, Dr. Madhuri Gawande & Dr. Swati Patil

Sharad Pawar Dental College, Sawangi, India

Abstract- Aim and Objective: Comparison of IHC expression of P53 protein in frozen section versus routine paraffin embedded section in OSCC.

Materials and Methods: Patients diagnosed with OSCC were selected from the Department Of Oral and Maxillofacial Surgery of Sharad Pawar Dental College, Sawangi, During curative surgery tissue sections were obtained for frozen IHC and paraffin embedded sections were obtained from routinely processed resected tissue which were sent for histopathological diagnosis were also subjected to IHC for the purpose of the study. The tissue when then assessed to determine the expression of p53 protein.

Results: Sharper and more extensive p53 protein expression was observed in frozen section as compared to formalin fixed paraffin embedded sections. This is thought to be due to the blockage of antigen sites by formalin.

Conclusion: This study is of great significance to the pathologist who routinely assess IHC and reports on frozen section as diagnostic tools to guide the surgeon in order to determine the extent to which the resection should be carried out.

GJMR-J Classification: NLMC Code: WU 158



A COMPARATIVE STUDY BETWEEN IHC IN FROZEN SECTIONS AND FORMALIN FIXED SECTIONS AND THEIR CLINICAL SIGNIFICANCE- A RETROSPECTIVE STUDY

Strictly as per the compliance and regulations of:



© 2014. Dr. Minal Chaudhary, Dr. Deepali Jain, Dr. Madhuri Gawande & Dr. Swati Patil. This is a research/review paper, distributed under the terms of the Creative Commons Attribution-Noncommercial 3.0 Unported License (<http://creativecommons.org/licenses/by-nc/3.0/>), permitting all non-commercial use, distribution, and reproduction in any medium, provided the original work is properly cited.

A Comparative Study between IHC in Frozen Sections and Formalin Fixed Sections and their Clinical Significance- A Retrospective Study

Dr. Minal Chaudhary ^α, Dr. Deepali Jain ^ο, Dr. Madhuri Gawande ^ρ & Dr. Swati Patil ^ω

Abstract- Aim and Objective: Comparison of IHC expression of P53 protein in frozen section versus routine paraffin embedded section in OSCC.

Materials and Methods: Patients diagnosed with OSCC were selected from the Department Of Oral and Maxillofacial Surgery of Sharad Pawar Dental College, Sawangi, During curative surgery tissue sections were obtained for frozen IHC and paraffin embedded sections were obtained from routinely processed resected tissue which were sent for histopathological diagnosis were also subjected to IHC for the purpose of the study. The tissue when then assessed to determine the expression of p53 protein.

Results: Sharper and more extensive p53 protein expression was observed in frozen section as compared to formalin fixed paraffin embedded sections. This is thought to be due to the blockage of antigen sites by formalin.

Conclusion: This study is of great significance to the pathologist who routinely assess IHC and reports on frozen section as diagnostic tools to guide the surgeon in order to determine the extent to which the resection should be carried out. Hence, we can conclude that frozen section is more derivative in accordance with time as compared to formalin fixed tissue for determining the expression and as an important investigation to modify resection by using various tumor markers. In our study, we also considered conduction of IHC for margins during surgical procedure in order to guide the surgeon whether the margins are positive or negative and if the resection has to be extended or not. IHC here was conducted in a time period of 2 hours by polymer technique. Hence, an important and more definitive diagnostic tool for immediate results.

I. INTRODUCTION

Frozen sections are immediately obtained during surgical procedure. Whereas, the formalin fixed sections are obtained during incisional biopsy which is taken in order to attain a definitive diagnosis and resected specimens which are obtained as post-surgical procedure. These tissues are fixed in neutral buffered formalin for 24 hours and then embedded in paraffin wax for the preparation of blocks from which sections are prepared for routine hematoxylin and eosin staining and also for IHC.

Immunohistochemistry is an indispensable tool for diagnostic as well as research purpose in human

disease, and is widely employed in establishing diagnosis. It can be conducted on frozen section and formalin fixed section. It is a method for demonstrating the presence and location of proteins in tissue sections.

Though the procedure is less sensitive quantitatively than others, it enables the observation of processes in the context of intact tissue. This is especially useful for assessing the progression and treatment of diseases such as cancer.

In general, the information gained from IHC combined with microscopy literally provides a "big picture" that can help make sense of data obtained using other methods. Immunohistochemical staining is accomplished with antibodies that recognize the target protein.

Since antibodies are highly specific, the antibody will bind only to the protein of interest in the tissue section. The antibody-antigen interaction is then visualized using either chromogenic detection, in which an enzyme conjugated to the antibody cleaves a substrate to produce a colored precipitate at the location of the protein.

Mutation of the p53 tumor suppressor gene is the most frequent abnormality in various human tumors. More than 95% of these alterations are missense mutations which are scattered in the central part of the gene. Although all these mutations lead to the inactivation of the biological properties of the p53 protein, they also have dramatic consequences in term of p53 stability. Mutant p53 protein, which takes on an abnormal conformation, is more stable than the wild-type (half-life of several hours compared to 20 minutes for the wild type p53), accumulates in the nucleus of neoplastic cells and thus becomes immunologically detectable. An important consequence of this phenomenon is that positive immunostaining is indicative of abnormalities of the p53 gene and its product.

II. MATERIAL AND METHODS

The study was carried out at Sharad Pawar Dental College, Sawangi, Wardha in the Department of Oral and Maxillofacial Pathology. 30 samples were selected who had been diagnosed clinically and histologically with OSCC. Patients consent was taken

Author ^α ^ο ^ρ ^ω : Sharad Pawar Dental College, Sawangi (Dmimsu).
e-mail: drdjain0211@gmail.com

prior to the conduction of the study. The IHC procedure which was carried out for the purpose of this study was Universal immuno enzyme technique

These samples had been procured during the curative surgical procedure for frozen section and later from resected specimen for paraffin embedded sections. These samples were then subjected to IHC staining for p53 antibody.

For frozen sections the tissue sample obtained during the surgical procedure were samples frozen in the cryostat machine after which tissue sections 2-3 micron meter thick were sectioned in the machine collected on silane coated slides and fixed in pre-cooled acetone for a period of 10 minutes.

Which was followed by application of peroxidase block for a period of 20 minutes followed by washing in Tris buffered solution (TBS) for 5minutes after which the application of p53 antibody (clone DO-7) after which it was washed in TBS for 10 minutes.

The application of HRP labeled polymer antibody is done for a period of 30 minutes after which it was washed in TBS for 10 minutes.

Finally, the application of DAB and hematoxylin is done for 30 minutes, after which is washed for 10 minutes with TBS. Similar, procedure was carried out for IHC in paraffin embedded sections which was also collected on silane coated slides.

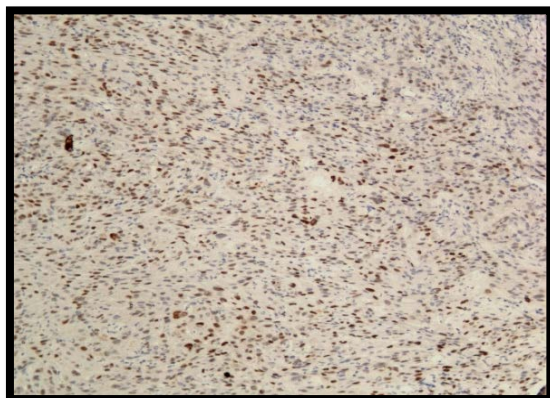
The fixation here is done with Neutral buffered formalin for 24 hours. And the antigen retrieval is done for a period of 30 minutes. The remaining procedure for these sections remains the same as the latter.

The complete procedure of IHC staining in frozen section requires a time period of approximately 2 hours.

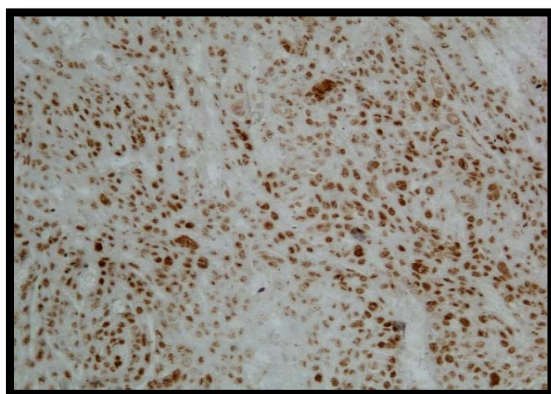
III. RESULTS

25 out of 30 samples exhibited positive staining for frozen sections as well as paraffin embedded sections. More sharper and extensive p53 protein expression was seen in frozen section as compared to formalin fixed paraffin embedded sections.

However the cellular morphology is more definite in formalin fixed tissue. This is because of the loss of antigen during tissue handling, fixation and processing.



Expression of p53 in Formalin fixed tissue, (10x view)



Expression of p53 in Frozen tissue, (10x view)

Therefore, we can determine that frozen section is more derivative in accordance with time as compared to formalin fixed tissues for determining the expression of p53 by IHC and as an important investigation to modify resection by using various tumor markers.

It will also act as a guide to the surgeon in order to determine where to stop the resection which will also help in preservation of important structures which

otherwise might have been resected to rule out the possibility of recurrence. Hence, ultimately be beneficial to the patient as well.

IV. DISCUSSION

It has been observed that patients suffering from OSCC have very low that is about 5 year survival rate of 50%. No increase in the 5 year survival rate of

patients with OSCC has been documented in the last 10 years. The main cause of death from OSCC after surgery is either due to formation of second primary tumor or recurrence of OSCC.

It is here that the role of field cancerization comes into play. In many cases field cancerization cannot be diagnosed by routine hematoxylin and eosin staining procedure. Hence, arises the need for more aggressive treatment modalities and newer diagnostic tools. We advocate the identification and removal of cancer and field on frozen section IHC as a routine treatment protocol for better prognosis.

IHC has frequently been considered a domain of research rather than for treatment and routine diagnostic procedure. There is an urgent need to change this line of thinking and integrate frozen IHC as a routine diagnostic tool for better assessment of margins and fields which will lead to better treatment and improved survival rate in patients with OSCC. Frozen IHC thus can be an important diagnostic, prognostic as well as research tool.

Removal of modified radical neck dissection protocol and repair requires a time period of about 5 to 6 hours.

Frozen section IHC which is an important diagnostic tool can be incorporated as a routinely used procedure during the course of surgery.

This could help in better management of margins which remain undetected otherwise but show positivity with molecular markers. Hence, the management of such condition on priority basis during surgical intervention could lead to better prognosis in patients with OSCC and will negate the need for recurrent surgeries.

V. CONCLUSION

We conclude that frozen section IHC, is a viable technique which can be carried out during the course of surgical intervention and the result equals if not exceeds the results that are seen by conventional IHC procedure having equally significant prognostic value.

Also, though technique sensitive it is an easy procedure to conduct and does not require special training and can be conducted by technician who is able to perform routine IHC.

This procedure requires a time period of only 2 hours as compared to conventional IHC that requires approximately 26 hours.

Also, most of the antibodies that can be used for conventional IHC can be used for frozen IHC as well. There are certain misconceptions about frozen IHC such as it is difficult to conduct being time consuming and requires special training.

REFERENCES RÉFÉRENCES REFERENCIAS

1. Immunocytochemical Methods and Protocols. 2nd Edition. Edited by Lorette C. Javois. Humana Press, Totowa, New Jersey.

2. Giorno R. A comparison of two immunoperoxidase staining methods based on the avidin-biotin interaction. *Diagn Immunol.* 1984; 2(3):161-6.
3. Nagle RB, Clark VA, McDaniel KM, Davis JR. Immunohistochemical demonstration of keratins in human ovarian neoplasms. A comparison of methods. *J HistochemCytochem.* 1983 Aug; 31(8):1010-4.
4. Oros J, Matsushita S, Rodriguez JL, Rodriguez F, Fernandez A. Demonstration of rat CAR bacillus using a labelled streptavidin biotin (LSAB) method. *J Vet Med Sci.* 1996 Dec; 58(12):1219-21.
5. P Milde, J Merke, E Ritz, MR Haussler and EW Rauterberg. (1989) Immunohistochemical detection of 1,25-dihydroxyvitamin D3 receptors and estrogen receptors by monoclonal antibodies: comparison of four immunoperoxidase methods. *J Histochem-Cytochem* 37(11): 1609-1617.
6. ZR Shi, SH Itzkowitz, and YS Kim (1988) A comparison of three immunoperoxidase techniques for antigen detection in colorectal carcinoma tissues. *J. Histochem. Cytochem.* 36: 317-322.
7. J. A. Ramos-Vara (2005) Technical Aspects of Immunohistochemistry. *Vet Pathol* 42: 405-426 (2005).