



GLOBAL JOURNAL OF MEDICAL RESEARCH: H  
ORTHOPEDIC AND MUSCULOSKELETAL SYSTEM  
Volume 15 Issue 1 Version 1.0 Year 2015  
Type: Double Blind Peer Reviewed International Research Journal  
Publisher: Global Journals Inc. (USA)  
Online ISSN: 2249-4618 & Print ISSN: 0975-5888

## Tuberculosis of Zygapophyseal Joint: A Report of 3 Cases Observed in the University Hospital Center of Cocody in Abidjan (Côte d'Ivoire)

By Mohamed Diomandé, Ehaulier Soh Christian Louis Kouakou, Mariam Gbané-Koné, Baly Ouattara, Edmond Eti, Jean-Claude Daboiko & Marcel N'zué Kouakou

*University Hospital Center of Cocody (Abidjan Côte d'Ivoire), Cote DIvoire*

**Abstract-** The zygapophyseal joint is very rarely affected with mycobacterium tuberculosis.

We report three new observations of tuberculosis of zygapophyseal joint. It usually affects immunocompromised patients particularly by HIV. The clinical symptoms are not very different from spinal tuberculosis. Plain radiographies of the lumbar spine are not contributory. The radiographic diagnosis was achieved through CT scan and/or magnetic resonance imaging. The diagnosis was made in the first case by polymerase chain reaction and in the second case by identification of mycobacterium tuberculosis. In the latter case, the diagnosis was presumptive with satisfactory outcome on tuberculosis treatment.

Zygapophyseal arthritis is an unusual location of the bone and joint tuberculosis. The performance of an efficient imaging (CT scan and/or magnetic resonance imaging) is necessary in front of any inflammatory low back pain.

**Keywords:** bone and joint tuberculosis - zygapophyseal arthritis – CT scan-magnetic resonance imaging - abidjan.

**GJMR-H Classification:** NLMC Code: WE 253



*Strictly as per the compliance and regulations of:*



© 2015. Mohamed Diomandé, Ehaulier Soh Christian Louis Kouakou, Mariam Gbané-Koné, Baly Ouattara, Edmond Eti, Jean-Claude Daboiko & Marcel N'zué Kouakou. This is a research/review paper, distributed under the terms of the Creative Commons Attribution-Noncommercial 3.0 Unported License (<http://creativecommons.org/licenses/by-nc/3.0/>), permitting all non-commercial use, distribution, and reproduction in any medium, provided the original work is properly cited.

# Tuberculosis of Zygapophyseal Joint: A Report of 3 Cases Observed in the University Hospital Center of Cocody in Abidjan (Côte d'Ivoire)

Mohamed Diomandé <sup>α</sup>, Ehaulier Soh Christian Louis Kouakou <sup>σ</sup>, Mariam Gbané-Koné <sup>ρ</sup>, Baly Ouattara <sup>ω</sup>, Edmond Eti <sup>¥</sup>, Jean-Claude Daboiko <sup>§</sup> & Marcel N'zué Kouakou <sup>x</sup>

**Abstract-** The zygapophyseal joint is very rarely affected with mycobacterium tuberculosis.

We report three new observations of tuberculosis of zygapophyseal joint. It usually affects immunocompromised patients particularly by HIV. The clinical symptoms are not very different from spinal tuberculosis. Plain radiographies of the lumbar spine are not contributory. The radiographic diagnosis was achieved through CT scan and/or magnetic resonance imaging. The diagnosis was made in the first case by polymerase chain reaction and in the second case by identification of mycobacterium tuberculosis. In the latter case, the diagnosis was presumptive with satisfactory outcome on tuberculosis treatment.

Zygapophyseal arthritis is an unusual location of the bone and joint tuberculosis. The performance of an efficient imaging (CT scan and/or magnetic resonance imaging) is necessary in front of any inflammatory low back pain.

**Keywords:** bone and joint tuberculosis - zygapophyseal arthritis - CT scan-magnetic resonance imaging - abidjan.

## I. INTRODUCTION

Bone and joint tuberculosis (BJT) accounts for 30% of extra-pulmonary localizations and is dominated by the spinal localization (50 to 60% of cases) producing generally spondylodiscitis<sup>1</sup>. The involvement of the posterior elements of the vertebrae (pedicles, transverse processes, posterior articular processes, spinous processes, blades) is rare, accounting for 3% of all spinal tuberculosis particularly the zygapophysial joint (ZJ)<sup>2</sup>. The involvement of this joint is rather unknown, contrary to the spondylodiscitis. We report 3 new cases of zygapophyseal tuberculous arthritis observed in the rheumatology department of the University Hospital Center of Cocody emphasizing the clinical and biological characteristics and the contribution of high-performance imaging.

*Author α ρ ω ¥ χ : Department of rheumatology of University Hospital Center of Cocody (Abidjan Côte d'Ivoire).*

*e-mails: diomandemohamed48@yahoo.fr, mariamgbane05@yahoo.fr, baly\_ouattara@yahoo.fr, etiedmondoutlook@yahoo.fr, mnkouakou@yahoo.fr*

*Author σ § : Department of rheumatology of University Hospital Center of Bouaké (Côte d'Ivoire). e-mails: kchristianlouis@yahoo.fr, daboiko3jfc@yahoo.fr*

## II. CASES PRESENTATION

### a) Observation 1

A 46 year-old female patient, with no particular history, was admitted to our department for low back pain with sciatica poorly systematized after a misdiagnosis of 1 year. She was partially relieved by anti-inflammatory drugs. Two weeks before her hospitalization, her condition worsened by a walking disability. This clinical picture was developed into a context of vesperal fever, impairment of the general condition and night sweats. Clinical examination showed some painful points on palpation at the level of L4 and L5 vertebrae. There was no neuro-deficit sign. However tendon reflexes were brisk in the lower limbs. The tuberculin skin test (TST) was positive at 10 cm, the erythrocyte sedimentation rate (ESR) was 98 mm in the first hour, the C-reactive protein (CRP) was 285.5mg/l and the HIV serology was positive. Lumbar CT scan showed L4-L5 spondylodiscitis with soft tissue abscess and left zygapophyseal arthritis at the same stage (figure 1). The Polymerase Chain Reaction (PCR) performed on the abscess in search of mycobacterium tuberculosis was positive. The diagnosis of bifocal BJT was accepted. The patient was immobilized with a back brace. Antituberculous treatment combining Rifampicin-Isoniazid-Pyrazinamid-Ethambutol (RHZE) for 2 months following by 10 months of Rifampicin-Isoniazid (RH) allowed a favorable evolution marked by the healing of the patient.

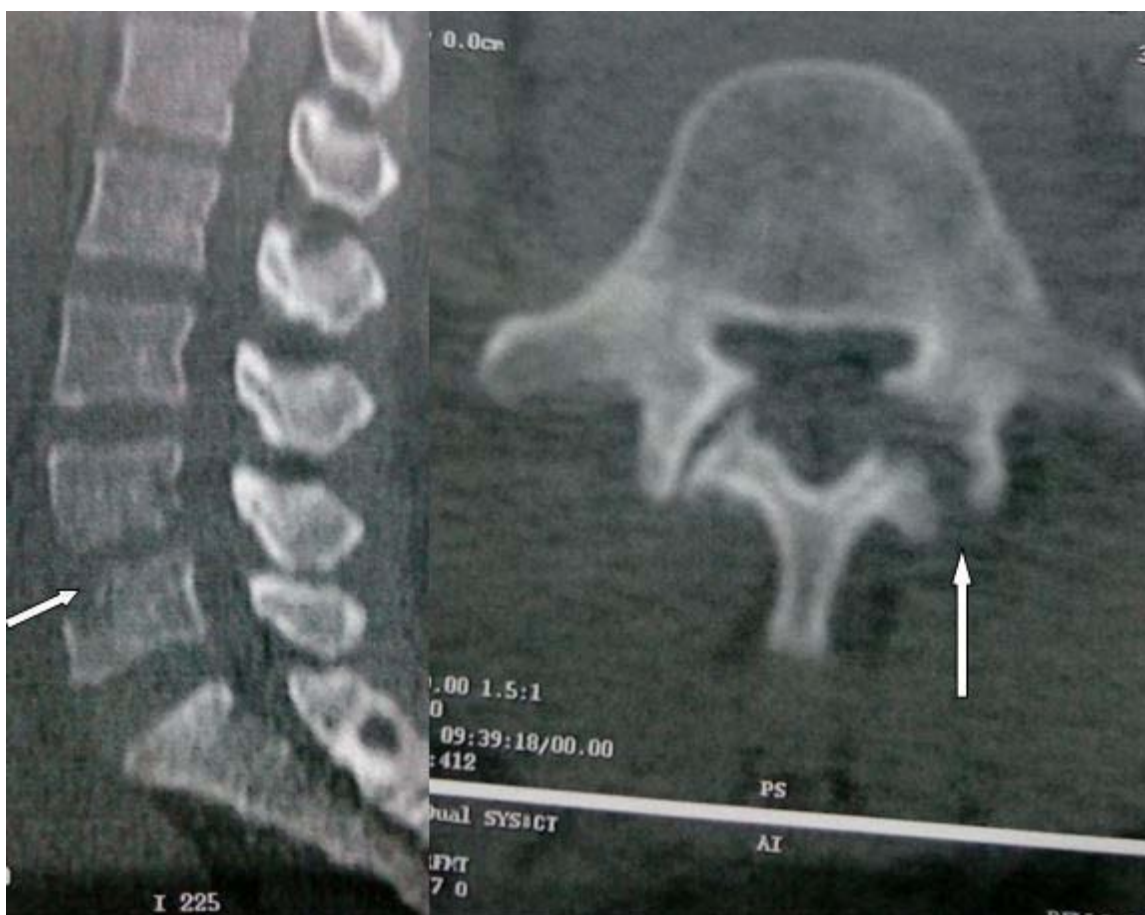

Figure 1 : Lumbar CT scan showed L4-L5 spondylodiscitis and left zygapophyseal arthritis at the same stage CT (patient 1)

b) Observation 2

A 56-year-old female patient with a chronic renal failure was admitted for chronic bilateral low back pain with sciatica poorly systematized that developed gradually and became inflammatory about 45 days before hospitalization. She also had a productive cough with whitish sputum. To this symptomatology, was associated a state of agitation with incoherent remarks with no notion of headache. This clinical picture was developed into a context of vesperal fever and impaired general condition. On physical examination, we noted a fever of  $38^{\circ}1$  C, a lumbar spinal syndrome characterized by lumbar spinal stiffness much greater on extension, a positive bell test and a positive bilateral Lasègue's sign, at  $30^{\circ}$ . We did not observe any sign of neurological deficit. Pulmonary examination allowed to note the presence of crackles. The TST revealed anergia, ESR was 60 mm, CRP 24 mg/l and the HIV serology was positive. Acid-and alcohol fast bacilli were identified in the sputum. Cerebral CT scan was normal as well as the electroencephalogram. Analysis of cerebrospinal fluid showed cytology with 3 elements without any identified germ. Lumbar CT scan showed zygapophyseal arthritis from L4-L5 and L5-S1 without spondylodiscitis associated (figure 2). The diagnosis of pulmonary

tuberculosis and zygapophysial tuberculous arthritis was accepted. The healing was achieved after 12 months of antituberculous treatment (2 months of RHZE and 10 months of RH) associated with immobilization by a back brace.

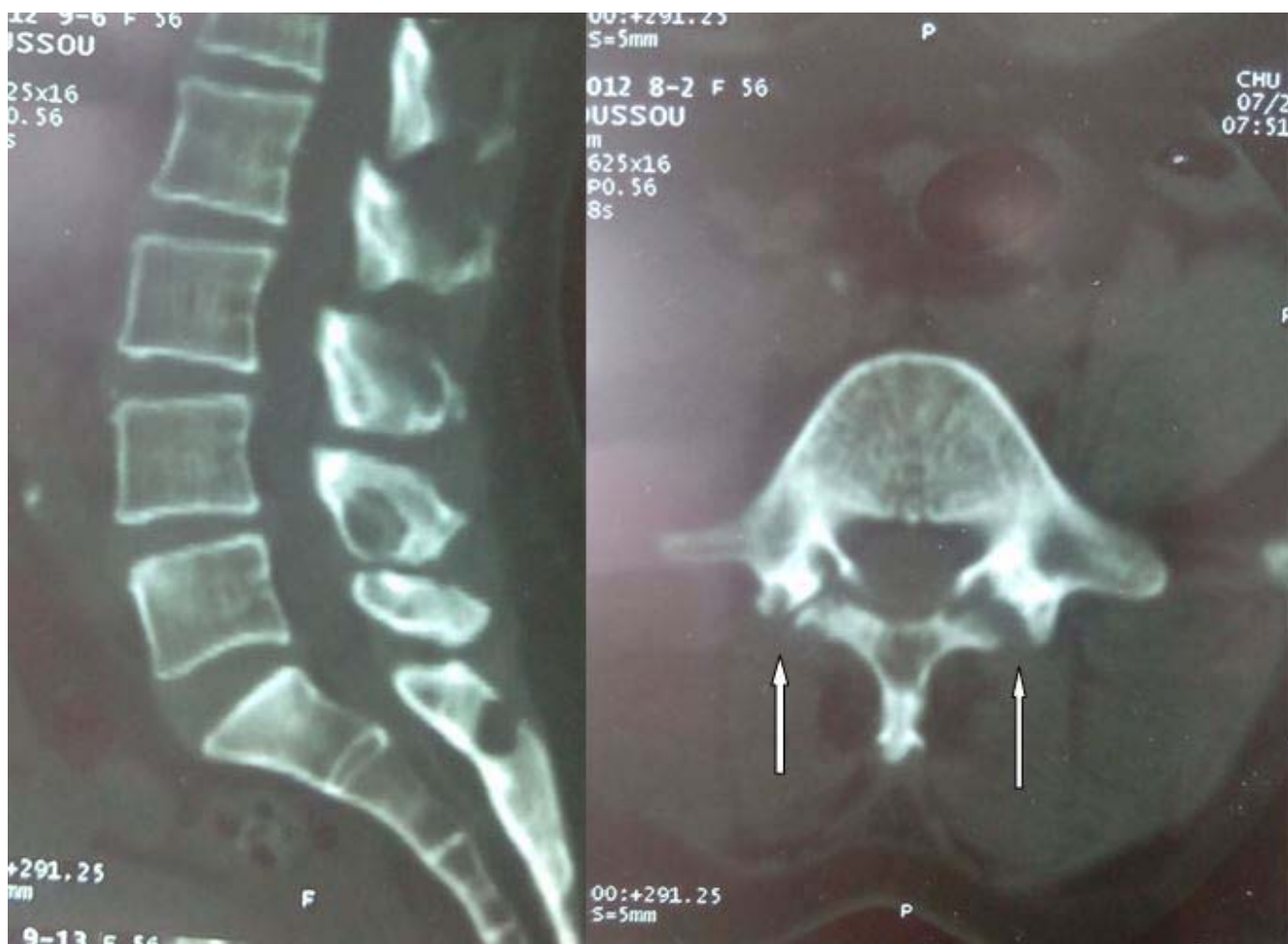
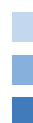
Figure 2 : Lumbar CT scan showed bilateral zygapophyseal arthritis from L4-L5 and L5-S1 without spondylodiscitis (patient 2)

c) Observation 3

A 47-year-old female patient, with type 2 diabetes and with hypertrophic cardiomyopathy was hospitalized for low back pain and poorly systematized sciatica that developed chronically and became hyperalgesic about 1 month before hospitalization, causing difficulty in walking. She presented no visceral sign and this symptomatology was developed in a context of intermittent fever with a weight loss of 10 kg in 6 months. Clinical examination revealed a lumbar spinal syndrome with painful points at lumbar spine, a limitation of spinal movements with impossibility of extending the lumbar spine and a Schöber index at 10+2, a radicular syndrome with positive Lasègue's sign at 10°. The TST was negative as well as the HIV serology. ESR and CRP were respectively 90 mm and 41.64 mg/l. Lumbar CT scan revealed an intraductal hypodensity at the L3-L4 stage requiring the performance of a lumbar MRI which brought out a multi-stage zygapophyseal arthritis from L2 to S1 associated with epiduritis (figure 3). The evolution was favorable with immobilization with a back brace and after one year

of antituberculous treatment (2 months of RHZE and 10 months of RH).



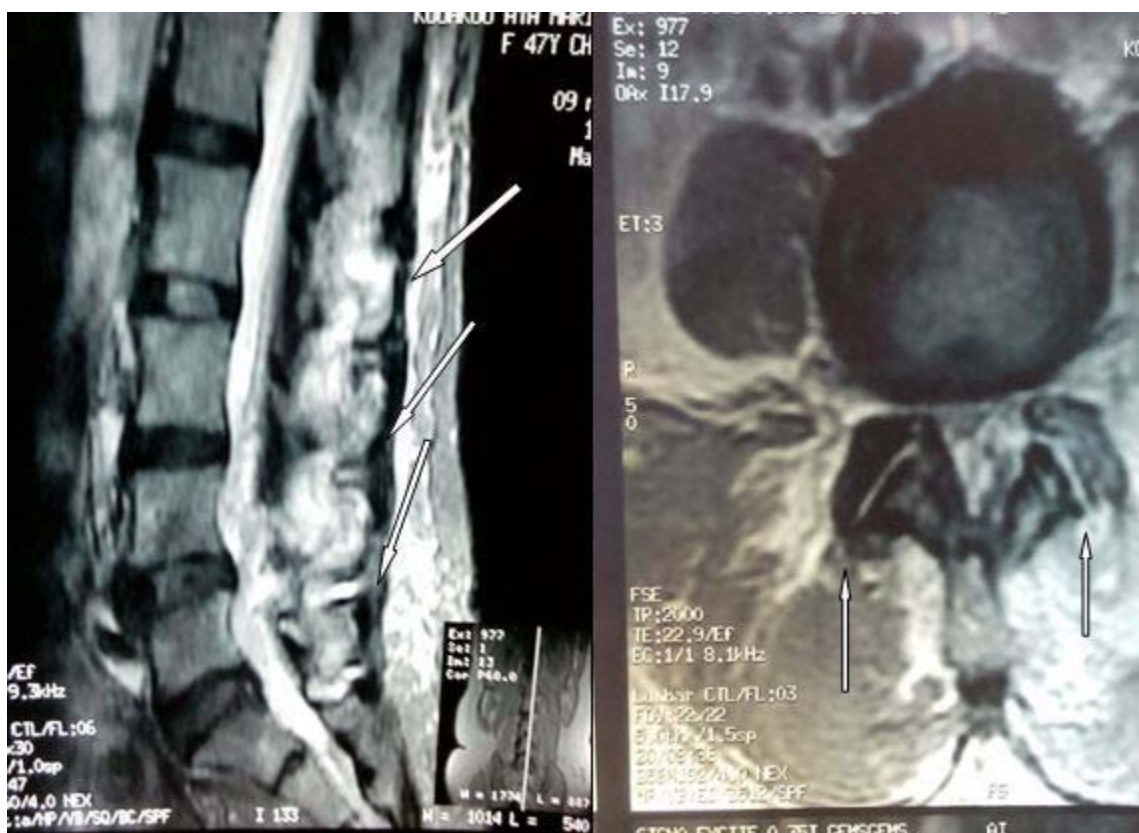


Figure 3 : MRI of the lumbar spine showing in T2 sequence with fat suppression, a hyperintensity signal, next to zygapophyseal joints from L2 to S1 associated with taking contrast of zygapophyseal joint L3-L4, most seen in the left joint

### III. DISCUSSION

The ZJ is rarely affected by mycobacterium tuberculosis<sup>3,4</sup> judging by the very limited number of cases reported in the literature unlike Pott's disease. The prevalence of zygapophyseal tuberculous arthritis would be 1.76% according to the series of Narlawar et al<sup>2</sup>. Almost the majority of cases of zygapophyseal arthritis described was due to ordinary germs<sup>5,6</sup>. The involvement of the ZJ is best explained by the venous dissemination from anastomoses with the venous plexus on the surface of the posterior articular processes contrary to spondylodiscitis where the dissemination is achieved by arterial way<sup>7</sup>.

As in any tuberculosis, a predisposing factor is always present particularly HIV immunosuppression. In our case, patient 1 was HIV positive, patient 2 was HIV positive with chronic renal failure and patient 3 was diabetic. The diagnosis of zygapophyseal tuberculous arthritis is often delayed as it was the case in our 3 cases (6.5 months on average). This delay was due on the one hand by the fact that plain radiographies, always requested in first line cannot identify lesions of the ZJ because of the superposition of anatomical elements of the posterior arch and on the other hand the duration of misdiagnosis contributes to the installation of bone destructions as well as the increase in the risk of

neurological deficit<sup>4</sup>. The clinical symptoms were not significantly different than Pott's disease. We'll find spinal pains rather inflammatory with spinal stiffness much more pronounced on extension of the spine associated with painful point at the injury site. Neurological deficit complications are often associated<sup>4,8,9</sup> contrary to our 3 cases. A biological inflammatory syndrome is usually present as well as the positivity of TST. Acid-and alcohol-fast bacilli can be identified after sampling in case of soft tissue abscess where we can bring out a tuberculous follicle after biopsy of ZJ at the affected site. As regards imaging, plain radiography lacks sensitivity and cannot reveal diagnosis in most cases and imposes CT scan and /or MRI. CT scan is better to identify bone lesions particularly osteolysis or erosions of the edges of the joints like the case in 2 of our observations (patient 1 and 2). Even better than CT scan, MRI seems to be the test of choice to identify anomalies of the ZJ and the surrounding soft tissues (abscess, epiduritis) and makes early diagnosis<sup>2</sup>. Typically, it brings out bone inflammation as T1 hypointensity signal, T2 hyperintensity signal and T2-STIR hyperintensity signal (fat removal), or shows a hypointensity signal in T1-weighting of capsular ligamentous structures which enhance after gadolinium injection and T2 hyperintensity signal. It has great value in assessing neurological

damages<sup>2</sup>. In our cases, only patient 3 realized MRI after that CT scan could not identify the osteoarticular lesions. Definitive diagnosis was made in 2 out of 3 cases by bacteriology particularly by PCR (patient 1). PCR, recent technique with a specificity of 92-98%, rather unknown in sub-Saharan Africa, deserves to be promoted<sup>10</sup>. It allows rapid diagnosis and is a diagnostic alternative since biopsy of ZJ is difficult to perform, in our context because of the inadequacy of the technical platform. As for surgical biopsy, it is very expensive for the majority of our patients who do not have health insurance coverage. In the last case (patient 3), the epidemiological, clinical, biological and especially therapeutic and evolutionary arguments have prevailed in accordance with the work of Eti et al<sup>11</sup>.

Therapeutically, this antituberculous protocol that consisted of 2 months of RHZE following by 10 months of RH, widely practiced in sub-Saharan Africa gave satisfactory results that ended in the recovery of patients after 12 months of treatment.

#### IV. CONCLUSION

Tuberculosis affects exceptionally ZJ. Clinically, it is not significantly different from Pott's disease. PCR is a recent technique which can help us to do definitive diagnosis, deserves to be promoted<sup>10</sup>. CT scan and / or MRI are imaging of choice.

*Conflict of Interest: None*

#### REFERENCES RÉFÉRENCES REFERENCIAS

1. Zamiaty W, EL Quessar A, Jiddane M, El Hassani MR, Chakir N, Boukhrissi N. Tuberculous osteitis of the posterior vertebral arch: case report. J Neuroradiol 1999; 26 (1): 21-6.
2. Narlawar RS, Shah JR, Pimple MK, Patkar DP, Patankar T, Castillo M. Isolated tuberculosis of posterior elements of spine: magnetic resonance imaging findings in 33 patients. Spine 2002; 27: 275-81.
3. Tuli SM. Tuberculosis of the spine. In: Tuli SM, editor. Tuberculosis of the skeletal system (bones, joints, spine and bursal sheaths). 3rd ed. New Delhi: Jaypee Brothers Medical Publishers (P) Ltd.; 2004. p 191-343.
4. Babhulkar SS, Tayade WB, Babhulkar SK. Atypical spinal tuberculosis. J Bone Joint Surg Br. 1984; 66 (2): 239-42.
5. Derouet N, Haettich B, Temmar Z, Dugard D, Puechal X. Septic arthritis of a lumbar facet joint. A case report. Ann Med Interne 2001; 152: 279-82.
6. Michel-Batôt C, Dintinger H, Blum A, Olivier P, Fyriel Laborde F, Bettembourg-Brault I and al. A particular form of septic arthritis: Septic arthritis of facet joint. Rev Rhum 2008; 75: 82-6.
7. Tuli SM. Tuberculosis of the spine. In: Tuli SM, editor. Tuberculosis of the skeletal system. 2nd ed. New Delhi, India: Jaypee Brothers Medical, 1997:177-311.
8. Naim-Ur-Rahman AJ, Jamjoom A, Jamjoom ZA, Al-Tahan AM. Neural arch tuberculosis: radiological features and their correlation with surgical findings. Br J Neurosurg 1997; 11 (1): 32-8.
9. Mehta JS, Bhojraj SY. Tuberculosis of the thoracic spine. A classification based on the selection of surgical strategies. J Bone Joint Surg Br. 2001; 83 (6): 859-63.
10. Pertuiset E. Peripheral bone and joint tuberculosis. EMC-Rheumatology Orthopedic 2004; 1: 463-86.
11. Eti E, Daboiko JC, Brou KF, Ouali B, Koffi KD, Kouakou NM. Vertebral tuberculosis: our experience from a study of 147 cases in the rheumatology department of the university hospital of Cocody, Abidjan, Ivory Coast. Med Afr noire 2010; 57 (5): 287-92.