



GLOBAL JOURNAL OF MEDICAL RESEARCH: A
NEUROLOGY AND NERVOUS SYSTEM
Volume 15 Issue 1 Version 1.0 Year 2015
Type: Double Blind Peer Reviewed International Research Journal
Publisher: Global Journals Inc. (USA)
Online ISSN: 2249-4618 & Print ISSN: 0975-5888

Treatment Preferences and Prognosis of Acute Traumatic Brain Injury; Outcomes in the Patients Who Were on Antiplatelet Therapy

By Hasan Emre Aydin, Zuhtu Ozbek, Emre Ozkara, Emre Delen,
Murat Vural, AliArslantas & Metin Ant Atasoy

University of Yunus EMRE State Hospital, Turkey

Introduction- Antiplatelet therapy comprises a group of drugs used in the treatment of valvular heart disease, cardiac stents, rhythm disorders, pulmonary embolism and cerebrovascular diseases (1). The patients followed-up by regular measurement of the haemostatic parameters usually miss their follow-up visits due to the social reasons and are exposed to uncontrolled side effects of these drugs. The people admitting for the side effects of anticoagulant therapy are commonly seen in the emergency department because of the increased use of this group of drugs (2,3).

GJMR-A Classification : NLMC Code: WE 706



Strictly as per the compliance and regulations of:



Treatment Preferences and Prognosis of Acute Traumatic Brain Injury; Outcomes in the Patients Who Were on Antiplatelet Therapy

Hasan Emre Aydin ^α, Zuhtu Ozbek ^σ, Emre Ozkara ^ρ, Emre Delen ^ω, Murat Vural [¥], Ali Arslantas [§]
& Metin Ant Atasoy ^χ

I. INTRODUCTION

Antiplatelet therapy comprises a group of drugs used in the treatment of valvular heart disease, cardiac stents, rhythm disorders, pulmonary embolism and cerebrovascular diseases (1). The patients followed-up by regular measurement of the haemostatic parameters usually miss their follow-up visits due to the social reasons and are exposed to uncontrolled side effects of these drugs. The people admitting for the side effects of anticoagulant therapy are commonly seen in the emergency department because of the increased use of this group of drugs (2,3). Bleeding is the most common side effect of oral anticoagulants. Although the majority of the cases of intracerebral hemorrhage diagnosed in the emergency department are the spontaneous intracerebral hematomas, the patients who were using anticoagulants with regular follow-up visits and admitted to the emergency department following the trauma also constitute a great proportion of these cases. It is well-known that even a mild trauma may have serious consequences in people under anticoagulant therapy. Furthermore, the mortality rate is high in people aged over 65 years who had admitted to the emergency department with head trauma despite not using the anticoagulants (4). Traumatic intracerebral hemorrhage are seen as intraparenchymal, subdural or epidural hematoma (5,6,7,22).

II. MATERIALS AND METHODS

This study included 17 patients with head trauma and using antiplatelet therapy and who admitted to the neurosurgery clinic at Eskisehir Osmangazi University between the years 2007 and 2012. The

comorbidities, indications for oral anticoagulant use, initial INR value (measured by the clot based method) and CT findings of the patients were evaluated retrospectively. The patients were classified as having mild or severe head trauma depending on the neurological symptoms and radiological findings at the time of admission.

The patients with a Glasgow Coma Scale score of 13 and over and having no pathological condition that requires surgery were considered as having mild head trauma. The first group of patients were those who had no pathological condition requiring surgery according to the computed tomography (CT) findings at the time of admission (mild head trauma) but in whom surgical treatment required during the follow-up in intensive care unit because of the increasing intracerebral hemorrhage despite the discontinuation of anticoagulant therapy. The second group included the patients who had a pathological condition requiring surgery at the time of admission (severe head trauma) and in whom hemostatic parameters deteriorated due to the use of anticoagulants. This last group of patients was evaluated by hematology and cardiology departments and hemostatic parameters were immediately brought to normal according to the recommendations. Third group of patients were those who did not require surgery at the time of admission (mild head trauma) but in whom hemostatic parameters deteriorated. The patients followed up in the intensive care unit received medical treatment according to the recommendations of departments relevant to their diseases requiring anticoagulants and spontaneous resorption of hematoma has been observed in a controlled manner (Table 1).

Table 1 : Patient groups

	GKS	INR	Medical Treatment	Surgery
Group I	over 13	over 3	Yes	yes
Group II	8-13	over 3	Yes	yes
Group III	over 13	3 and lower	Yes	no

statistical analysis. $P < 0.05$ was considered as statistically significant.

III. STATICAL RESULTS

Of the 17 patients included to the study, 7 were female and 10 were male. The mean age of the patients was 60 years (range 35-84 years), with 10 % of them were over the age of 65 years. Mortality rate was significantly higher in patients over 65 years of age ($p < 0.05$). On the other hand, there was no significant relationship between the gender and mortality. All the patients were using 10 mg warfarin as the oral anticoagulant and the indication for warfarin use were cardiac valve replacement (29,4%), atrial fibrillation (17,6

% or vascular thrombosis (52,9 %). In parallel with our findings, the most common indications for the use of warfarin have been reported in the literature to be vascular thrombosis and heart valve disease (4,8). Warfarin treatment has been discontinued in all patients at the time of admission.

The need for emergency surgery and mortality rate were found to be significantly higher among the patients with an INR value of 3 or more at admission ($p < 0.05$) (Table 2). Moreover, in accordance with severe head trauma, GCS score at admission was significantly lower in patients with an INR value of 3 or more ($p < 0.05$) (Table 3).

Table 2 : Relationship between INR levels and mortality

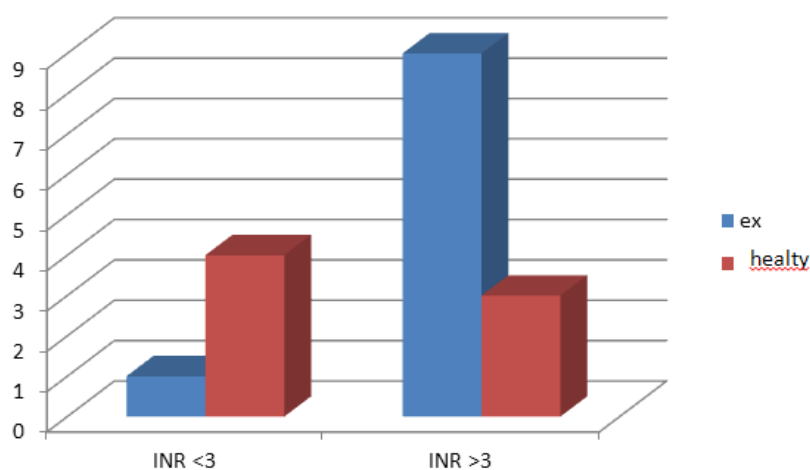
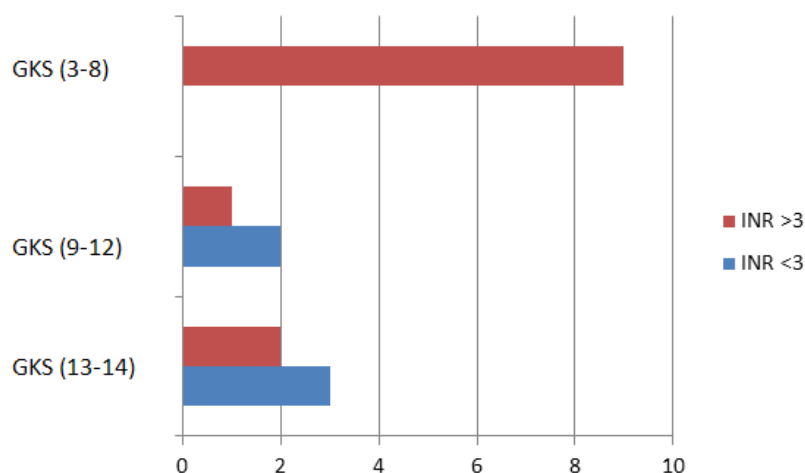


Table 3 : Relationship between GKS and INR in admission



The CT imaging was performed in all patients who were on anticoagulant therapy before the head trauma. According to the CT images, surgery was required in 14 patients and was not in 3 patients. Of the patients, 11,8 % were diagnosed as epidural hematoma,

52,9 % as subdural hematoma and 35,3 % as intraparenchymal hematoma.

All patients requiring surgery were treated with vitamin K and FFP (fresh frozen plasma) replacement was performed prior to surgery. INR value was maintained in normal limits.

IV. DISCUSSION

The most severe side effect of the antiplatelet drugs with the highest mortality rate is intracerebral hemorrhage. Simple traumatic head injuries should be even considered as important in this group of patients and the headache, nausea, vomiting, or progressive neurologic deficits following the trauma should suggest intracerebral hemorrhage (8). The findings may not occur immediately after the trauma. Clinical and radiological findings of ongoing active bleeding become evident in the first 24 hours with the increasing intracerebral hemorrhage (9).

Although the mechanism of post-traumatic intracerebral hemorrhage in patients on antiplatelet therapy is not clear, the inhibition of repair mechanisms against the damage to the vessel wall caused by a minor trauma may be responsible from the post-traumatic intracerebral hemorrhage in patients using warfarin (9). It may also be explained by the fact that the wound healing in the cerebral tissue begins in 3-4 days after the surgical procedure and with gliosis characterized by astrocyte proliferation and glial fibrillary acidic protein production. The risk of bleeding increases with the deterioration of the balance between clot formation and lysis due to the anticoagulant therapy (10).

The most important prognostic factors in these patients include INR value at the time of admission and duration of warfarin usage, which may affect the mortality and hematoma progression (11,12). The INR (International normalized ratio) value is calculated by dividing the patient's prothrombin time (PT) to the laboratory's mean PT value for normal patients. INR is not expressed in any units and ranges between 0.9 and 1.1 in normal population. The mortality rate is higher than 60% in patients with an INR value of 3 or over at the time of admission (13,14). The most common cause of uncontrolled increases in INR value is the lack of regular follow-up visits. The other important prognostic factors on CT imaging are the initial hematoma volume and shift effect.

Chronic use of anticoagulant drugs comprises 5% of the overall drug usage (15). The incidence of bleeding as a complication of oral anticoagulant usage has been reported to range from 0.8 to 3.5% (16). Previous studies have demonstrated that 6-24% of intracerebral hemorrhages results from using antiplatelet therapy. A considerable proportion of the patients are known to use the antiplatelet therapy for prophylaxis. It should be noted that prophylactic use of these drugs in patients with no absolute indications may lead to serious consequences.

The first to do in the management of this group of patients is immediately discontinuation of antiplatelet therapy and to restore the hemostatic parameters to normal limits. Fresh frozen plasma (FFP), vitamin K,

prothrombin concentrate and recombinant factor VIIa can be used in order to normalize the hemostatic values, particularly in the cases requiring emergency surgery. Despite the studies carried out on this issue, there is an inconsistency about the discontinuation of antiplatelet treatment. The treatment can be restarted following the surgery if there is an absolute indication for anticoagulation and there are no acceptable alternative treatments (17).

Although heparin and low molecular weight heparin used in the case of heart valve replacement and for preventing thromboembolic complications due to the discontinuation of anticoagulants have been suggested to cause no increase in the amount of intracerebral hemorrhage, there are a few cases of heparin-induced intracerebral hemorrhage reported in the literature (18,19). Moreover, in an experimental study on restarting antiplatelet therapy following the surgery, it has been suggested that it will be safe to restart the treatment in post-surgery 10-14 days (10,23). The controlled restarting of the antiplatelet therapy within a short time after the surgery reduces the mortality due to the chronic disease.

The most commonly used oral anticoagulant is the warfarin. The warfarin has a half-life of 36 hours and inhibits the vitamin K-dependent clotting factors (II, VII, IX, X) and vitamin K-dependent coagulation inhibitors (1). Because the drug is metabolized in the liver and interacts with many other drugs due to the polymorphism of cytochrome P450 enzyme system, physicians should be cautious in drug alterations and concomitant drug usage (4). The drug is used in patients with atrial fibrillation, venous thrombosis, acute myocardial infarction and mechanical heart valve disease. The effectiveness of the drug is followed by INR value, which is recommended to be maintained between 2 and 3 for therapeutic effectiveness. However, it is recommended to be between 2.5 and 3.5 in patients with mechanical heart valve disease. The risk of bleeding is 7-10 times higher in patients with an INR value of 3 or more (3). The standard treatment in warfarin-induced bleeding disorder is FFP and vitamin K. Following the replacement therapy, the improvement rate in INR is about 0.18 INR/hour (20). Rapid replacement should be avoided unless it is necessary, because of resulting pulmonary edema or increased cerebral pressure. Dabigatran (Pradaxa), the recent and not widely used oral anticoagulant, directly inhibits the factor Xa and has major advantages of not requiring INR monitoring and causing fewer drug interactions than warfarin (12,21). In a clinical study, although dabigatran has been found to significantly prevent the development of stroke, no difference has been found between dabigatran and warfarin in terms of causing intracerebral hemorrhage (11).

In recent years, the number of patients admitting to the emergency department with traumatic



or spontaneous intracerebral hemorrhage increased with the advanced age and increasing use of oral anticoagulants for chronic diseases. Of the 65 years old or over patients admitted to the emergency department, 73% has been found to have concomitant diseases (6). The coagulopathy-induced complications with high mortality may develop in patients with chronic diseases requiring anticoagulant use (7). Of the elderly patients with head injury, 9% has been found to be using anticoagulation prior to the trauma (8). The use of anticoagulant medication prior to the trauma is known to increase the post-traumatic intracerebral hemorrhage (3,5,10).

V. CONCLUSION

In this study, warfarin-induced intracerebral hemorrhage was found to be correlated with high INR value, neurological status (low degrees of GKS) and radiological findings at the time of admission. Because of the insidious increase in the risk of bleeding, close neurological follow-up should be performed and FFP and vitamin K replacement with the appropriate time intervals is necessary in patients requiring no emergency surgery. Therefore, a multidisciplinary approach is necessary in these patients, with the support of cardiology and hematology departments.

Çubuk EC, Karakurt T. Surgical management of chest wall tuberculosis. *J Cutan Med Surg* 2009;13(1):33-9.

REFERENCES RÉFÉRENCES REFERENCIAS

1. Eruyar E, Guney F. Prognosis In Anticoagulant Therapy Related Intracerebral Hemorrhage. *Turk J Cerebrovasc D* 2011;17(3):101-104.
2. Beynon C, Hertle Dn, Unterberg Aw, Sakowitz Ow. Clinical Review: Traumatic Brain Injury In Patients Received Antiplatelet Medication. *Crit Care* 2012;16(4): 228.
3. Visser Le, Bleumink Gs, Trienekens Ph, Vulto Ag, Hofman A, Et Al. The Risk Of Overanticoagulation In Patients With Heart Failure On Coumarin Anticoagulants. *Br J Haematol* 2004;127: 85-89.
4. Thompson Hj, McCormick Wc, Kagan Sh. Traumatic Brain Injury In Older Adults: Epidemiology, Outcomes, And Future Implications. *J Am Geriatr Soc* 2006;54(10):1590-5
5. Franke Cl, De Jonge J, Wieten Jc, Coul Aww, Gijn J. Intracerebral Hematomas During Anticoagulant Treatment. *Stroke* 2009;21:726-730.
6. Zuckerman Sl, Morgan Cd, Burks S, Forbes Ja, Chambless Lb, Et Al. Functional And Structural Traumatic Brain Injury In Equestrian Sports: A Review Of The Literature. *World Neurosurg* 2014;Doi: 10.1016/J.Wneu.
7. Shen X, Dutcher Sk, Palmer J, Liu X, Kiptanui Z, Et Al. A Systematic Review Of The Benefits And Risks Of Anticoagulation Following Traumatic Brain Injury. *J Head Trauma Rehabil* 2014;(Epub Ahead Of Print)
8. Bommer Wj. Current And Future Alternatives To Warfarin For The Prevention Of Stroke In Atrial Fibrillation. *Crit Pathw Cardiol* 2012;11(2): 45-54.
9. Le Roux P, Pollack Cv, Milan M, Schaefer A. Race Against The Clock: Overcoming Challenges In The Management Of Anticoagulant Associated Intracerebral Hemorrhage. *J Neurosurg* 2014;121 Suppl:1-20.
10. Sorensen B, Asvaldsdottir Hs, Gudmundsdottir Br, Onundarson Pt. The Combination Of Recombinant Factor Viia And Fibrinogen Correct Clotting Ex Vivo In Patient Samples Obtained Following Cardiopulmonary Bypass Surgery. *Thromb Res* 2009;124(6): 695-700.
11. Anderson Cs. Medical Management Of Acute Intracerebral Hemorrhage. *Curr Opin Crit Care* 2009;15(2): 93-8.
12. Pfeilschifter W, Spitzer D, Czech-Zechmeister B, Steinmetz H, Foerch C. Increased Risk Of Hemorrhagic Transformation In Ischemic Stroke Occurring During Warfarin Anticoagulation: An Experimental Study In Mice. *Stroke* 2011;42(4):1116-21.
13. Siegmund Hu, Burghaus R, Kubitz D, Coboecken K. Contribution Of Rivaroxaban To The International Normalized Ratio When Switching To Warfarin For Anticoagulation As Determined By Simulation Studies. *Br J Clin Pharmacol* 2014;Doi: 10.1111/Bcp.12571.
14. Aldemir A, Avsar F, Comoglu S. A Case Of Warfarin Associated Intracerebral Hemorrhage With Delayed Presentation Of Radiological Findings. *Turk J Cerebrovasc D* 2011;17(3): 107-110.
15. Hart Rg, Boop Bs, Anderson Dc. Oral Anticoagulants And Intracranial Hemorrhage: Facts And Hypotheses. *Stroke* 1995;26:1471-7.
16. Lavoie A, Ratte S, Clas D, Demers J, Moore L, Et Al. Preinjury Warfarin Use Among Elderly Patients With Closed Head Injuries In A Trauma Center. *J Trauma* 2004;56(4): 802-7.
17. Eroglu M, Ozturk U, Yuceturk Cn, Ciftci M, Murat S, Et Al. The Relationship Between Inr Level And Microscopic Hematuria In Anticoagulant Patients. *Turk Urology J* 2005;31(4):574-9.
18. Duncan Jm, Cooley Da, Reul Gj, Ott Da, Hallman Gl, Et Al. Durability And Low Thrombogenicity Of The St. Jude Medical Valve At 5 Year Follow Up. *Ann Thorac Surg* 1986;42: 500-5.
19. Parra Mw, Zucker L, Johnson Es, Gullett D, Avila C, Et Al. Dabigatran Bleed Risk With Closed Head Injuries: Are We Prepared? *J Neurosurg* 2013;119(3): 760-5.
20. Diamod T, Gray Wj, Chee Cp, Fannin Tf. Subdural Hematoma Associated With Long Term Oral Anticoagulation. *Br J Neurosurg* 1988;2: 351-6.

21. Wassef Sn, Abel Tj, Grossbach A, Viljoen Sv, Jackson Aw, Et Al. Traumatic Intracranial Hemorrhage In Patients Taking Dabigatran: Report Of 3 Cases And Review Of The Literature. J Neurosurg 2013;73(2): 363-78.
22. Rutland-Brown W, Langlois Ja, Thomas Ke, Xi Yl. Incidence Of Traumatic Brain Injury In The United States, 2003. J Head Trauma Rehabil 2006;21(6): 544-8.
23. Yilmaz M, Demirci S. The Factors Affecting Mortality In Patients With Intracerebral Hemorrhage. J Clin Exp Invest 2011;2(4): 404-7.



GLOBAL JOURNALS INC. (US) GUIDELINES HANDBOOK 2015

WWW.GLOBALJOURNALS.ORG