



GLOBAL JOURNAL OF MEDICAL RESEARCH: H
ORTHOPEDIC AND MUSCULOSKELETAL SYSTEM
Volume 16 Issue 1 Version 1.0 Year 2016
Type: Double Blind Peer Reviewed International Research Journal
Publisher: Global Journals Inc. (USA)
Online ISSN: 2249-4618 & Print ISSN: 0975-5888

Antibiotic-Loaded Resorbable Bone-Graft Substitute: A New Treatment

By Dr. Med. Bernd Gächter, Dr. Med. Jennifer Frieda Angehrn, Dr. Med. Stephane Schlunke,
Prof. Dr. Sebastian Probst & Dr. Med. Paul Biegger

Introduction- Patients with osteomyelitis of the long bones need a surgical debridement with a long-term antibiotic therapy. This is always a great challenge. This patient group has usually a long hospitalization period, high therapy costs and a great risk of a recurrence. Patients often interrupt independently the long-term antibiotic therapy because of side effects. Patients with osteomyelitis do have many multiple comorbidities like diabetes mellitus or arthropathy which doesn't favor the healing process of the wound. The immune system of this patient group is often compromised due to cortisone treatment or an infectious disease. Some of these patients live at the margins of our society with addiction and psychiatric illnesses. Additionally experiences demonstrate that this patient population usually show a very poor compliance.

A simple treatment concept is needed that can be carried out even in patients with poor reliability.

This case report will demonstrate that even after two surgical treatments the healing of the wound was not accomplished. But using the treatment with antibiotic-loaded resorbable bone-graft substitute the healing was successful.

GJMR-H Classification: NLMC Code: WE 168



Strictly as per the compliance and regulations of:



© 2016. Dr. Med. Bernd Gächter, Dr. Med. Jennifer Frieda Angehrn, Dr. Med. Stephane Schlunke, Prof. Dr. Sebastian Probst & Dr. Med. Paul Biegger. This is a research/review paper, distributed under the terms of the Creative Commons Attribution-Noncommercial 3.0 Unported License (<http://creativecommons.org/licenses/by-nc/3.0/>), permitting all non-commercial use, distribution, and reproduction in any medium, provided the original work is properly cited.

Antibiotic-Loaded Resorbable Bone-Graft Substitute: A New Treatment

Case Report

Dr. Med. Bernd Gächter ^α, Dr. Med. Jennifer Frieda Angehrn ^σ, Dr. Med. Stephane Schlunke ^ρ
 Prof. Dr. Sebastian Probst ^ω & Dr. Med. Paul Biegger [¥]

I. INTRODUCTION

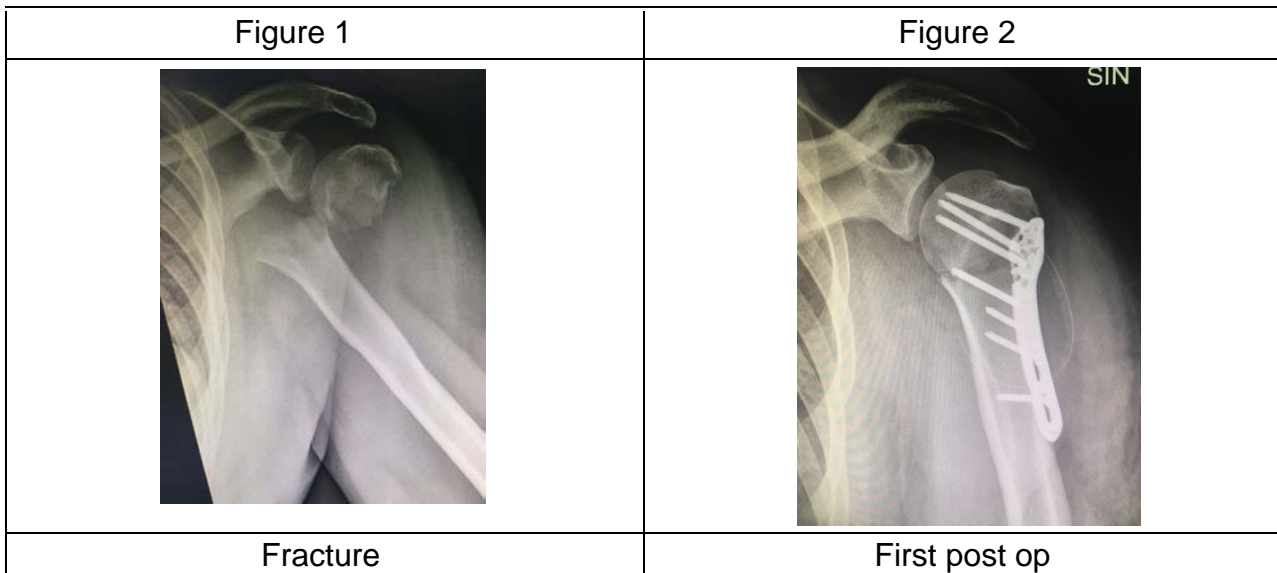
Patients with osteomyelitis of the long bones need a surgical debridement with a long-term antibiotic therapy. This is always a great challenge. This patient group has usually a long hospitalization period, high therapy costs and a great risk of a recurrence. Patients often interrupt independently the long-term antibiotic therapy because of side effects. Patients with osteomyelitis do have many multiple comorbidities like diabetes mellitus or arthropathy which doesn't favor the healing process of the wound. The immune system of this patient group is often compromised due to cortisone treatment or an infectious disease. Some of these patients live at the margins of our society with addiction and psychiatric illnesses. Additionally experiences demonstrate that this patient population usually show a very poor compliance.

A simple treatment concept is needed that can be carried out even in patients with poor reliability.

This case report will demonstrate that even after two surgical treatments the healing of the wound was not accomplished. But using the treatment with antibiotic-loaded resorbable bone-graft substitute the healing was successful. The affected bone was resected, the remaining bone was drilled and the antibiotic-loaded bone-graft was filled up. In this way a high dose of local antibiotics could act in the remaining bone for weeks. After a couple of months the resorbable bone-graft cannot be detected by means of radiography.

II. CASE PRESENTATION

An unemployed 44-year-old man with a history of alcohol and drug abuse and a bipolar disorder which has been assigned to a guardian. He presented himself in our clinic with a proximal fracture of his left humeral shaft after a fall (Figure 1).



Author ^α: FMH Surgery, Consultant in Wound Care, Ospedale Regionale di Locarno, Via all'Ospedale 1, 6600 Locarno, Switzerland.

e-mail: b.gaechter-angehrn@bluewin.ch

Author ^σ: FMH Practical Doctor, Ospedale Regionale di Locarno, Via all'Ospedale 1, 6600 Locarno, Switzerland.

Author ^ρ: FMH General and Trauma Surgery, Vascular Surgery, Clinica Luganese Moncucco, Via Moncucco 10, 6900 Lugano.



Author ^ω: DClinPrac, RN, Professor in Wound Care, University of Applied Sciences Western Switzerland, 47 Avenue Champel, 1206 Geneva, Switzerland.

Author [¥]: FMH General and Trauma Surgery, FMH Surgery visceral, Consultant, Ospedale Regionale di Locarno, Via all'Ospedale 1, 6600 Locarno, Switzerland.




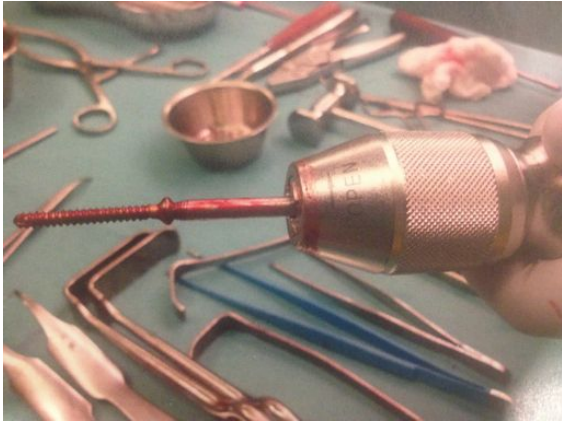
A couple of weeks after the osteosynthesis (Figure 2) patient returns to our emergency room with a dislocation of the plate after an other fall (Figure 3). The

patient was operated again with the introduction of a new proximal plate (Figure 4). The next six months proceeded uneventful.

Figure 3	Figure 4
	
Dislocation	Second post op

After this period the patient presented himself again in our wound service with a purulent wound of his



left arm that reached deep down up to the osteosynthetic plate (Figure 5).

Figure 5	Figure 6
	
Purulent wound	Removal of osteosynthesis material

The radiography showed a healed fracture. The laboratory findings demonstrate lightly elevated parameters of inflammation (Lc 12.8, CPR 10). In the bacteriological culture the growth of *Staphylococcus capitis* (sensitive to gentamicin) was determined. We proceeded with the removal of the metallic plate (Figure 6), took several biopsies for further bacteriological findings, debrided the wound and closed it with a negative pressure device. Every three to four days the negative pressure sponge was changed in the operating theater and the wound was debrided (Figure 7). The biopsies taken didn't show any further bacterial growth and the wound started to granulate so that a secondary



wound closure was performed leaving inside a "drainage of redon" which was removed after a few days.

After dismissal the patient did not take the resistance tested antibiotics regularly and did not present himself to the scheduled control appointments as agreed.

<p align="center">Figure 7</p>	<p align="center">Figure 8</p>
	
<p align="center">Negative pressure therapy</p>	<p align="center">Gentamicin chain therapy</p>

After some time the patient presented himself with a purulent wound again. The radiography did not show any abnormalities. The patient refused to repeat the therapy with the negative pressure device. We debrided the wound thoroughly, took biopsies for bacteriology and placed a gentamicin chain deep into the wound (Figure 8). After several weeks we took out the chain in the operating theater.

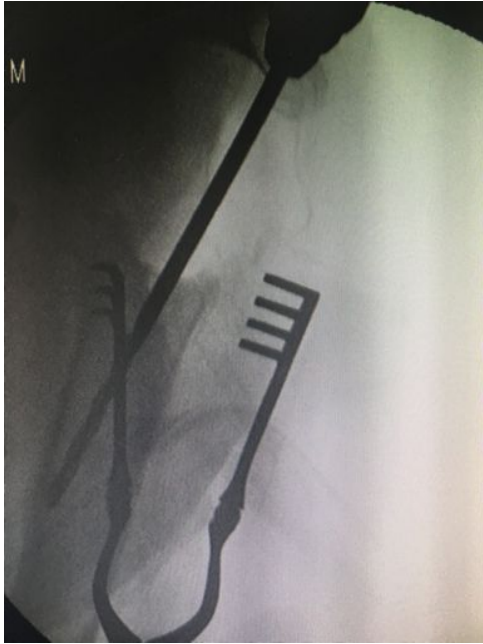Also this second try remained without success. The patient returned again with a secreting wound and in this case the radiography showed an osteomyelitis of the head of the humerus with deformation and missing bone (Figure 9). The classification after Charney was IV.

<p align="center">Figure 9</p>	<p align="center">Figure 10</p>
	
<p align="center">Rx osteomyelitis</p>	<p align="center">Macroscopic osteomyelitis</p>

We decided to do a one-stage surgical procedure with debridement, drill up the bone (Figure 11) and introduction of the antibiotic-loaded resorbable bone-graft substitute during radiographic control (Rx intra op Figure 12, Rx post op Figure 13). The necrotic part of the humerus head was resected with a radical debridement (figure 10) and at least ten

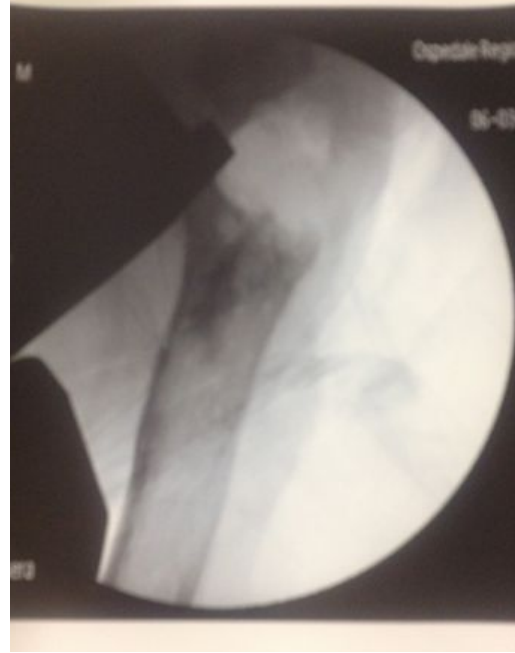samples were taken for bacteriology and histology. In the bacteriological culture the growth of Staphylococcus epidermidis (sensitive of gentamicin).

Figure 11



Drill up the bone marrow

Figure 12

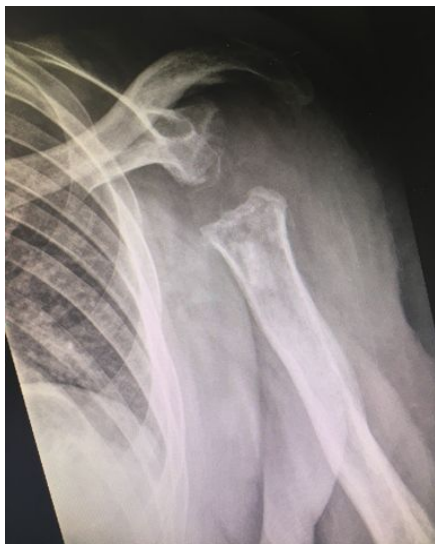

Rx intra op: fill in the antibiotic-loaded resorbable bone-graft substitute

We used the Ultrasonic-Assisted Wound Debridement device for cleaning the wound. The wound was closed immediately. The wound secreted a serous

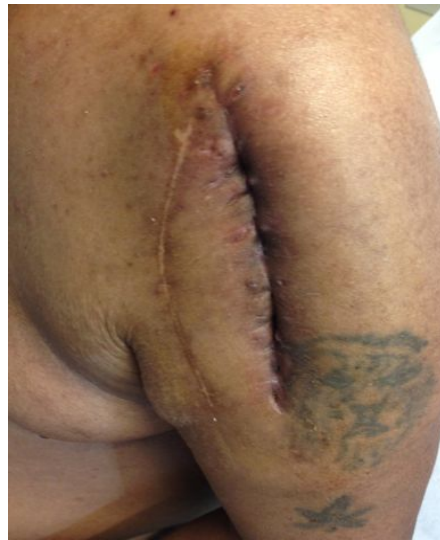fluid for approximately four weeks after that the wound was dry (Figure 14).

Figure 13



Rx post op with antibiotic-loaded resorbable bone-graft substitute



Figure 14



Wound post op


The patient was checked at first in a daily basis, after two weeks the patient was able to go home. The wound was seen every week, after a month every two weeks and after three months every three weeks. An antibiotic therapy for three months was prescribed which was not followed regularly despite the help of a guardian.

The x-ray examination after six months showed a dissolved bone-graft and the formation of a strong bone (Figure 18). And the wound was healed without secreting serous fluid (Figure 17).

Figure 17	Figure 18
	
<p>Wound after 6 month</p>	<p>Rx after 6 month: the antibiotic-loaded bone-graft substitute is resorbed</p>

The patient is now able to move his left hand toward his mouth, the abduction of the shoulder is 60°

(Figure 18). The internal rotation movement is feasible (Figure 19).

Figure 18	Figure 19
	
<p>Range of motion after 6 month</p>	<p>Range of motion after 6 month</p>

III. DISCUSSION

The need for surgical revision is an enormous burden for the patient and their families as well as for the healthcare system and hospital staff. Any reduction of the hospitalization time, of the complication rates or recurrence rate is especially important in this highly problematic group of patients.

The patient had some serous fluid leak but healed. We found that any excess bone-graft substitute must be completely removed; otherwise there will be prolonged secretion.

We often see that patients do not complete the three-month antibiotic treatment because of side effects such as abdominal pain or nausea, or because of the patients very low reliability. The antibiotic-loaded resorbable bone-graft substitute has an high antibiotic effect locally.

The x-ray examinations during follow-up show that the antibiotic-loaded resorbable bone-graft substitutes has dissolved and strong bone formed. In our patients with humeral head resection a foundation would then be created for a prosthetic replacement by patient with a good compliance.

To better understand the effectiveness of the therapy a larger numbers of patients must be studied in the future with longer observation periods.

Our experience in this case suggest that antibiotic-loaded reservable bone-graft substitute might help to reduce recurrence rates in this challenging group of patients. The antibiogram in bone biopsy was sensitive to gentamicin. A clarifying question in future studies would be whether oral antibiotic therapy with gentamicin is at all necessary in sensitivity germs at bone biopsy.

IV. CONCLUSION

Our case report suggests that this new kind of bone-graft could reduce the rates of recurrence and complications in long bone osteomyelitis in one sitting.

An ongoing prospective series is currently being done in our facility that will add additional evidence to help evaluate this hypothesis. Further studies will be required before any definitive statement can be made. The evidence of efficacy of this device in osteomyelitis therapie, combined with the logic of high local antibiotica depot give us reason to be optimistic.

Consent

Written informed consent was obtained from the patient for publication of this case report and accompanying images.