



GLOBAL JOURNAL OF MEDICAL RESEARCH: A
NEUROLOGY AND NERVOUS SYSTEM
Volume 16 Issue 2 Version 1.0 Year 2016
Type: Double Blind Peer Reviewed International Research Journal
Publisher: Global Journals Inc. (USA)
Online ISSN: 2249-4618 & Print ISSN: 0975-5888

Recurring Ischemic Infarcts Showing Biermer's Disease Associated with Protein S Deficiency

By Kokou Mensah Guinhouya, Léhleng Agba, Nyinévi Anayo & Mofou Belo

Universite de Lome

Observation- Mrs ASS....AKOU, 36 married and right handed household was at her second episode of stroke in six months.

Concerning her history; six months ago, during her first episode of stroke she was discovered and known to have a high blood pressure in the left anterior cerebral artery, responsible of an after effects right crural hemiparesis at 4/5.

She was not using hormonal contraception and there was not a sign of alcoholic or tobacco intoxication. Since six months she has been under second prevention with acetylsalicylic under 100 mg per day and sartan 150 mg per day.

The current episode was marked by a brutal installation of a left hemi body deficit predominant to inferior member in the morning of 26th December 2014 at her home. When she was admitted the exam allowed to note a blood pressure of 160/80 Hg in the left hand and 160/90 mmHg in the right, a beat of 78 pulsations per minute, a temperature at 37°C talking of a neurology she was conscious without trouble of superior functions.

GJMR- A Classification: NLMC Code: WL 348



Strictly as per the compliance and regulations of:



© 2016. Kokou Mensah Guinhouya, Léhleng Agba, Nyinévi Anayo & Mofou Belo. This is a research/review paper, distributed under the terms of the Creative Commons Attribution-Noncommercial 3.0 Unported License <http://creativecommons.org/licenses/by-nc/3.0/>), permitting all non-commercial use, distribution, and reproduction in any medium, provided the original work is properly cited.

Recurring Ischemic Infarcts Showing Biermer's Disease Associated with Protein S Deficiency

Kokou Mensah Guinhouya ^α, Léhleng Agba ^σ, Nyinévi Anayo ^ρ & Mofou Belo ^ω

Observation- Mrs ASS...AKOU, 36 married and right handed household was at her second episode of stroke in six months

Concerning her history; six months ago, during her first episode of stroke she was discovered and known to have a high blood pressure in the left anterior cerebral artery, responsible of an after effects right crural hemiparesis at 4/5.

She was not using hormonal contraception and there was not a sign of alcoholic or tobacco intoxication. Since six months she has been under second prevention with acetylsalicylic under 100 mg per day and sartan 150 mg per day.

The current episode was marked by a brutal installation of a left hemi body deficit predominant to inferior member in the morning of 26th December 2014 at her home. When she was admitted the exam allowed to note a blood pressure of 160/80 Hg in the left hand and 160/90 mmHg in the right, a beat of 78 pulsations per minute, a temperature at 37°4C talking of a neurology she was conscious without trouble of superior functions. She was presenting a paraplegia with no sensitive level nor trouble of sphincter with a left predominance and mortice forces at 4/5 in the right inferior member and 1/5 in the left inferior member. There was signs of spasticity in the right inferior member. The cerebral scan CT which was urgently made allowed to objective post ischemic after effect in the left anterior cerebral artery and a sharp phase of ischemic in the right anterior cerebral artery (fig 1). The injected tomography from supra aortic artery trunks was normal. The electrocardiogram was at a sinus rhythm and so was the transthoracic and the trans oesophagus echography. The hemogram showed a slight anaemia (haemoglobin = 11,5 g/dl) macrocytic (MCV = 115 fl). The mixture protein S and C showed a deficit in protein S. the renal and hepatic functions was normal.

REFERENCES BIBLIOGRAPHIQUES

1. Bamford J, Sandercock P, Dennis M, Burn J, Warlow C. A prospective study of acute cerebrovascular disease in the community: the Oxfordshire Community Stroke Project 1981-86. 2. Incidence, case fatality rates and overall outcome at one year of cerebral infarction, primary intracerebral and

subarachnoid haemorrhage. *J Neurol Neurosurg Psychiatry* 1990; 53: 16-22.

2. Bevan H, Sharma K, Braley W. Stroke in young adults. *Stroke* 1990; 21:382-6.
3. Tairou A., Stadler A., Ahawo A. K. M. Création d'un système d'approvisionnement en médicaments essentiels et de recouvrement des coûts dans la région centrale du Togo. *Echos de santé* 1996; 34: 56-57.
4. A. Bougteba, A. Basir, N. Kissani. Infarctus cérébral récidivant révélant une maladie de Biermer. *Rev Neurol (Paris)*. 2009 Dec; 165 (12): 1099-102.
5. Rodeghiero F, Tosetto A. The epidemiology of inherited thrombophilia: the VITA Project. Vicenza Thrombophilia and Atherosclerosis Project. *Thromb Haemost* 1997; 78: 636-40.

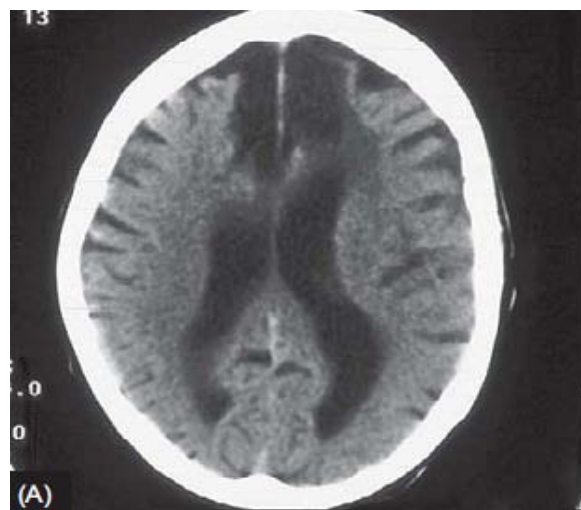


Figure 1 : Infarcts in both left and right anterior cerebral arteries

Author ^α ^σ ^ρ ^ω: Service de neurologie du CHU Sylvanus OLYMPIO; BP 57 ; 30284, Lomé- Togo. e-mail: herve_guinhouya@yahoo.fr