



GLOBAL JOURNAL OF MEDICAL RESEARCH: J  
DENTISTRY & OTOLARYNGOLOGY  
Volume 19 Issue 3 Version 1.0 Year 2019  
Type: Double Blind Peer Reviewed International Research Journal  
Publisher: Global Journals  
Online ISSN: 2249-4618 & Print ISSN: 0975-5888

## Monostotic Fibrous Dysplasia of Maxilla - A Case Report and Review

By Dr. Y. Raghavendra Reddy, Dr. C. N. V. Akhila, Dr. A. Ravi Prakash  
& Dr. M. Rajinikanth

**Abstract-** Fibrous dysplasia belongs to a group of fibro-osseous lesions in which cellular fibrous connective tissue stroma replaces bone. It is a developmental hamartomatous lesion with cases occurring below the age of puberty. Fibrous dysplasia can occur as the monostotic form in which single bone is affected and polyostotic where multiple bones are involved. Majority of the cases reported are the monostotic form with the common site of involvement being the craniofacial skeleton. Polyostotic form are often associated with McCune- Albright syndrome, Jaffe-Lichtenstein syndrome and, Mazabraud syndrome. The syndromic lesions manifest as triad of symptoms - fibrous dysplasias, endocrine abnormalities (endocrinopathies like precocious puberty and hypophosphatemia) and skin pigmentations (a cafe- au-lait spots). Fibrous dysplasias are expansile lesions and cause complications associated with the site of origin. The maxilla is the most common site of involvement in the craniofacial skeleton. In this case, a 13-year-old male patient presented who was having maxillary fibrous dysplasia.

**GJMR-J Classification:** NLMC Code: WU 158



*Strictly as per the compliance and regulations of:*



© 2019. Dr. Y. Raghavendra Reddy, Dr. C. N. V. Akhila, Dr. A. Ravi Prakash & Dr. M. Rajinikanth. This is a research/ review paper, distributed under the terms of the Creative Commons Attribution-Noncommercial 3.0 Unported License <http://creativecommons.org/licenses/by-nc/3.0/>), permitting all non-commercial use, distribution, and reproduction in any medium, provided the original work is properly cited.

# Monostotic Fibrous Dysplasia of Maxilla - A Case Report and Review

Dr. Y. Raghavendra Reddy <sup>α</sup>, Dr. C. N. V. Akhila <sup>σ</sup>, Dr. A. Ravi Prakash <sup>ρ</sup> & Dr. M. Rajinikanth <sup>ω</sup>

**Abstract-** Fibrous dysplasia belongs to a group of fibro-osseous lesions in which cellular fibrous connective tissue stroma replaces bone. It is a developmental hamartomatous lesion with cases occurring below the age of puberty. Fibrous dysplasia can occur as the monostotic form in which single bone is affected and polyostotic where multiple bones are involved. Majority of the cases reported are the monostotic form with the common site of involvement being the craniofacial skeleton. Polyostotic form are often associated with McCune-Albright syndrome, Jaffe-Lichtenstein syndrome and, Mazabraud syndrome. The syndromic lesions manifest as triad of symptoms - fibrous dysplasias, endocrine abnormalities (endocrinopathies like precocious puberty and hypophosphatemia) and skin pigmentations (a cafe-au-lait spots). Fibrous dysplasias are expansile lesions and cause complications associated with the site of origin. The maxilla is the most common site of involvement in the craniofacial skeleton. In this case, a 13-year-old male patient presented who was having maxillary fibrous dysplasia.

## I. INTRODUCTION

Fibro-osseous lesions comprise distinct clinical features with complications and co-morbid features. Fibrous dysplasia, cherubism, juvenile ossifying fibroma, osteoma, and aneurysmal bone cyst are the fibro-osseous lesions commonly encountered in the oral cavity. Fibrous dysplasia occurs as relatively rare neoplasm occurring during infancy or childhood. Monostotic fibrous dysplasia accounts for 80-85 % of all the cases with jaws being the prevalent site of involvement <sup>1</sup>.

The etiology is mainly genetic with postzygotic somatic mutations of the GNAS gene. Mutation of which leads to altered bone-forming cells which have fibroblastic phenotype and produce neoplasms at particular sites <sup>2</sup>. Thereby bone is replaced by fibrous connective tissue leading to irregular trabecular pattern and woven bone formation. Mostly the diagnosis of the lesion is made by clinical and radiographic features not

requiring biopsy. But some of them pose diagnostic difficulties in which biopsy is mandatory.

Treatment modalities differ based on the age and clinical behavior of the neoplasm. Surgical interventions may be difficult as they are more likely to be associated with significant anatomical structures. Follow up plays a major role if incomplete resection (remodeling) when done, lesions are more likely to recur over time. Bisphosphonate therapy can also be indicated in polyostotic fibrous dysplasia. Radiotherapy is contraindicated in these neoplasms as it increases the rate of malignant transformation, with the frequency of sarcoma occurrence <sup>3</sup>.

In this article, we present a case of monostotic fibrous dysplasia of maxilla in a 13-year-old patient.

## II. CASE REPORT

A 13-year-old male patient reported to G. Pullareddy dental college and hospital, oral and maxillofacial surgery department, with growth in the right maxillary region for one year. The patient complained that the lesion was insidious in onset with unusual growth pattern and attained the present size (Figure 1). The swelling was not associated with pain. No known family history is revealed by the patient. No associated trauma is admitted by patient. Laboratory investigations were normal. On extraoral examination, gross facial asymmetry was noticed on the right side of the face, with a deviation of the nose to left side (Figure 2). Anteriorly the lesion extended below the orbit region at the zygomatic process of the right maxilla without eye involvement. Posteriorly it extended till the malar area of the right side face. Upon inspection the growth was round circumscribed and well-demarcated, measuring 3 X 5 cm. On palpation, the lesion was bony hard, non-tender and was not associated with pain. Intraoral examination revealed expansile swelling extending 5cm anteroposteriorly from the mesial aspect of 14 to distal side of 17 with obliteration of vestibule and 4cm Buccopalatally with bi-cortical expansion, without crossing the mid-palatal line (Figure 3). Retained 54, 55 and clinically missing 13, 15 are observed. Blanching of alveolar mucosa at 55 and 54 is observed. OPG findings revealed radiopaque, ground glass appearance borders blending with adjacent bone (Figure 4). No resorption or displacement of teeth involved is found. CBCT axial view showed varied degrees of opacifications, and coronal view showed thinning of cortical plates, with

**Author α:** MDS, Oral and Maxillofacial Surgery, G. Pullareddy Dental College and Hospital, Kurnool, NTRUHS.  
e-mail: rimpo2001@yahoo.co.in

**Author σ:** Post graduate student, Oral Pathology and Microbiology, G. Pullareddy Dental College and Hospital, Kurnool, NTRUHS.  
e-mail: drakhilacnv@gmail.com

**Author ρ:** Head of the Department, Oral Pathology and Microbiology, G. Pullareddy Dental College and Hospital, Kurnool, NTRUHS.  
e-mail: drravi17@yahoo.com

**Author ω:** Professor, Oral Pathology and Microbiology, G. Pullareddy Dental College and Hospital, Kurnool, NTRUHS.  
e-mail: dentopathfinder@gmail.com

pushing lateral wall and septum of nose medially (Figure 5 & Figure 6).

Provisionally a diagnosis of fibrous dysplasia was considered. Differential diagnosis of other fibro-osseous lesions such as, ossifying fibroma and osseous dysplasia are considered. Taking into consideration the age of the patient surgical recontouring and long term follow up was planned. Under general anesthesia the lesion was shaved, recontoured and reshaped. A vestibular approach was used exposing the anterior aspect till infraorbital region and the bone was shaved using osteotomes and rotary instruments and while periodically checking the amount of bone removal. After adequate removal of the swelling, the area was sutured. The bone bits are sent for histopathological examination (Figure 7).

Microscopically the H & E stained decalcified sections showed irregularly shaped trabeculae of woven bone in a cellular connective tissue stroma. The bony trabeculae are not rimmed by osteoblasts. Curvilinear shaped trabeculae were evident in focal areas. Lesional bone is adjacent to the normal bone. Artifactual peritrabecular clefting is also noticed. The fibrous stroma showed coarse, irregularly arranged collagen fibers with fibroblasts (Figure 8). Based on clinical, radiographic and histological features a final diagnosis of monostotic fibrous dysplasia of maxilla was given, and the patient was advised long term follow up.

### III. DISCUSSION

Fibrous dysplasia is a benign congenital fibro-osseous lesion with physiological bone replaced by fibrous tissues. It was first described by Albright et al. in 1937 in a patient with syndromic symptoms of skeletal neoplasms, skin pigmentation, and endocrine abnormalities<sup>4</sup>. Pathogenesis of fibrous dysplasia mainly involves mutations of the *GNAS1* gene (Guanine nucleotide-binding protein) located at chromosome 20q13.2<sup>5</sup>. Early postzygotic mutations cause polyostotic fibrous dysplasia with multiple sites of involvement, and late postzygotic mutations cause monostotic fibrous dysplasia with a single area of occurrence. As these mutations are somatic familial history is not expected, as seen in the present case. These mutations cause hyperfunction of bone progenitor cells which acquire fibroblastic phenotype. The medullary and cortical bones is replaced by sheets of fibro-osseous tissues along with trabecular bone. The fibrous dysplasia occurs below the age of ten years, equally in both males and females.

Clinically the lesion exhibits severe asymmetry and associated symptoms like visual impairment, diplopia, proptosis, hearing loss, nasal obstruction, epistaxis, epiphora, pain, and paresthesia<sup>6</sup>. Laboratory investigations show increased levels of alkaline phosphatase, serum calcium, and serum phosphate

levels. But in monostotic forms, the laboratory investigations are not elevated like in the present case. Radiographic features are generally diagnostic with characteristic ground glass appearance, orange peel or cotton wool appearance of bony trabeculae. Displacement and root resorption of associated teeth are absent in fibrous dysplasia as seen in the present case. Sometimes the density of fibrous dysplasia mimics multilocular appearance often misleading the diagnosis as ameloblastoma. Differential diagnosis of ameloblastoma, ameloblastic fibroma, ameloblastic fibro-odontoma, central giant cell granuloma, odontogenic cyst, ossifying fibroma, chronic sclerosing osteomyelitis, and osteosarcoma are considered for fibrous dysplasia. Treatment may involve radical surgery for devastating forms or shaving and debridement as a part of conservative treatment. Sometimes the lesion is said to be regressed as the patient reaches adulthood, but this concept is not proven. Few cases reports also mentioned about deferring treatment till the patient is above ten years of age or as such with a close follow up.

### IV. CONCLUSION

In our case report, we presented clinical, radiographic, histopathological features and, treatment plan for a case of monostotic fibrous dysplasia of maxilla. Proper clinical and radiographic features of the patient are mandatory for confirmative diagnosis. Based on the clinical behavior and age of the patient, appropriate treatment has to be planned with early intervention to avoid complications. Recurrences are frequently seen in fibrous dysplasia. Hence long term follow up should be done. Our case with its clinical and radiographic features represents an addition to the literature of monostotic fibrous dysplasia.

### REFERENCES RÉFÉRENCES REFERENCIAS

1. Bansal, Puja & Vaid, Neha. Monostotic Fibrous Dysplasia of the Maxilla: Report of a Rare Case. *Journal of Oral Health & Research*. 2013; 4: 46-50.
2. Bhattacharyya N, Wiench M, Dumitrescu C, Connolly B M, Bugge T H, Patel H V, Gafni R I, Cherman N, Cho M, Hager G L, Collins M T. Mechanism of FGF23 processing in fibrous dysplasia. *Journal of bone and mineral research*. 2012 May; 27(5): 1132-41.
3. Sherman N H, Rao V M, Brennan R E, Edeiken J. Fibrous dysplasia of the facial bones and mandible. *Skeletal radiology*. 1982 May 1; 8(2): 141-3.
4. Warrick C K. Polyostotic Fibrous Dysplasia Albright's Syndrome. *The Journal of bone and joint surgery. British volume*. 1949 May; 31(2): 175-83.
5. Adetayo O A, Salcedo S E, Borad V, Richards S S, Workman A D, Ray A O. Fibrous dysplasia: an

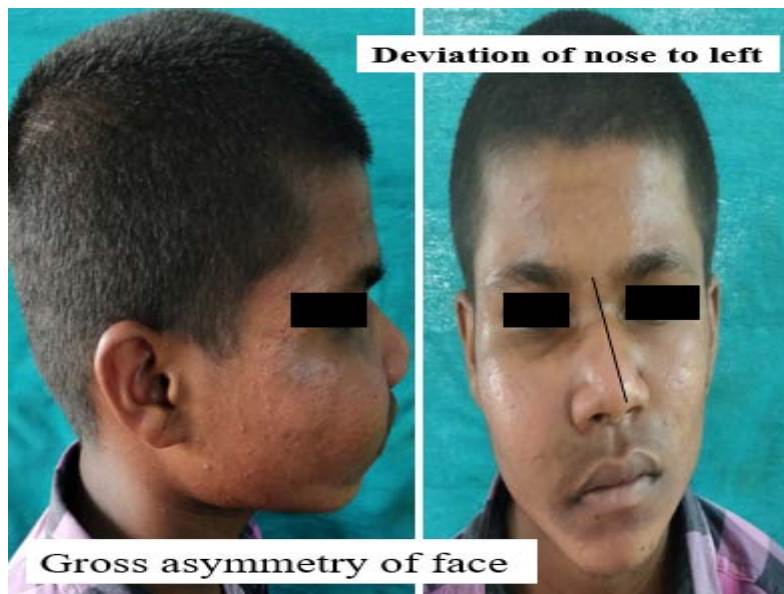overview of disease process, indications for surgical management, and a case report. *Eplasty*. 2015; 15.

6. Liakos G M, Walker C B, Carruth J A. Ocular complications in craniofacial fibrous dysplasia.

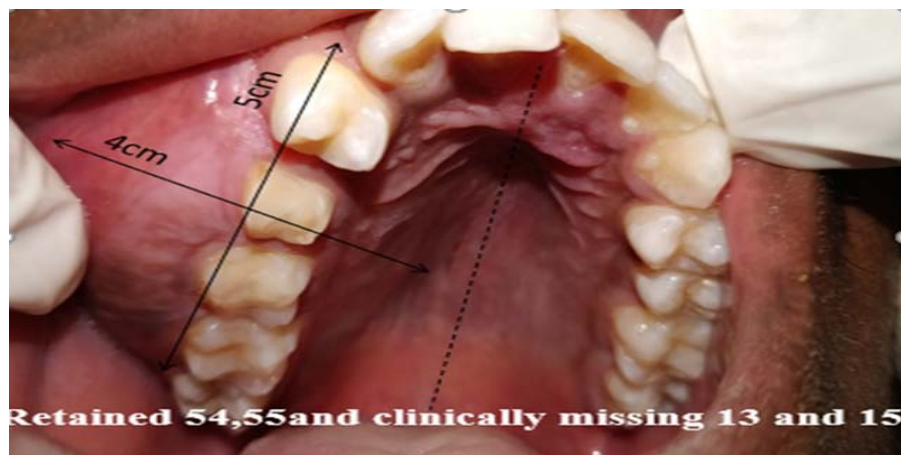
*British Journal of Ophthalmology*. 1979 Sep 1; 63(9): 611-6.



*Figure 1:* Extraoral photograph of the patient



*Figure 2:* Deviation of nose is noticed to left side



*Figure 3:* Intraoral Photograph of the patient

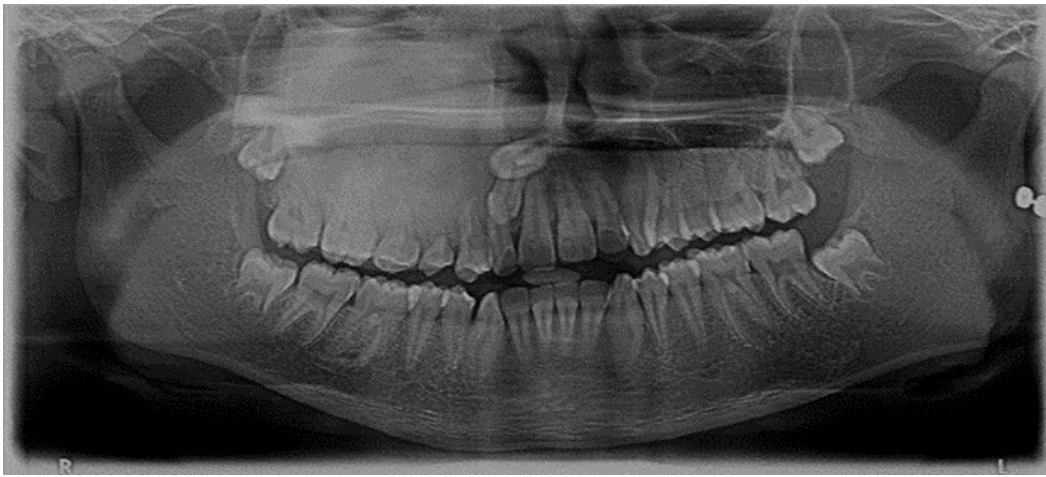

Figure 4: OPG

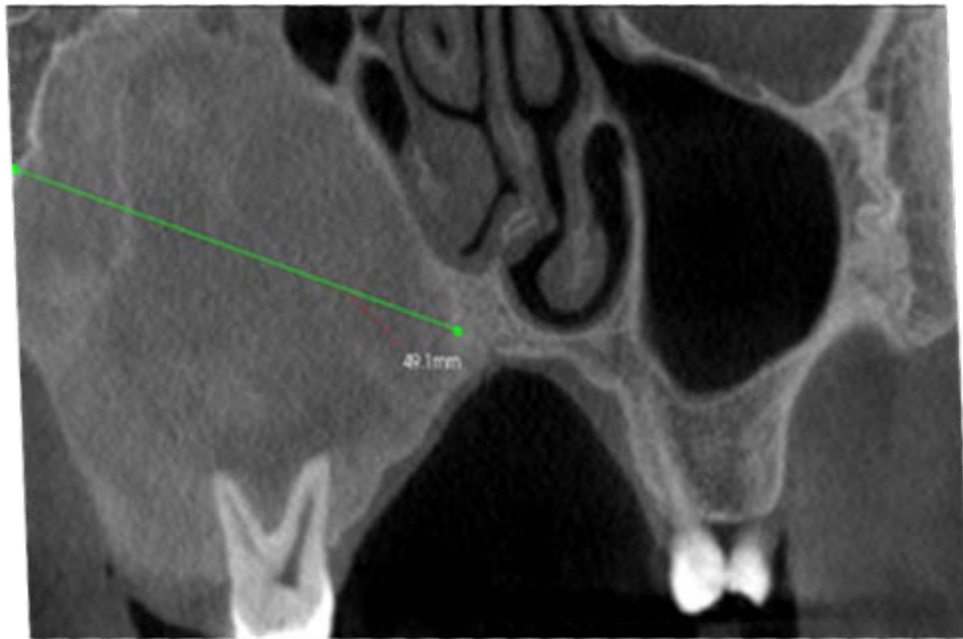

Figure 5: CBCT (axial view)

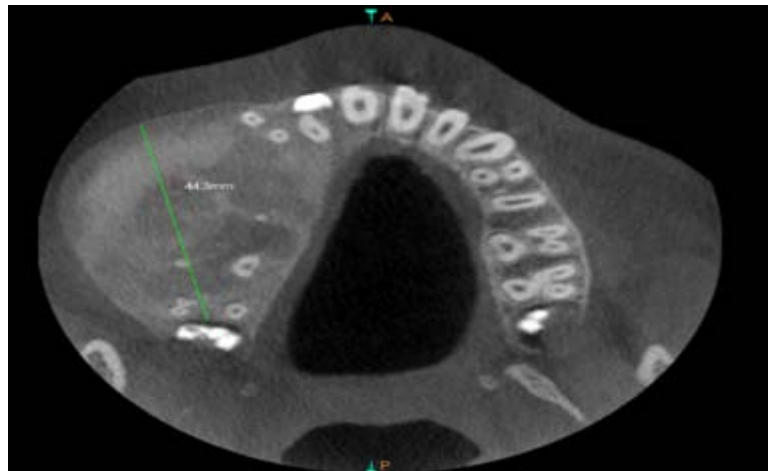
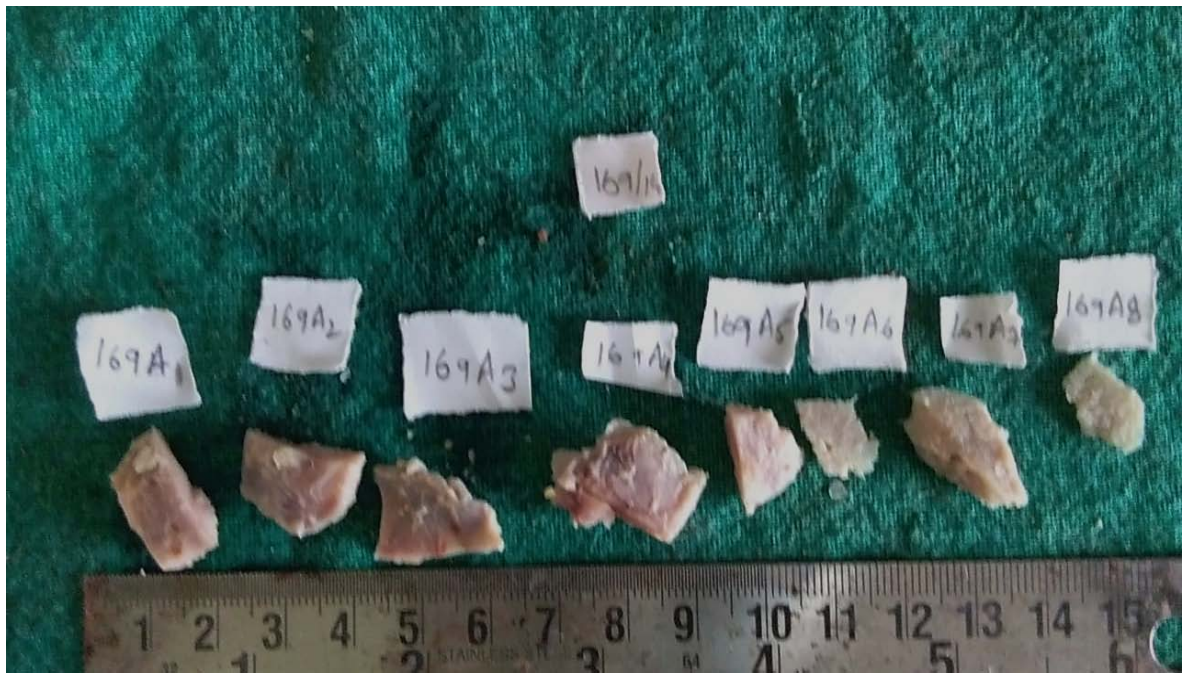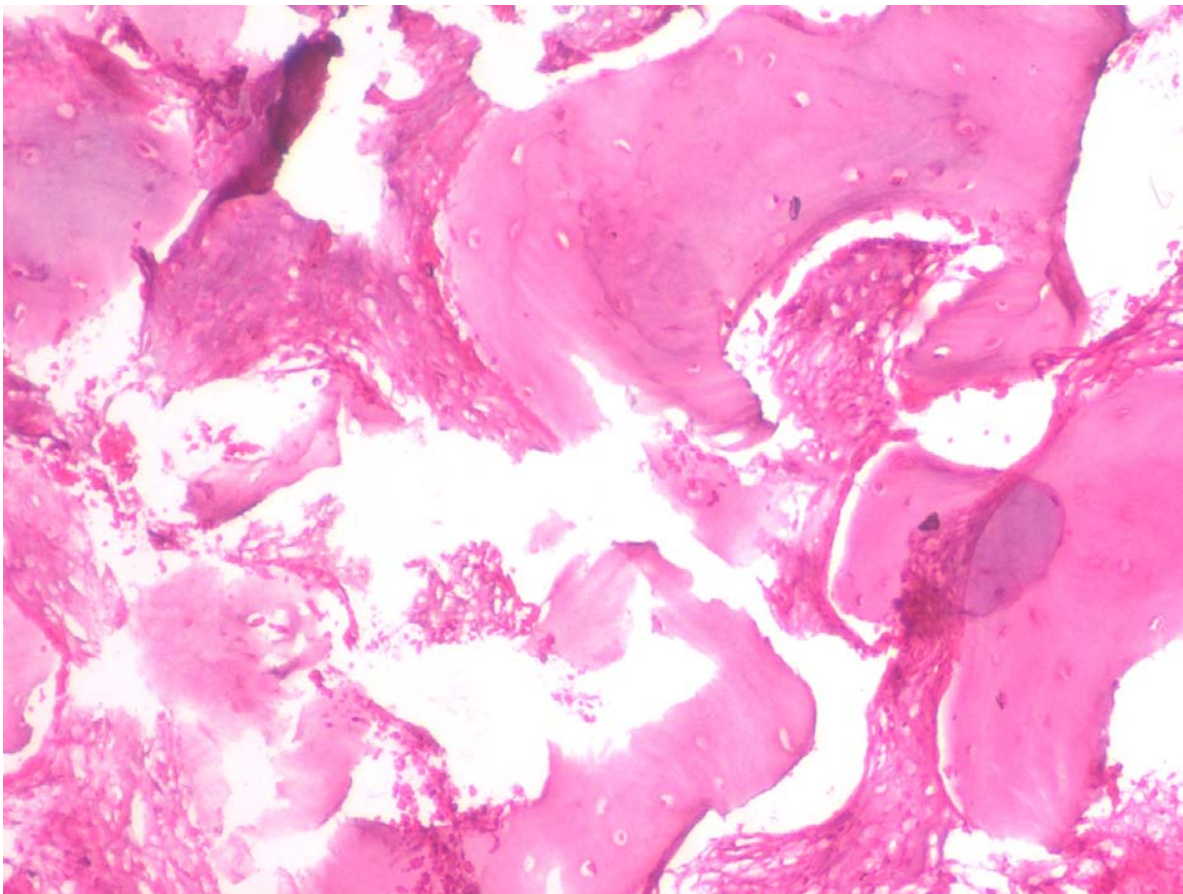


Figure 6: CBCT (coronal view)



*Figure 7:* Grossing picture of the lesion after biopsy



*Figure 8:* H & E picture of the lesion