



GLOBAL JOURNAL OF MEDICAL RESEARCH: B  
PHARMA, DRUG DISCOVERY, TOXICOLOGY & MEDICINE  
Volume 19 Issue 3 Version 1.0 Year 2019  
Type: Double Blind Peer Reviewed International Research Journal  
Publisher: Global Journals  
Online ISSN: 2249-4618 & Print ISSN: 0975-5888

## Histological Effects of Aqueous Stem Bark Extract of *Cadaba Farinosa* on Gastrointestinal Tract of Wistar Rats

By Solomon Matthias Gamde, Amali Abubakar Muhammad, Mohemmed Umar,  
Abdulraman Musa, Halilu Emmanuel Meshelia & Aliyu Saleh Illela

*Usmanu Danfodiyo University Sokoto*

**Abstract- Background:** *Cadaba farinosa* fork is widely used traditionally as mucosae plant medicine for treatments of diarrheal, dysentery, intestinal parasites, and ulcerative peptic diseases that are hard to cure even with conventional medicines.

**Aim and Objective:** The main aim of the study is to evaluate the possible histological effects of aqueous stem bark extract of *Cadaba farinosa* on the gastrointestinal tract of Wistar rats.

**Materials and Methods:** The lethal dose (LD50) of aqueous stem bark extract of *Cadaba farinosa* was determined using the Lorke's method. Thirty (30) male and female Wistar rats were selected and randomized into five groups of six rats per group. Group 1 served as the control group, and no extract was administered to the experimental animals while the rats in groups 2, 3, 4, and 5 were administered by gavage dose levels 100, 200, 300, and 400 mg/kg extract for twenty-eight days.

**Keywords:** *cadaba farinosa*, stem bark, wistar rats, intestinal goblet cells, mucin, and cyclooxygenase.

**GJMR-B Classification:** NLMC Code: QV 4



*Strictly as per the compliance and regulations of:*



© 2019. Solomon Matthias Gamde, Amali Abubakar Muhammad, Mohemmed Umar, Abdulraman Musa, Halilu Emmanuel Meshelia & Aliyu Saleh Illela. This is a research/review paper, distributed under the terms of the Creative Commons Attribution-Noncommercial 3.0 Unported License <http://creativecommons.org/licenses/by-nc/3.0/>), permitting all non-commercial use, distribution, and reproduction in any medium, provided the original work is properly cited.

# Histological Effects of Aqueous Stem Bark Extract of *Cadaba Farinosa* on Gastrointestinal Tract of Wistar Rats

Solomon Matthias Gamde <sup>α</sup>, Amali Abubakar Muhammad <sup>σ</sup>, Mohemmed Umar <sup>ρ</sup>, Abdulraman Musa <sup>ω</sup>, Halilu Emmanuel Meshelia <sup>¥</sup> & Aliyu Saleh Illela <sup>§</sup>

**Abstract- Background:** *Cadaba farinosa* fork is widely used traditionally as mucosae plant medicine for treatments of diarrheal, dysentery, intestinal parasites, and ulcerative peptic diseases that are hard to cure even with conventional medicines.

**Aim and Objective:** The main aim of the study is to evaluate the possible histological effects of aqueous stem bark extract of *Cadaba farinosa* on the gastrointestinal tract of Wistar rats.

**Materials and Methods:** The lethal dose (LD<sub>50</sub>) of aqueous stem bark extract of *Cadaba farinosa* was determined using the Lorke's method. Thirty (30) male and female Wistar rats were selected and randomized into five groups of six rats per group. Group 1 served as the control group, and no extract was administered to the experimental animals while the rats in groups 2, 3, 4, and 5 were administered by gavage dose levels 100, 200, 300, and 400 mg/kg extract for twenty-eight days.

**Result:** The lethal dose (LD<sub>50</sub>) of aqueous stem bark extract of *Cadaba farinosa* is above 5000mg/kg. Sub-chronic oral administration of aqueous stem bark extract of *Cadaba farinosa forsk* at the tested doses showed numerous intestinal goblet cells that secrete mucin and cyclooxygenase.

**Conclusion:** Acute oral administration of aqueous stem bark extract of *Cadaba farinosa forsk* is safe up to 5000mg/kg body weight/day. Sub-chronic oral administration of aqueous stem bark extract of *Cadaba farinosa forsk* at the tested doses showed numerous intestinal goblet cells that secrete mucin and cyclooxygenase (COX) responsible for the synthesis of prostaglandin. Hence, *Cadaba farinosa forsk* is a possible source of anti-peptic ulcer drug since prostaglandins deficiency plays a critical role in the background of gastrointestinal lesions.

**Keywords:** *cadaba farinosa*, stem bark, wistar rats, intestinal goblet cells, mucin, and cyclooxygenase.

## I. INTRODUCTION

A peptic ulcer disease is major diseases of the gastrointestinal tract seen throughout the world<sup>1</sup>. The formation of peptic ulcer diseases depends

**Author α:** Corresponding author, Hospital Services Management Board Sokoto, Nigeria. e-mail: solomonmatthias85@gmail.com

**Author σ:** Department of Pharmacology and Toxicology, Usmanu Danfodiyo University Sokoto, Nigeria.

**Author ρ ω:** Department of Anatomy and Forensic Medicine, Usmanu Danfodiyo University Sokoto, Nigeria.

**Author ¥:** Department of Pharmacognosy and Ethno medicine, Usmanu Danfodiyo University Sokoto, Nigeria.

**Author §:** Primary Healthcare Agency, Board Sokoto, Nigeria.

on the presence of acid and peptic activity in gastric juice with a breakdown in mucosal defenses of the gastrointestinal tract<sup>2</sup>. The prevalence of Helicobacter pylori infection and widespread use of acetylsalicylic acid and other nonsteroidal anti-inflammatory drugs (NSAIDs) are known etiologic agents disrupting mucosal resistance to injury<sup>3,4</sup>. Several other pathogenic elements postulated for gastrointestinal lesions, include prostaglandins deficiency, bile acids, bacterial flora, and nitric oxide<sup>5,6</sup>, yet the precise mechanisms remain unknown.

Currently, the prevention and cure of peptic ulcer diseases are among global health challenges confronting medicine<sup>2</sup>. In our review, most reported studies give the general idea of peptic ulcer and its management using synthetic drugs demonstrated intermittent relapses and adverse drug interactions<sup>7,8,9</sup>.

However, many medicinal plants have been reported to possess beneficial effects in gastrointestinal disorders, especially ulcerative peptic diseases with a high level of safety compared to most synthetic drugs<sup>10</sup>. In developing countries, most people still rely on medicinal plants to meet their health needs, especially in cases where synthetic medicines could not provide relief from hard-to-cure illnesses<sup>11,12</sup>. *Cadaba farinosa* belongs to the capparidaceae (capparaceae) family<sup>13</sup>. The plant is enriched with abundant phytochemicals, including flavonoids and alkaloids are widely used in traditional medicine as antibacterial, antiprotozoal and anthelmintic agents to treats diarrheal, dysentery, and gastrointestinal parasites<sup>13,14</sup>. The stem bark of *Cadaba farinosa* served as aperients, purgative, and stomachic stimulants. In that desert of India and Pakistan, its extract is externally applied to fresh wounds to prevent sepsis, thereby assisting in healing<sup>15,16</sup>. In Nigeria, the analgesic and anti-inflammatory properties of *Cadaba farinosa* was reported among the people of Maiduguri, Jimeta, and Nguru<sup>17</sup>. The plant was also used in the management of gastric and duodenal ulcers by inhibition of carbonic anhydrase<sup>18</sup>. Hence, these findings prompted us to study the possible histological effects of the aqueous stem bark extract on the gastrointestinal tract.

## II. MATERIALS AND METHOD

### a) Experimental Animals

Wistar rats were procured from the Animal House, Faculty of Pharmaceutical Science, Usmanu Danfodiyo University Sokoto, and maintained with free access to standard animal pellets and water. The permission and approval for animal studies with Reg. NO: PTAC/Cf/OT/004-18 was obtained from the Faculty of Pharmaceutical Sciences, Animal Ethics Committee, Usmanu Danfodiyo University Sokoto.

### b) Plant Collection

The fresh stem bark of *Cadaba farinosa* was harvested from its natural habitat at the Faculty of Pharmaceutical Science, Usmanu Danfodiyo University Sokoto. The plant was authenticated and deposited at the Department of Pharmacognosy and Ethno medicine, Usmanu Danfodiyo University Sokoto, Nigeria.

### c) Plant Extraction

The fresh inner stems bark was shadow dried and pounded into small pieces using pestle and mortar. About 210g powdered plant material was soaked and extracted in 600mL of water at room temperature for 24 hours<sup>19</sup>. The liquid filtrates were concentrated and evaporated to dryness at 45°C in a water bath. The aqueous extract was stored at -4°C until used.

### d) Experimental Design

The acute toxicity and LD<sub>50</sub> determination were carried out using Lorke's method<sup>20</sup>. According to guideline 423 of the Organization for Economic Cooperation and Development (OECD), the first phase consists of nine Wistar rats that were separated into three groups of three rats each and the aqueous extract was administered by gavage at dose levels 10, 100, and 1000 mg/kg/day. A cage side observation was done to detect any behavioral signs of toxicity salivation, erection of the hair, diarrhoea or mortality.

Following the absence of toxicity sign, the second phase according to Lorke's consisted of three rats that were administered with dose levels 1600, 2900, and 5000mg/kg/24 hours. The animals were observed for signs of toxicity.

In the sub-acute study, thirty (30) male and female Wistar rats were selected and randomized into five groups of six rats per group. Group 1 served as the control while the rats in groups 2, 3, and 4 were administered with plant extract by gavage at dose levels 100, 200, 300, and 400mg/kg for twenty-eight days.

**Table 1:** Acute toxicity study and LD<sub>50</sub> determination of aqueous stem bark extract of *Cadaba farinosa* on Wistar rats (n=12)

Dose mg/kg body weight	Mortality	
	Phase I	Phase II
10		-
100		-
1000		-
1600	-	
2900	-	
5000	-	

### e) Tissue Histology

The intestines of Wistar rats were excised by abdominal incision and the tissues were fixed in 10% formal saline for 24 hours before being processed and embedded in paraffin wax. The tissues were sectioned with a rotary microtome at 5µm, and the cut sections were stained with Haematoxylin and Eosin (H&E) stain<sup>21</sup>. The stained slides were carefully examined under a light microscope at high power magnification, and photomicrographs were taken<sup>22</sup>.

## III. RESULTS

### a) Acute toxicity and LD<sub>50</sub> determination

The toxicity study and LD<sub>50</sub> determination result (Table 2) showed that oral administration of the aqueous stem bark extract of *Cadaba farinosa* at dose levels 10, 100, 1000mg/kg/24hours produced no behavioral sign of toxicity or mortality.

In Phase II, oral administration of the extract at dose levels 1600, 2900, and 5000mg/kg/day, indicated neither behavioral change nor death. The animals were as active as control. Therefore, the median lethal dose (LD<sub>50</sub>) of aqueous stem bark extract of *Cadaba farinosa* is above 5000mg/kg.

**Table 2:** Acute toxicity study following oral administration of aqueous stem bark extract of *Cadaba farinosa* on adult Wistar rats (n= 12)

Dose mg/kg body weight	Mortality	
	Phase I	Phase II
10	0/3	-
100	0/3	-
1000	0/3	-
1600	-	0/1
2900	-	0/1
5000	-	0/1

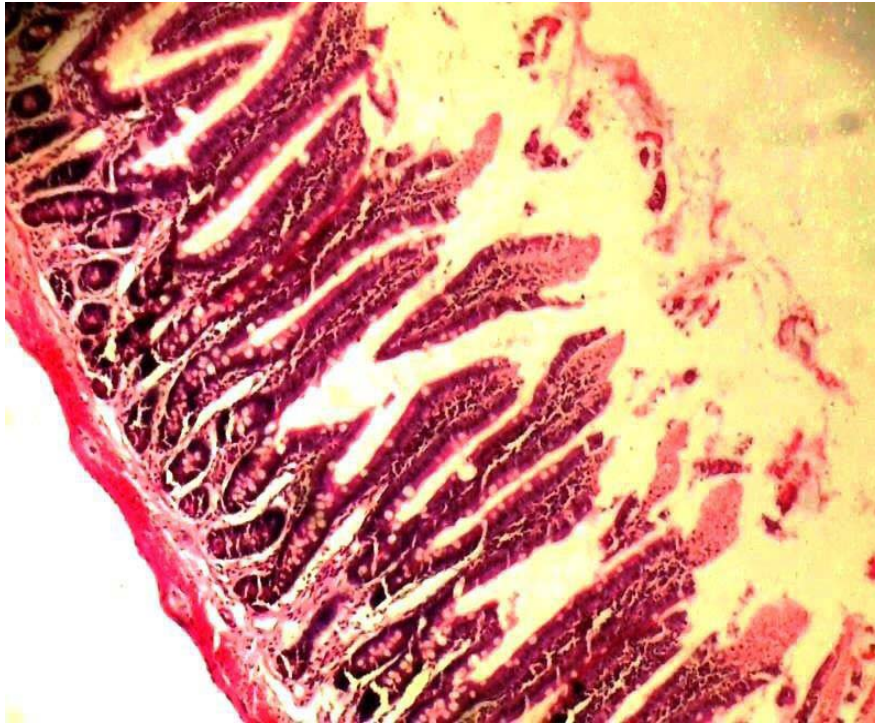
### b) Tissue effects of plant extract

Our histological finding showed normal intestinal goblet cells lined by epithelial cells and intact submucosa and smooth muscle layers (Plate 1).

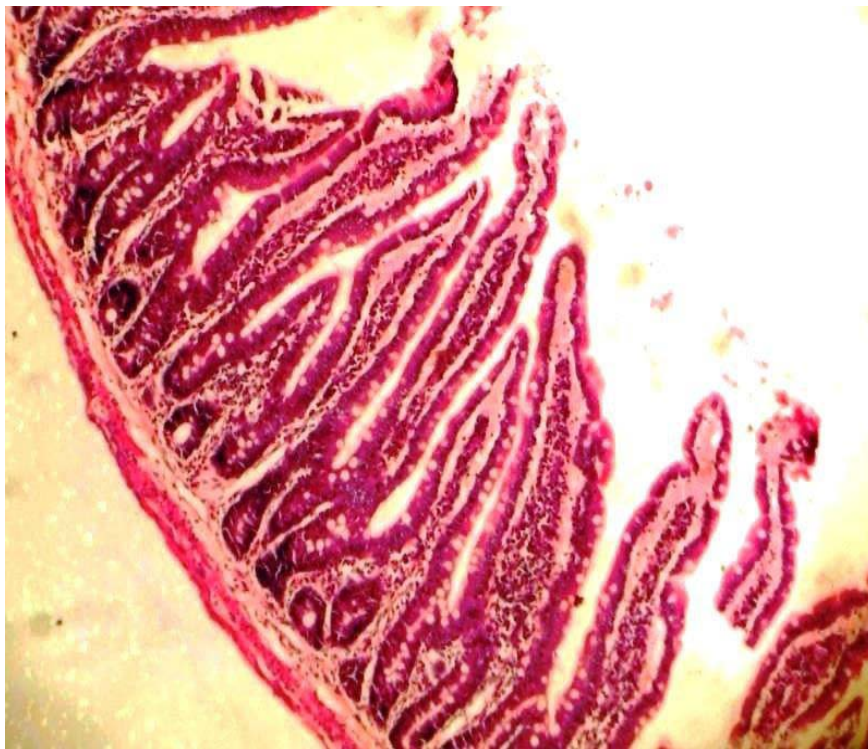
Extract administration of 100mg/kg/28days showed considerably increased intestinal goblet cells lined by epithelial cells and well-preserved submucosa and smooth muscle layers (Plate 2).



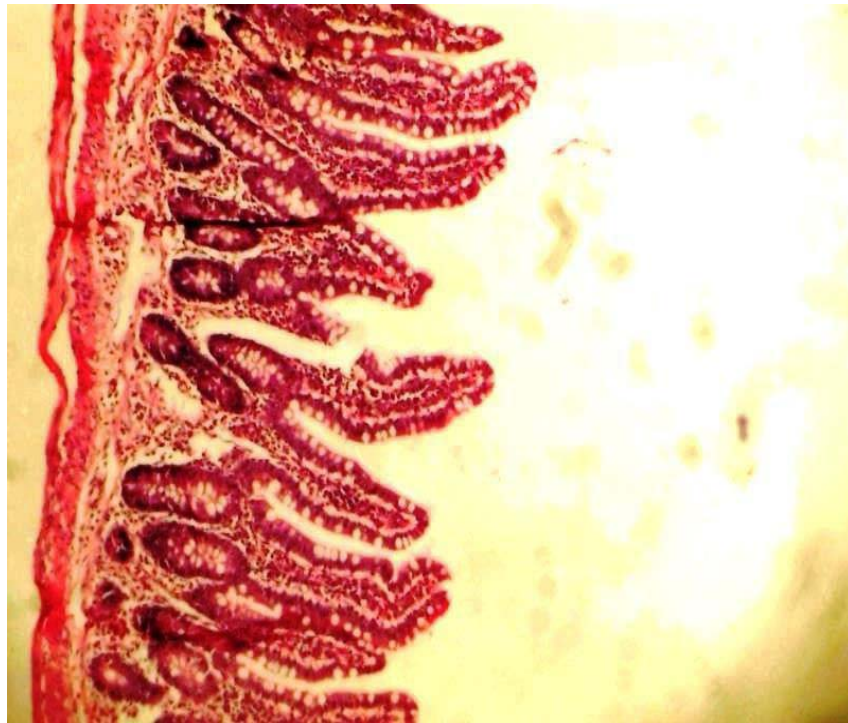
Extract administration of 200,300 and 400mg/kg/28 days showed numerous intestinal goblet cells, and well-preserved submucosa and smooth muscle layers (Plate 3, 4, and 5).



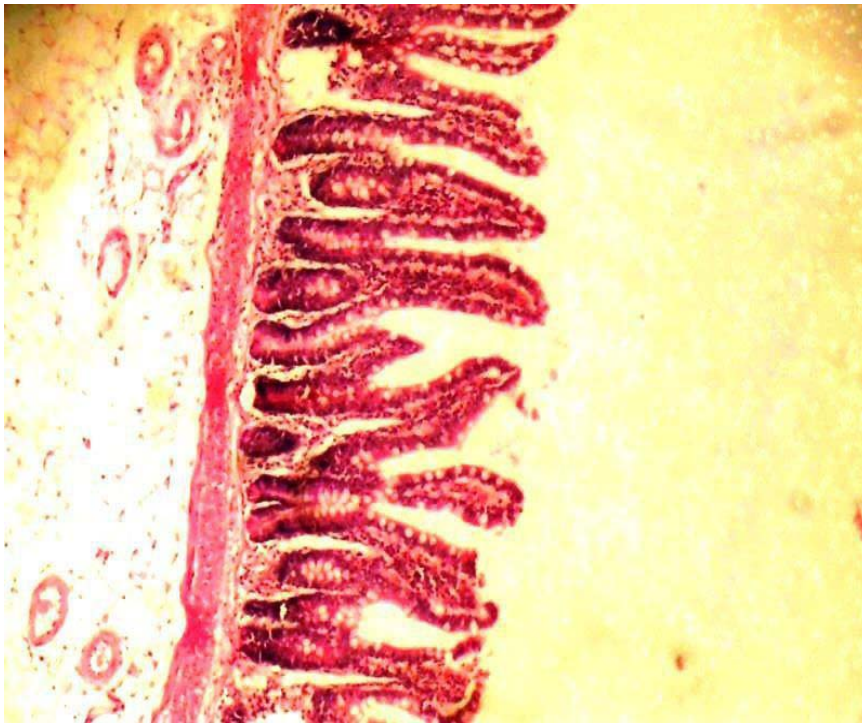
*Plate 1:* Normal control showed a mucosa layer with few intestinal goblet cells lined by epithelial cells and intact submucosa and smooth muscle layers. (H&E. X100).



*Plate 2:* Administration of 100mg/kg/28days showed a mucosa layer with considerably increased intestinal goblet cells lined by epithelial cell and well- preserved submucosa and smooth muscle layers. (H&E. X100).

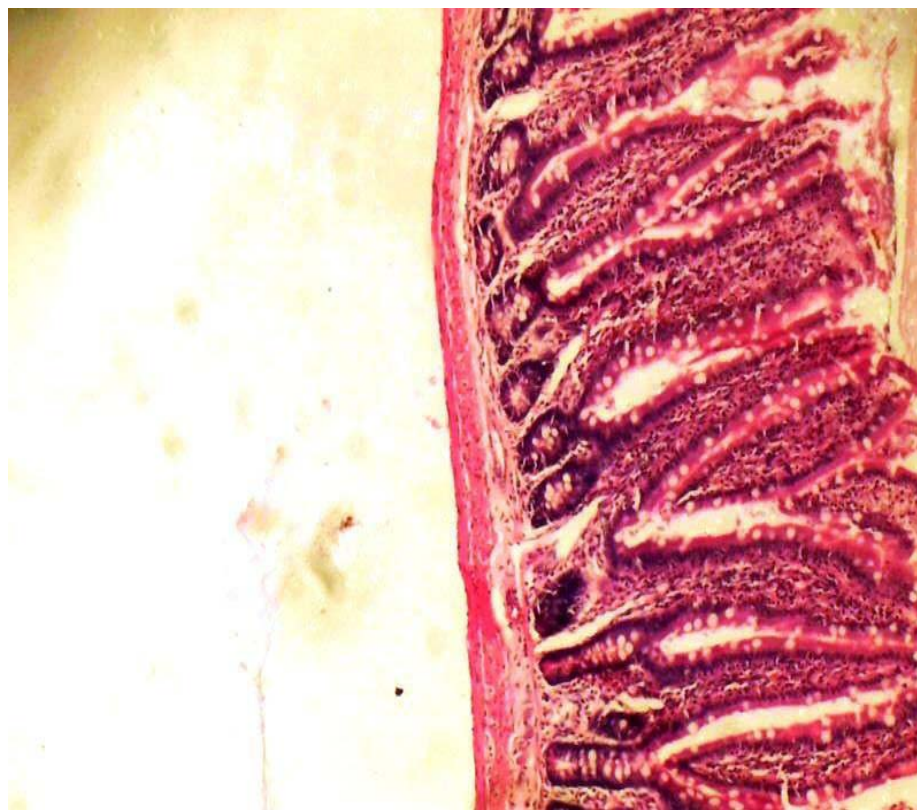


*Plate 3:* Administration of 200mg/kg/28days showed a mucosa layer with numerous intestinal goblet cells lined by epithelial cells and well-preserved submucosa and smooth muscle layers. (H&E. X100).



*Plate 4:* Administration of 300mg/kg/28days showed a mucosa layer with numerous intestinal goblet cells lined by epithelial cells, and well-preserved submucosa and smooth muscle layers. (H&E. X100).





**Plate 5:** Administration of 400mg/kg/28days showed a mucosa layer with numerous intestinal goblet cells lined by epithelial cells, and well-preserved submucosa and smooth muscle layers H&E. X100).

#### IV. DISCUSSION

Gastrointestinal lesions (ulcerative peptic diseases) is associated with several pathogenic elements, including prostaglandins deficiency, bile acids, bacterial flora, and nitric oxide,<sup>5,6</sup> yet the precise mechanisms remain unknown<sup>23</sup>. However, the overwhelming proportions of chemical agents (84.45%) used in most pharmaceutical industries for the production of conventional drugs used for the management of gastrointestinal lesions are gotten from plants<sup>24</sup>. In the present study, the acute toxicity study revealed that oral administration of *Cadaba farinosa* extract up to 5000mg/kg produced no immediate signs of toxicity or mortality indicating that the LD<sub>50</sub> was above 5000 mg/kg, therefore, this explains that aqueous extract of *Cadaba farinosa* could be administered to animals with some degree of safety, through oral route where absorption might not be complete due to inherent factors limiting gastrointestinal tract absorption<sup>25</sup>.

Our histological finding, showed a mucosa layer with few intestinal goblet cells lined by epithelial cells with intact submucosa and smooth muscle layers (Plate 1), while extract dose level 100mg/kg/28days showed considerably increased intestinal goblet cells and well-preserved submucosa and smooth muscle layers (Plate 2). A mucosa layer with numerous intestinal goblet cells that was lined by epithelial cells and well-preserved submucosa, and smooth muscle layers were

seen in animals at dose levels 200, 300, and 400mg/kg compared to the normal control with few intestinal goblet cells.

Intestinal goblet cells are unicellular glands<sup>26</sup>. These cells synthesized and secretes mucin and cyclooxygenase (COX) responsible for the synthesis of prostaglandin that is expressed in cyclooxygenase pathway 1 (COX-1) and the inducible cyclooxygenase pathway 2 (COX- 2) isoforms<sup>27</sup>. The intestinal goblet cells following oral administration of aqueous stem bark of *Cadaba farinosa* is indicative of high secretion of mucin COX-2 that would preserve vulnerable cellular compartment of the gastrointestinal tract. The luminal prostaglandin modulates acid concentration by inhibiting acid secretion, alter blood flow, and stimulate mucus and bicarbonate secretion leading to dramatic protection against mucosal damage. Our result is similar to the role of endogenous prostaglandins in gastric secretion and mucosa defence<sup>28</sup>, the anti-inflammatory effects of prostaglandins in ameliorating mucosal damage<sup>26,27</sup>, and stimulation of duodenal bicarbonate and mucus secretion mediated intestinal mucosal protection<sup>29,30,31</sup>. These physiological functions of mucin COX-2 could modulate major etiologic factors implicated in ulcerative peptic diseases, including lesions caused by NSAIDs were effectively prevented by supplementation of exogenous prostaglandin-endoperoxide synthase (PGE2)<sup>31,32,33</sup>.

Therefore, stem bark extract of *Cadaba farinosa* is a possible source of a drug, which modulates secretions of mucus, acid, and bicarbonates preceding dramatic protection against mucosal damage risk factors of ulcerative peptic diseases and gastrointestinal hemorrhage.

## V. CONCLUSION

This study showed that acute oral administration of aqueous stem bark extract of *Cadaba farinosa forsk* is safe up to 5000mg/kg body weight/day. Sub-chronic oral administration of aqueous stem bark extract of *Cadaba farinosa forsk* at the tested doses showed numerous intestinal goblet cells that secretes mucin and cyclooxygenase (COX) responsible for the synthesis of prostaglandin. Hence, *Cadaba farinosa forsk* is a possible source of anti-peptic ulcer drug since prostaglandins plays a critical role in the background of gastrointestinal lesions.

## ACKNOWLEDGEMENTS

We acknowledge the effort of Ayooye Samuel, the Principal Medical Laboratory Scientist of the Department of Histopathology, Usmanu Danfodiyo University Teaching Hospital Sokoto, Nigeria, for taking good photomicrographs for this study.

### Funding

No funding sources

### Conflict of interest

None declared

### Ethical approval

No: PTAC/Cf/OT/004-18 was obtained from the Faculty of Pharmaceutical Sciences, Animal Ethics Committee, Usmanu Danfodiyo University Sokoto.

## REFERENCES RÉFÉRENCES REFERENCIAS

1. Lucija Kuna, Jelena Jakab, Robert Smolic, Nikola Raguz-Lucic, Aleksandar Vcev and Martina Smolic. Peptic Ulcer Disease: A brief review of conventional therapy and herbal treatment options. *Journal of Clinical Medicine*, 2019; 8(179): 1-19.
2. Pahadiya Anitakumari Rambhai, S. S Sisodia. Indian Medicinal Plants for Treatment of Ulcer: Systematic Review, *UK Journal of Pharmaceutical and Biosciences*, 2018; 6(6): 38-44.
3. Aejaz Habeeb, Santosh K Tiwari, Avinash Bardia, Shaswathi Khan, Sandeep Kumar Vishwakarma, Safwaan Habeeb and Aleem Ahmed Khan. Peptic ulcer disease: descriptive epidemiology, risk factors, management and prevention. [www.smgebooks.com](http://www.smgebooks.com), Creative Commons Attribution 4.0 International License, Pp.1-13.
4. Monjur Ahmed. Peptic ulcer disease. Management of digestive disorders. In tech open access publisher. Pp. 1-20.

5. Reuter B. K, Davies N. M, Wallace J. L. Nonsteroidal anti-inflammatory drug enteropathy in rats: role of permeability, bacteria, and enterohepatic circulation. *Gastroenterology*, 1997; 112: 109-17.
6. Takeuchi K, Satoh H. NSAID-induced small intestinal damage: roles of various pathogenic factors. *Digestion*, 2015; 91: 218-32.
7. Mahmoud Bahmania, Arman Zargarab, Mahmoud Rafieian-Kopae. Identification of medicinal plants of Urmia for treatment of gastrointestinal disorders. *Revista Brasileira Farmacognosia*, 2014; 24: 468-480.
8. Kang J. Y, Elders A, Majeed A, Maxwell J. D, Bardhan K. D: Recent trends in hospital admissions and mortality rates for peptic ulcer in Scotland 1982-2002. *Aliment Pharmacol Ther.*, 2006; 24: 65- 79.
9. Ali Esmail Al-Snafi. Beneficial medicinal plants in digestive system disorders (part 2): plant based review. *IOSR Journal of Pharmacy*, 2016; 6(7): 85-92.
10. Tripathi A.S, V. Chitra, N W Sheikh, D. S Mohale and A. P Dewan. Immunomodulatory Activity of the Methanol Extract of *Amorphophallus campanulatus* (Araceae) Tuber. *Tropical Journal of Pharmaceutical Research*, 2010; 9 (5): 451-454.
11. Isah R. T, Mohammed M. O, Muhammad A. T, Sahabi S. M, Umar Z. U, Mahmud R. I, Abubakar U. Effects of aqueous leaf extracts of *Senna occidentalis* on rat kidney. *Africa Journal Biomedical Research*, 2018; 21: 225-230.
12. Umesh Telrandhe, Vaibhav Uplanchiwar. Phytopharmacological perspective of *Cadaba farinosa forsk*. *American Journal of Phytomedicine and Clinical Therapeutics*, 2013; 1: 011-022.
13. Ezekiel J and Kadam T. Phytochemical analysis and biological assay of the methanolic leaf extract of *Cadaba farinosa Forsk* (Capparidaceae). *International Journal of Advanced Research*, 2015; 3: 1368-1375.
14. Habib, A., Ghulam, R. B., Abdul, L. (2004). Medicinal flora of the Thar Desert: An overview of problems and their feasible solutions, *Zones Aridas. Pakistan*, 2004: 73-83.
15. Siva N, Ganesan, Banumathy N, Muthuchelian. Antifungal effect of leaf extract of some medicinal plants against *Fusariumoxysporum* causing wilt disease of *Solanummelogenal*. *Tamil Nadu India*, 2008: 1-8.
16. Mohammed, Z., Daja, A., Hamza, H., Gidado, A., and Hussaini, I. Ethno botanical survey of folkloric plants used in managing breast cancer by the traditional medical practitioners of North-East Nigeria. *Journal of Medical and Applied Bioscience*, 2014; 6: 29-43.
17. Ibrahim S. I, Ameh D. A, Atawodi S. E., Umar I. A., Jajere U. M. and Mohammed S. Y. In vitro inhibitory

- effect of methanol leaf extract of *Cadabafarinosa* on carbonic anhydrase activity, *International Journal of Biochemistry Research and Review*, 2016;11(4): 1-8.
18. Martín M. J., La -Casa C., Alarcón-de-la-Lastra C., J. Cabeza, I. Villegas and V. Motilva anti- oxidant mechanisms involved in gastroprotective effects of Quercetin. *Z. Naturforsch*, 1998; 52: 82- 88.
  19. Majekodunmi O., Zany K., Olanyaga, I, Shi L and Melanhin J. Selective Toxicity Diterpene from *Euphorbia Poi sonic*. *Journal of Medicinal Chemistry*, 1996; 39: 1005-1008.
  20. Lorke D. A new approach to practical acute toxicity testing. *Archives of Toxicology*, 1983; 53: 275-287.
  21. Awioro O. G. Histochemistry and Tissue Pathology. Principles and Techniques. 4<sup>th</sup> Edition, 2014; 123-425.
  22. Singh, D. Principles and Techniques in Histology Micrograph and Photomicrography. 2<sup>nd</sup> Edition, CBS Publishers and Distributors. Newdelhi. India, 2006; 19-54.
  23. Koji Takeuchi, Kikuko Amagase. Roles of prostaglandin E and EP receptors in mucosal protection and ulcer healing in the gastrointestinal tract. *Arch Dig Disord.*, 2017;1(2): 8-16.
  24. Mozhgan Ghobadi Pour, Naser Mirazi, Asghar Seif. Treatment of liver and spleen illnesses by herbs: Recommendations of Avicenna's heritage "Canon of Medicine". *Avicenna Journal of Phytomedicine*, 2019; 9(2): 101-116.
  25. Idakwoji, P. A., Ajima, J. N., Anosike, J. C., Amadi, E. B., and Nweje-Anyalowu, P. C. Effects of Aqueous Stem Bark Extract of *Citrusaurantifolia* on the Gastrointestinal Tract of Wistar Rats. *Asian Journal of Research in Medical and Pharmaceutical Sciences*, 2018; 5(3): 1-7.
  26. Leslie P. Gartner, James L. Hiatt. Colour Text Book of Histology. Digestive system. Small intestine. 3<sup>rd</sup> edition, Elsevier publisher, 2007; 400.
  27. Luo, C., Laine, V.J.O., Yilnen, L., Teros, t., Makinen, M., Ristimaki, A., and Simell, O. Expression of cyclooxygenase-2 in intestinal goblet cells of pre-diabetic NOD Mice. *Acta Physiologica Scandinavica*, 2002; 174: 265-274.
  28. Cohem M M. Role of endogenous prostaglandins in gastric secretion and mucosal defence. *Clin. Invest. Med.*, 1987; 10(3): 226-231.
  29. Morteau, O., Morham, S. G., Sellon, R., Dieleman, L. A., Langenbach, R., Smithies. Impaired mucosal defense to acute colonic injury in mice lacking cyclooxygenase-1 or cyclooxygenase-2. *Journal of Clinical Investigations*, 2000; 105: 469-478.
  30. Takeuchi K., Megumu O., Hiromichi N. and Okabe S. (), Role of sulphhydryls in mucosal injury caused by ethanol. Relation to microvascular permeability, gastric motility and cytoprotection. *J. Pharmacology. Exp. Ther.*, 1988; 248: 836-839.
  31. Araki, H., Ukawa, H., Sugawa, Y., Yagi, K., Suzuki, K., and Takeuchi, K. The roles of prostaglandin E receptor subtypes in the cytoprotective action of prostaglandin E2 in rat stomach. *Aliment Pharmacol. Ther.*, 2000; 14(1): 116-124.
  32. Aihara, E., Nomura, Y., Sasaki, Y., Ise, F., Kita, K., and Takeuchi, K. Involvement of prostaglandin E receptor EP3 subtype in duodenal bicarbonate secretion in rats. *Life Sci.*, 2007; 80: 2446-2453.
  33. Kunikata T, Tanaka A, Miyazawa T. 16-dimetyl prostaglandin E2 inhibits indomethacin- induced small intestinal lesions through EP3 and EP4 receptors. *Dig Dis Sci*. 2002; 47: 894-904.
  34. Tanaka A, Kunikata T, Konaka A, et al. Dual action of nitric oxide in pathogenesis of indomethacin-induced small intestinal ulceration in rats. *Journal of Physiol Pharmacol.*, 1999; 50: 405-17.