



GLOBAL JOURNAL OF MEDICAL RESEARCH: I
SURGERIES AND CARDIOVASCULAR SYSTEM
Volume 20 Issue 3 Version 1.0 Year 2020
Type: Double Blind Peer Reviewed International Research Journal
Publisher: Global Journals Inc. (USA)
Online ISSN: 2249-4618 & Print ISSN: 0975-5888

Clinical Efficacy of Surgical Treatment in 40 Patients with Acute Hematogenous Osteomyelitis

By Wang Linan, Wang Xuwei, Liu Jian, Li Yongai, Wanghui, Lin Jianwen,
Shi Jiandang, Ding Huiqiang & Niu Ning-Kui

Ningxia Medical University

Abstract- Objective: This study aimed to evaluate the diagnostic methods of acute hematogenous osteomyelitis and the clinical efficacy of fenestration decompression, focus debridement, and convective flushing.

Methods: A retrospective analysis was performed on 40 patients with acute hematogenous osteomyelitis admitted to the Department of Orthopedics of our hospital from January 2011 to December 2018. There were 21 males and 19 females, aged 1–70 years, with an average age of 21.45 ± 15.23 years, including 27 children and adolescents. The pathogenic sites were as follows: femur 20 cases, tibia 16 cases, humerus 2 cases, ulna 1 case, and radius 1 case. The systemic and local symptoms of patients before and after surgery were evaluated. The results of white blood cell count (WBC), NEUT%, hs-CRP, erythrocyte sedimentation rate (ESR), imaging examination, bacteriology, and pathological examination were analyzed. Fenestration decompression, focus debridement, and convective flushing were used at the site of lesion in the surgery.

Keywords: acute hematogenous osteomyelitis; surgical treatment; fenestration decompression; focus debridement.

GJMR-I Classification: NLMC Code: WE 251



CLINICALEFFICACYOFSURGICALTREATMENTIN40PATIENTSWITHACUTEHEMATOGENOUSOSTEOMYELITIS

Strictly as per the compliance and regulations of:



RESEARCH | DIVERSITY | ETHICS

© 2020. Wang Linan, Wang Xuwei, Liu Jian, Li Yongai, Wanghui, Lin Jianwen, Shi Jiandang, Ding Huiqiang & Niu Ning-Kui. This is a research/review paper, distributed under the terms of the Creative Commons Attribution-Noncommercial 3.0 Unported License <http://creativecommons.org/licenses/by-nc/3.0/>, permitting all non-commercial use, distribution, and reproduction in any medium, provided the original work is properly cited.

Clinical Efficacy of Surgical Treatment in 40 Patients with Acute Hematogenous Osteomyelitis

Wang Linan ^α, Wang Xuewei ^σ, Liu Jian ^ρ, Li Yongai ^ω, Wanghui [¥], Lin Jianwen [§], Shi Jiandang ^χ, Ding Huiqiang ^ν & Niu Ning-Kui ^θ

Abstract- Objective: This study aimed to evaluate the diagnostic methods of acute hematogenous osteomyelitis and the clinical efficacy of fenestration decompression, focus debridement, and convective flushing.

Methods: A retrospective analysis was performed on 40 patients with acute hematogenous osteomyelitis admitted to the Department of Orthopedics of our hospital from January 2011 to December 2018. There were 21 males and 19 females, aged 1–70 years, with an average age of 21.45 ± 15.23 years, including 27 children and adolescents. The pathogenic sites were as follows: femur 20 cases, tibia 16 cases, humerus 2 cases, ulna 1 case, and radius 1 case. The systemic and local symptoms of patients before and after surgery were evaluated. The results of white blood cell count (WBC), NEUT%, hs-CRP, erythrocyte sedimentation rate (ESR), imaging examination, bacteriology, and pathological examination were analyzed. Fenestration decompression, focus debridement, and convective flushing were used at the site of lesion in the surgery.

Results: Thirty-four of 40 patients showed obvious symptoms of systemic poisoning, and all patients had local pain, swelling, and elevated skin temperature. The WBC, NEUT%, hs-CRP, and ESR of patients before and after surgery significantly improved or returned to normal, and the difference was statistically significant ($P < 0.05$); the diagnostic accuracy of X-ray, CT, and MRI was 17.5%, 64.3%, and 95.0%, respectively. The accuracy of MRI was significantly higher than that of X-ray and CT, and the difference was statistically significant ($P < 0.05$). Thirty-eight of 40 patients underwent bacterial smear and culture of lesions; 11 cases were negative (28.9%), and 27 cases were positive (71.1%). Pathological results after the surgery were consistent with that of typical acute osteomyelitis or inflammatory changes. All 40 patients underwent fenestration decompression, focus debridement, and convective flushing, and the continuous convective flushing lasted for 10–21 days. The cases were also administered with sensitive antibiotics intravenously for anti-

infective therapy for 2 weeks and antibiotics orally for 4 weeks. Twenty-one were cured, 15 were improved, 3 were ineffective, and 1 died; the total effective rate was 90%.

Conclusion: Appropriate examination methods are of great significance for the early diagnosis and prognosis of acute hematogenous osteomyelitis. Fenestration decompression, focus debridement, and convective flushing are effective in the treatment of acute hematogenous osteomyelitis.

Keywords: acute hematogenous osteomyelitis; surgical treatment; fenestration decompression; focus debridement.

INTRODUCTION

Acute hematogenous osteomyelitis is a common type of pyogenic osteomyelitis that occurs most frequently in children and adolescents [1, 2]. It generally results from infection of a single pathogenic bacterium, the most common of which is methicillin-sensitive *S. aureus* (MSSA) [3, 4]. It is mainly characterized by bone destruction and resorption [5], with acute onset, rapid progress, and great harm. In case of no timely and appropriate diagnosis and treatment, it can lead to chronic osteomyelitis, local protracted course of disease, segmental bone defects and growth disorders, and serious complications such as multiple organ dysfunction syndrome (MODS) and death [6]. Therefore, early diagnosis and proper treatment of acute hematogenous osteomyelitis can effectively reduce its complications and better cure the disease. In this study, the clinical efficacy of 40 patients with acute hematogenous osteomyelitis who were surgically treated in our hospital was analyzed retrospectively to investigate the diagnosis and treatment of acute hematogenous osteomyelitis.

I. MATERIALS AND METHODS

a) General materials

A retrospective analysis was performed on 40 patients with acute hematogenous osteomyelitis who underwent surgery from January 2011 to December 2018. There were 21 males and 19 females, aged 1–70 years, with an average age of 21.45 ± 15.23 years, including 27 children and adolescents. The duration of hospitalization ranged from 2 to 43 days, with an

Author α: Ningxia Medical University, School of Clinical Medicine, Master Degree Candidate, 602 Shengli Street, Xingqing District, Yinchuan 750004 Ningxia, People's Republic of China.
e-mail: wanglinan117@163.com

Author σ: Medical record room, general hospital of ningxia medical university.

Author ρ ω ¥ §: Ningxia Medical University, School of Clinical Medicine.

Author χ ν: Department of Spinal Surgery, General Hospital of Ningxia Medical University.

Corresponding Author θ: Department of Spinal Surgery, General Hospital of Ningxia Medical University, 804 Shengli Street, Xingqing District, Yinchuan 750004 Ningxia, People's Republic of China.
e-mail: niuningkui@163.com

average of 23.9 ± 18.7 days. The duration from onset to operation was 2–30 days, with an average of 18.87 ± 13.82 days. The pathogenic sites were as follows: 20 cases of the femur, 16 cases of the tibia, 2 cases of the humerus, 1 case of the ulna, and 1 case of the radius. Four of the 40 patients had an upper respiratory tract preceding infection. Thirty-four of 40 patients showed obvious systemic poisoning symptoms, including chills, high fever, and restlessness, accompanied by nausea, vomiting, and fatigue. Six of them had no obvious symptoms of systemic poisoning, manifested as low fever, fatigue, and poor appetite. All patients had local redness and swelling, high skin temperature, movement disorder, tenderness, and percussion pain at pathogenic sites. In severe cases, ecchymosis and epidermal ulceration were observed.

b) *Laboratory examination*

Blood routine included white blood cell count (WBC), neutrophilic granulocyte, (NEUT%), high-sensitivity C-reactive protein (hs-CRP), erythrocyte sedimentation rate (ESR), and procalcitonin (PCT). The venous blood of the patients was collected, and WBC and NEUT% were detected by an automatic hematology analyzer. The serum hs-CRP was detected by immunoturbidimetry using a fully automatic biochemical analyzer. ESR was detected by an automatic ESR analyzer with reference to the national procedures or instrument manual [7, 8].

c) *Imageological examination*

For those with typical symptoms, X-ray and MRI scans of the lesion site were routinely performed, and the lesion scope and differential diagnosis were determined by MRI. For those with obvious bone destruction, 3D CT reconstruction was performed to further evaluate bone destruction.

d) *Bacteriological examination*

i. *Puncture fluid examination before surgery*

Following the principle of aseptic operation, We determined the puncture point and punctured it with sterile syringe to obtain 3-5ml puncture liquid, then put it into aseptic tubes, and routinely performed bacterial smear, general bacterial culture and identification examination.

ii. *Specimen collection during surgery*

Pus, necrotic and degenerated granulation tissue on the wall of the lesion, and broken bones were removed by a curette or rongeur and then transferred into aseptic tubes. Bacterial smears and general bacterial culture and identification were then performed.

iii. *Blood culture*

Patients' venous blood samples were obtained for blood culture when they were suffering from shivers and high fever (over 38.5°C). The blood sampling system of two sides and two bottles was adopted in

blood culture. When the automatic hematology analyzer yielded a positive result, the liquid in the blood culture bottle was removed for smearing and Gram staining. Routine bacterial identification and susceptibility testing were performed according to the staining results, mycelial morphology, and growth condition in aerobic and anaerobic plates[9].

e) *Pathological examination*

In 40 patients, pus, bone tissue, and granulation tissue were collected for pathological specimens. After the specimens were removed, they were routinely fixed by formalin, washed, dehydrated, waxed, embedded, paraffin sectioned, and examined by HE staining microscopy[10].

f) *Therapy*

i. *Systemic therapy*

The patients' nutritional status were improved through administration of a high-protein and high-vitamin diet to balance water, electrolyte, and acid-base levels. In case of anemia, fresh red blood cell suspension could be infused. When the patients were clinically diagnosed with acute hematogenous osteomyelitis, they were often administered intravenously with ceftazidime sodium or antibiotics of the same level for anti-Gram-positive cocci infection. The medication was adjusted after the pathogen type was confirmed by bacterial culture and sensitivity testing. The patients were given 2 weeks of intravenous administration of sensitive antibiotics. After normal body temperature, normal hemogram, and negative bacterial smear and culture for 3 consecutive times, intravenous antibiotics therapy was stopped and oral antibiotics continued for 4 weeks to consolidate the efficacy.

ii. *Surgical treatment*

Surgery was performed when the local symptoms could not be controlled after 48–72 h of antibiotic administration or when the local puncture fluid was clearly manifested as bacterial infection combined with systemic acute infection. Fenestration decompression, focus debridement, and convective flushing were applied during surgery. The scope of fenestration opening was determined according to MRI before surgery. After perspective positioning, the skin and subcutaneous tissue were incised to remove lesions of soft tissue and periosteum. Several holes with a diameter of 2.5 mm at the bone destruction were made. In case pus flowed out, the holes could be connected. The diseased bone was removed with an osteotome, and fenestration decompression was performed. The fenestration range should be large enough and based on NMR and local absence of pus; however, it should not be more than 1/3 of the circumference of the entire cortical bone. Curets and drills were used to thoroughly remove the lesions, which were rinsed repeatedly with iodophor, hydrogen

peroxide, chlorhexidine, and saline. After flushing, 3 blood transfusion tubes were placed in the bone marrow cavity as flushing tubes of convective flushing: 1 inlet tube and 2 outlet tubes. The drainage tubes were cut into ones with 3–5 holes on the side (the quantity was determined according to the extent of the lesion). The inlet tube was placed at the far end of the lesion, and the outlet tube was at the proximal end of the lesion. The two tubes were then tightly sutured. After suturing the fascia layer, normal saline was continuously injected from the inlet tube, and the smoothness of drainage was observed. In case of any leaks at the fascia layer, the suture was further sutured until there was no leakage, and the subcutaneous and skin were sutured. Continuous closed convection flushing was performed using saline with the daily volume of 3000 mL of normal saline for the first 3 days, followed by 2000 mL thereafter to monitor the change in hemoglobin and prevent hemorrhagic shock. Flushing was continued for 2–3 weeks, and it was stopped after the patient's body temperature was normal, the drainage fluid was clear, and the bacterial culture results were negative for 3 consecutive times. Subsequently, negative pressure drainage balls were used. When the drainage was less than 20 mL, all drainage tubes were removed. The patient continued to take sensitive antibiotics for 4 weeks after the surgery.

g) *Criteria for efficacy evaluation*

Cured: The clinical symptoms of the patient completely disappeared, the condition significantly

improved, and all indexes returned to normal. Moreover, no fistula, dead bone, or dysfunction occurred. *Improved:* The clinical symptoms of the patient basically disappeared, the condition greatly improved, and the indicators were normal. *Ineffective:* The clinical symptoms did not improve, or they worsened; chronic osteomyelitis developed, with recurrent fistulas tract and sequestrum[11, 12].

h) *Statistical analysis*

All data were statistically analyzed using SPSS 21.0 software and expressed as. The measurement data before and after surgery were compared by paired t-test. Chi-square test was performed on the imaging examination results, and the difference was statistically significant at $P < 0.05$.

II. RESULTS

a) *Comparison of the improvement of inflammatory index before and after surgical treatment*

WBC, NEUT%, hs-CRP, and ESR were compared before and 2 weeks after surgical treatment, and the differences were statistically significant ($P < 0.05$; see Table 1 for details). Blood routine, ESR, and hs-CRP were still sensitive indexes for the diagnosis and prognosis of acute hematogenous osteomyelitis.

Tab.1: Comparison of the improvement of the inflammatory index before and after surgical treatment

	Cases (n)	WBC ($\times 10^9$)	NEUT%	hs-CRP (mg/L)	ESR (mm/h)
Before	40	14.39 \pm 8.04	73.37 \pm 13.16	42.87 \pm 18.70	55.21 \pm 18.90
After	40	7.45 \pm 1.54	56.51 \pm 6.29	3.59 \pm 1.05	8.65 \pm 4.83
T value	-	5.35	7.39	13.20	9.37
P value	-	<0.05	<0.05	<0.05	<0.05

b) *Imaging examination results*

Combined with the bacterial culture of the puncture fluid at the lesion site of the patient and based on the surgical pathological results, the imaging diagnostic accuracy of X-ray, CT, and MRI was 17.5%, 64.3%, and 95.0%, respectively. The detection rates of X-ray, CT, and MRI for soft tissue lesions were 40.0%,

78.6%, and 100.0%, respectively. Then bone marrow abnormalities of X-ray, CT, and MRI were 50.0%, 78.6%, and 95.0%, respectively. The MRI results were significantly higher than those of X-ray and CT. The chi-square test was performed, and the difference was statistically significant ($P < 0.05$). The specific statistical results are shown in Table 2.

Tab.2: Comparison of X-ray, CT, and MRI results in the examination of acute hematogenous osteomyelitis

Method	Rate of soft tissue lesions	Rate of abnormal bone marrow	Diagnostic sensitivity
X-ray (40)	40.0% (16)	50.0% (20)	17.5% (7)
CT (14)	78.6% (11)	78.6% (11)	64.3% (9)
MRI (40)	100.0% (40)	95.0% (38)	95.0% (38)

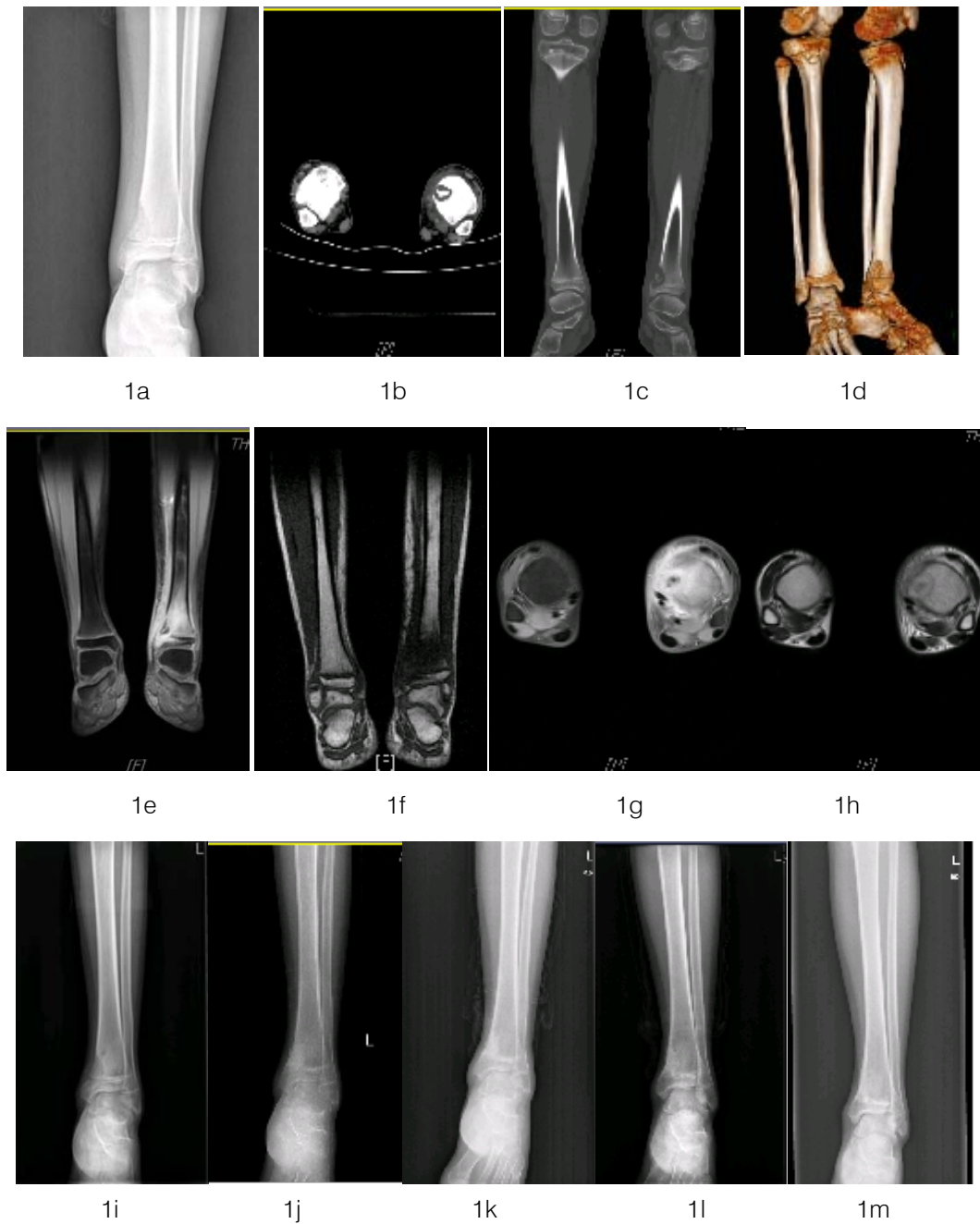


Figure 1: The patient, male, 13 years old, diagnosed with acute pyogenic osteomyelitis in the distal left tibia.

1a X-ray of left tibia and fibula before surgery: bone destruction on the metaphysis of the left tibia, involving the cortical area, abnormal bone density of epiphyseal plate and epiphysis, and swelling of soft tissue around the lesion;

1b and 1c: CT of the left tibia and fibula before surgery: bone destruction on the medial side of the metaphysis of the left tibia, observable high-density image in the lesion, the involved cortical area, accompanied with the involvement of the epiphyseal plate and epiphysis, and the surrounding soft tissue swelling

1d: 3D CT reconstruction of the left tibia and fibula: bone destruction on the medial side of the metaphysis of the left tibia;

1e—1h: MRI of the left tibia before surgery: medial bone destruction in the lower part of the left tibia, the lesion involved the cortical area, accompanied with abnormal signals of the epiphyseal plate and epiphysis, and the surrounding soft tissue edema;

1i to 1m: X-ray when reexamined at 1, 2, 3, 6, and 12 months after surgery showed complete focus debridement, improvement of soft tissue swelling, and healing of the focus.

c) *Bacterial culture results*

Thirty-eight of the 40 cases were used as specimens for bacterial smear and culture; 11 had negative results (28.9%), and 27 had positive results (71.1%). Of the 27 patients with positive results, 8 had preoperative puncture sampling and culture. Twenty-three cases had MSSA infection (1 combined with *Acinetobacter baumannii* and *Enterobacter cloacae*; 1 combined with *Klebsiella oxytoca*); 1 had Methicillin-resistant *Staphylococcus aureus* (MRSA) infection; 1 had *Klebsiella pneumoniae* infection (the patient combined with upper respiratory tract infection), and 2 had coagulase-negative MSSA.

d) *Blood culture results*

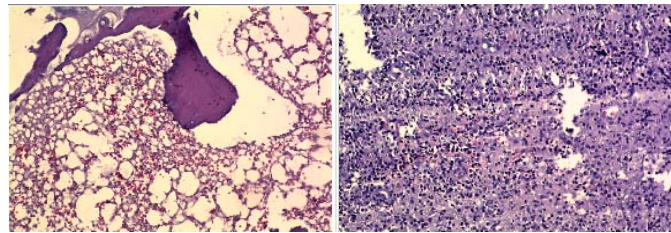
Thirteen of the 40 cases were used as specimens for blood culture (10 were obtained before

surgery) and 5 cases had positive results, of which 4 were MSSA and 1 was MRSA. Bacterial culture was performed on the specimens with positive blood culture results. Drug sensitivity testing was conducted on the obtained pathogens to guide the administration of sensitive and effective antibiotics in clinical practices.

e) *Pathological examination results*

After surgery, pathological results of the 40 patients were consistent with those of typical acute osteomyelitis or inflammatory changes, which were mainly manifested as large areas of infiltration of lymphocytes, plasmocytes, and neutrophils, and accompanied with abscesses and granulation tissues.

(Figure 2.)



2a (HE staining, $\times 100$)

2b (HE staining, $\times 400$)

Figure 2: Bone tissue and fibrous connective tissue; observable hemorrhage in some areas; large areas of infiltration of lymphocytes, plasmocyte, and neutrophils; and abscesses and granulation tissues.

f) *Clinical efficacy*

After the treatment, among 40 patients, 21 were cured, 15 improved, 3 were ineffective, and 1 died. The total effective rate was 90%. A total of 37 cases underwent continuous convective flushing for 2–3 weeks and administered with sensitive antibiotics for 4 weeks after surgery. Three cases had the drainage tube blocked, which was removed 1 week after the surgery. Two cases were complicated with chronic osteomyelitis after surgery, and there was sinus drainage from the incision, which was cured after 6 months of conservative treatment. One case underwent further aggravated infection, bone destruction, and bone resorption, leading to segmental femur defect; this patient was transferred to an external hospital for further treatment. A 5-year-old child was diagnosed with acute hematogenous osteomyelitis of the upper humerus combined with pulmonary infection, which was complicated with septic shock and respiratory circulatory failure, resulting in MODS. The child died 2 h after surgery.

III. DISCUSSION

Acute hematogenous osteomyelitis develops rapidly, is destructive, and tends to occur in children [1]. Among the 40 patients in this study, 27 were children and adolescents; thus, improper diagnosis and

treatment can have serious adverse consequences. Early diagnosis of acute hematogenous osteomyelitis is critical. Completing WBC, NEUT%, hs-CRP, ESR, and other examinations is conducive to the initial diagnosis and prognosis of acute hematogenous osteomyelitis [13]. In this study, 40 patients had statistically significant changes in WBC, NEUT%, hs-CRP, and ESR before and 2 weeks after surgery [2, 3]. These non-specific examinations were found to be of great value in diagnosing and evaluating the treatment effect of patients. For the treatment of this disease, the diagnosis must be further confirmed by combining imaging examination and the patient's symptoms and signs. In clinical practices, X-ray is the first choice for suspected cases; MRI should be completed when the case is highly suspected. In X-ray examination, acute hematogenous osteomyelitis first showed deep soft tissue swelling [14]. Only when the bone destruction changes reached 50%–75% of the bone density could it be imaged on plain X-ray film [15]. X-rays showed that bone destruction was usually lagging. In the X-ray plain films with more typical manifestations, the lesion might be discovered 10–14 days later [16]. The results of this study showed that the detection rate of soft tissue, bone marrow abnormality, and sensitivity of diagnosing osteomyelitis by X-ray were 40.0%, 50.0%, and 17.5%, respectively, thereby proving that early diagnosis

through X-ray may not necessarily be indicative of the disease. In this study, 40 patients underwent MRI examination before surgery. The detection rate of soft tissue, bone marrow abnormality, and sensitivity of diagnosing osteomyelitis by MRI were 100%, 95.0%, and 95.0%, respectively. These values were significantly better than those of X-ray and CT. MRI could show the condition of early-onset acute osteomyelitis infecting bone marrow and soft tissue lesions [17, 18]. Therefore, in the early diagnosis of disease, MRI was considered to be the main imaging for evaluating osteomyelitis, and it was the preferred imaging technique [3, 17]. For the treatment of acute pyogenic osteomyelitis, the appropriate treatment should be selected as soon as possible; otherwise, the prognosis was poor. In this study, 3 cases had poor efficacy mainly due to poor drainage. Two of them were complicated with chronic osteomyelitis, indicating that adequate drainage and complete focus debridement after surgery were one of the key factors to effectively prevent acute hematogenous osteomyelitis from developing the chronic; one of them was complicated with death mainly due to the failure of early diagnosis and reasonable treatment. The child had been acutely ill for more than 72 h when transferred to our hospital. The child did not improve after symptomatic support and anti-infection treatment but died of septic shock, circulatory failure, and MODS. Given that children have an underdeveloped immune system, poor immunity, acute onset, and rapid progress, they should be actively treated after early diagnosis and operated as soon as possible [1, 11].

Early administration of high-dose sensitive antibiotics is the basis and key in treating acute suppurative osteomyelitis [19]. However, the negative rate of bacterial culture results ranged from 30% to 50% [20, 21]. Even in cases with positive culture results, the pathogenic bacteria may take days to culture and isolate, often delaying the use of the most sensitive antibiotics [22]. Early bacteriological culture of pus collected by local puncture to identify pathogenic bacteria and conduct sensitivity testing may effectively improve the cure rate of the disease and reduce its complications. In this study, 8 of the 10 patients who underwent preoperative puncture showed positive results, with a positive rate of 80%. The collection of pus by preoperative puncture for bacteriological culture and identification was of great significance for guiding the next treatment of the patients. MSSA was the most common pathogen in acute hematogenous osteomyelitis [12], accounting for more than 50% [23]. In this study, the bacterial culture results of 23 out of 40 patients were *S. aureus*, but infections caused by pathogenic bacteria such as *K. pneumoniae* and *E. cloacae* also accounted for a certain proportion. In the empirical administration of antibiotics before the identification of pathogenic bacteria, antibiotics that are

sensitive to MSSA can cover the pathogenic bacteria in most cases, thereby improving the efficacy, greatly reducing the abuse of antibiotics and the production of resistant bacteria, and reducing the waste of medical resources.

Timely surgery was required for focus debridement when the local symptoms could not be controlled after 48–72 h of antibiotic administration or when the local puncture fluid was clearly manifested as bacterial infection combined with systemic acute infection. In this study, all patients were treated with fenestration decompression, focus debridement, and convective flushing with the purpose of completely clearing the focus, draining pus, reducing toxemia symptoms, and preventing acute osteomyelitis from developing into chronic osteomyelitis. Thorough debridement and unobstructed drainage were essential for the successful treatment of osteomyelitis [3]. Fenestration decompression could effectively prevent local inflammation from diffusing under excessive stress; the complete focus debridement shall directly affect the prognosis of the patient; unobstructed postoperative convective flushing was also one of the key factors affecting the prognosis of patients. Three patients exhibited chronic osteomyelitis or their condition worsened due to inadequate drainage 1 week after surgery, which indicated the importance of postoperative drainage for the prognosis of osteomyelitis. In this study, 40 patients underwent fenestration decompression, focus debridement and convective flushing, with a total effective rate of 90%, indicating that timely fenestration decompression, focus debridement, and convective flushing could achieve satisfactory clinical effects on acute hematogenous osteomyelitis when the local symptoms could not be controlled under conservative treatment.

In summary, completing WBC, NEUT%, hs-CRP, ESR, bacteriology, and MRI is of great value in the early diagnosis of acute hematogenous osteomyelitis based on patients' clinical manifestations. Early fenestration decompression, focus debridement, and convective flushing can achieve satisfactory therapeutic effects on acute hematogenous osteomyelitis.

Declaration of Competing Interest

The authors declare that no conflict of interest exists.

ACKNOWLEDGEMENTS

This study was funded by The Project of cultivating Young backbone talents of Ningxia Medical University (No.30230103).

REFERENCES RÉFÉRENCES REFERENCIAS

- Schmitt SK. Osteomyelitis. *Infect Dis Clin N Am.* 2017; 31(2):325-38.
- McBride S, Thurm C, Gouripeddi R, et al. Comparison of Empiric Antibiotics for Acute

- Osteomyelitis in Children. *Hosp Pediatr*. 2018; 8(5):280-7.
3. Lima AL, Oliveira PR, Carvalho VC, Cimerman S, Savio E. Recommendations for the treatment of osteomyelitis. *Braz J Infect Dis*. 2014; 18(5):526-34.
 4. Thakolkaran N, Shetty AK. Acute Hematogenous Osteomyelitis in Children. *Ochsner J*. 2019; 19(2):116-22.
 5. Karmazyn B. Imaging approach to acute hematogenous osteomyelitis in children: an update. *Semin Ultrasound CT MR*. 2010; 31(2):100-6.
 6. Dietrich LN, Reid D, Doo D, Fineberg NS, Khoury JG, Gilbert SR. Predicting MSSA in Acute Hematogenous Osteomyelitis in a Setting With MRSA Prevalence. *J Pediatr Orthop*. 2015; 35(4):426-30.
 7. Lavery LA, Ahn J, Ryan EC, et al. What are the Optimal Cutoff Values for ESR and CRP to Diagnose Osteomyelitis in Patients with Diabetes-related Foot Infections? *Clin Orthop Relat Res*. 2019; 477(7):1594-602.
 8. Lopic I, Padoan A, Bozzato D, Plebani M. Erythrocyte Sedimentation Rate and C-Reactive Protein in Acute Inflammation. *Am J Clin Pathol*. 2020; 153(1):14-29.
 9. Cheng MP, Stenstrom R, Paquette K, et al. Blood Culture Results Before and After Antimicrobial Administration in Patients with Severe Manifestations of Sepsis: A Diagnostic Study. *Ann Intern Med*. 2019; 171(8):547-54.
 10. Grosset AA, Loayza-Vega K, Adam-Granger E, et al. Hematoxylin and Eosin Counterstaining Protocol for Immunohistochemistry Interpretation and Diagnosis. *Appl Immunohistochem Mol Morphol*. 2019; 27(7):558-63.
 11. Lew DP, Waldvogel FA. Osteomyelitis. *Lancet*. 2004; 364(9431):369-79.
 12. Funk SS, Copley LA. Acute Hematogenous Osteomyelitis in Children: Pathogenesis, Diagnosis, and Treatment. *Orthop Clin North Am*. 2017; 48(2):199-208.
 13. Bires AM, Kerr B, George L. Osteomyelitis: an overview of imaging modalities. *Crit Care Nurs Q*. 2015; 38(2):154-64.
 14. Restrepo S, Vargas D, Riascos R, Cuellar H. Musculoskeletal infection imaging: past, present, and future. *Curr Infect Dis Rep*. 2005; 7(5):365-72.
 15. Lazzarini L, Mader JT, Calhoun JH. Osteomyelitis in long bones. *J Bone Joint Surg Am*. 2004; 86(10):2305-18.
 16. Kaim AH, Gross T, von Schulthess GK. Imaging of chronic posttraumatic osteomyelitis. *Eur Radiol*. 2002; 12(5):1193-202.
 17. Miyazaki O, Tanaka T, Aoki H, et al. Acute hematogenous pelvic osteomyelitis: appropriate timing for MRI. *Pediatr Int*. 2020.
 18. Malcius D, Jonkus M, Kuprionis G, et al. The accuracy of different imaging techniques in diagnosis of acute hematogenous osteomyelitis. *Medicina (Kaunas)*. 2009; 45(8):624-31.
 19. Stengel D, Bauwens K, Sehoul J, Ekkernkamp A, Porzolt F. Systematic review and meta-analysis of antibiotic therapy for bone and joint infections. *Lancet Infect Dis*. 2001; 1(3):175-88.
 20. Deshpande SS, Taral N, Modi N, Singrakhia M. Changing epidemiology of neonatal septic arthritis. *J Orthop Surg (Hong Kong)*. 2004; 12(1):10-3.
 21. Saavedra-Lozano J, Mejias A, Ahmad N, et al. Changing trends in acute osteomyelitis in children: impact of methicillin-resistant *Staphylococcus aureus* infections. *J Pediatr Orthop*. 2008; 28(5):569-75.
 22. Agrawal R, Sharma D, Dhiman P, Patro DK. Clinical and haematological predictors of acute hematogenous Methicillin Resistant *Staphylococcus aureus* (MRSA) osteomyelitis & septic arthritis. *J Orthop*. 2015; 12(3):137-41.
 23. Maffulli N, Papalia R, Zampogna B, Torre G, Albo E, Denaro V. The management of osteomyelitis in the adult. *Surgeon*. 2016; 14(6):345-60.

