



GLOBAL JOURNAL OF MEDICAL RESEARCH: F
DISEASES

Volume 20 Issue 8 Version 1.0 Year 2020

Type: Double Blind Peer Reviewed International Research Journal

Publisher: Global Journals Inc. (USA)

Online ISSN: 2249-4618 & Print ISSN: 0975-5888

Pericardial Effusion Caused by Renal Carcinoma of Clear Metastatic Cells: A Rare Cause of Cardiac Tamponade

By Erlon de Avila Carvalho, MD, Marina Varela Braga de Oliveira, MD, Rafael Reis, MD, Isabela Oliveira Campos, MD, Rafael Brito Fontella, MD, Ricardo José Pinheiro Reis Filho, MD & Júlio Rezende de Andrade, MD

Resume- Objective: To report the case of a patient with renal cell carcinoma of the clear cell type with the presence of metastatic disease at diagnosis, affecting the adrenal, lung and pericardium. Evolving with cardiac tamponade and need for urgent surgical intervention, being performed through thoracoscopy, a pericardiectomy for making a pericardial window.

Method: The information was obtained by reviewing the medical record, interviewing the patient, photographic record of the diagnostic methods to which the patient was submitted and literature review.

Final considerations: The reported case brings to light the description of a common clinical condition in medical centers in this case, cardiac tamponade, caused by renal carcinoma of which cardiac metastatic presentation represents a low index, and the need for urgent surgical intervention as an outcome.

Keywords: cardiac tamponade, rcc renal cell carcinoma, clear cell carcinoma, metastasis, pericardiectomy.

GJMR-F Classification: NLMC Code: WP 460



Strictly as per the compliance and regulations of:



© 2020. Erlon de Avila Carvalho, MD, Marina Varela Braga de Oliveira, MD, Rafael Reis, MD, Isabela Oliveira Campos, MD, Rafael Brito Fontella, MD, Ricardo José Pinheiro Reis Filho, MD & Júlio Rezende de Andrade, MD. This is a research/review paper, distributed under the terms of the Creative Commons Attribution-Noncommercial 3.0 Unported License (<http://creativecommons.org/licenses/by-nc/3.0/>), permitting all non-commercial use, distribution, and reproduction in any medium, provided the original work is properly cited.

Pericardial Effusion Caused by Renal Carcinoma of Clear Metastatic Cells: A Rare Cause of Cardiac Tamponade

Erlon de Avila Carvalho, MD ^α, Marina Varela Braga de Oliveira, MD ^σ, Rafael Reis, MD ^ρ, Isabela Oliveira Campos, MD ^ω, Rafael Brito Fontella, MD [¥], Ricardo José Pinheiro Reis Filho, MD [§] & Júlio Rezende de Andrade, MD ^x

Resume- Objective: To report the case of a patient with renal cell carcinoma of the clear cell type with the presence of metastatic disease at diagnosis, affecting the adrenal, lung and pericardium. Evolving with cardiac tamponade and need for urgent surgical intervention, being performed through thoracoscopy, a pericardiectomy for making a pericardial window.

Method: The information was obtained by reviewing the medical record, interviewing the patient, photographic record of the diagnostic methods to which the patient was submitted and literature review.

Final considerations: The reported case brings to light the description of a common clinical condition in medical centers in this case, cardiac tamponade, caused by renal carcinoma of which cardiac metastatic presentation represents a low index, and the need for urgent surgical intervention as an outcome.

Keywords: cardiac tamponade, rcc renal cell carcinoma, clear cell carcinoma, metastasis, pericardiectomy.

I. INTRODUCTION

Kidney cancer makes up 2% to 3% of adult malignancies, with an incidence of 7 to 10 cases per 100,000 inhabitants in the most developed regions of Brazil [123]. In these cases, clear cell carcinoma represents 81%, followed by papillary carcinoma, which is responsible for about 14% of kidney cancer cases [4]. It is estimated that about 16% of patients are diagnosed with metastatic disease [5]. Cardiac and pericardial metastasis is rare [4]. In the period from 1935 to 1998, there were only 131 cases of cardiac tamponade as an initial manifestation of underlying malignancy [6]. In this case, the patient described in this report developed cardiac tamponade, an event that is triggered by a pericardial effusion. It is a condition that needs urgent intervention. Among the

causes, metastatic spread of malignant diseases is an uncommon cause, being clinically silent in most cases [7]. In rarer situations, the clinical presentation can be present, be variable and delay the patient's diagnosis, which is essential to be performed early to reduce morbidity and mortality [8]. We report a case of cardiac tamponade caused by metastasis of a clear cell renal tumor and discussed the symptoms, diagnostic methods and the need for urgent surgical intervention through thoracoscopy, pericardiectomy and making a pericardial window.

II. CASE REPORT

Male patient, 49 years old, admitted to Hospital Alberto Cavalcanti in Belo Horizonte - MG, Brazil, on 04/23/2020 with dyspnea and cough started 6 months ago, associated with weight loss of 5kg. He sought care due to persistence and worsening of symptoms, presenting on admission: orthopnea, paroxysmal nocturnal dyspnea, dyspnea on exertion and cough that was accentuated in the supine position. Without fever, sputum or flu-like symptoms, a previous diagnosis of COPD of undetermined origin had already been made, and heart failure was questioned. During the physical examination, he noticed the presence of a mass in the left hypochondrium and lymph node enlargement in the left cervical chain. Computed tomography of the chest and abdomen showing a mass in the left kidney of 15 cm, suggestive of primary neoplasia. Mediastinal lymph node enlargement, bilateral micro pulmonary nodules and 2.7 cm adrenal mass, suggestive of secondary neoplasia (figure 1)

Author α: Hospital Alberto Cavalcanti /FHEMIG - Belo Horizonte, Minas Gerais State, Brazil, Professor of the Faculty of Medicine of Barbacena, Minas Gerais State, Brazil. e-mail: erlon.avila@gmail.com

Author σ ρ: Hospital Alberto Cavalcanti /FHEMIG - Belo Horizonte, Minas Gerais State, Brazil. e-mails: marina_varela@hotmail.com, reis_fael@yahoo.com.br

Author ω ¥ § χ: Faculdade de Medicina Barbacena, Minas Gerais, Brazil. e-mails: belacampos9@hotmail.com, fontella753@gmail.com, ricardojpreist@gmail.com, Juliora_183@hotmail.com

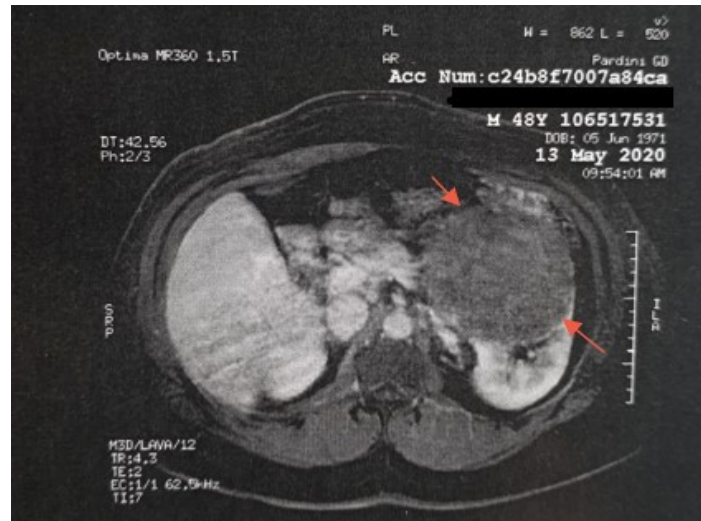


Figure 1: RED ARROW: Delimitation of the left renal tumor

It was evaluated by Oncology with the anatomopathological of the cervical lymph node showing fragments of lymph nodes with atypical epithelial cells, some with clear cytoplasm, forming solid masses and papillary structures infiltrating parenchyma. Immunohistochemistry showed metastatic clear cell carcinoma, a positive study for cytokeratin and diffuse expression for PAX8. The findings favor that the kidney is the site of origin for this metastatic carcinoma.

To rule out heart failure, a transthoracic echocardiogram with preserved systolic and diastolic function and normal BNP was performed. Since 05/17, the patient has presented progressive worsening of the respiratory pattern and refractoriness to clinical treatment. On 05/24, the patient was evaluated in bed, with respiratory worsening, tachycardia, jugular engorgement, paradoxical pulse, pain in the right hypochondrium, orthopnea, auscultation with expiratory wheezing and light crackling. Urgent ultrasound was performed, identifying pericardial effusion and indirect signs of cardiac tamponade (Figure 2). Thoracic surgery was requested to be evaluated due to the patient's

instability, and he was immediately referred for a surgical approach, where thoracoscopy was performed. 10 cm incision in the region of the 6th left intercostal space with 10mm trocars and 30mm optic passages within the left hemithorax inventory. Engorged pericardial effusion was identified with subsequent opening of the pericardium with a Hook cautery pen and elimination of bloody liquid (Figure 3). Pericardial window and pericardiectomy of about 2 cm² were performed (Figure 4). Approximately 200ml of hematic pericardial content was aspirated, and there was an instant improvement in hemodynamic parameters. Pericardial material and pericardial implant were collected for biopsy. Finally, water seal pleural drainage was performed. Anatomopathological examination of the pericardial biopsy confirmed metastatic implantation. There were no complications in the postoperative period, a chest tube was removed on the 12th postoperative day, and the patient was discharged on 06/16/2020, referred to the clinical oncology clinic for therapeutic follow-up.

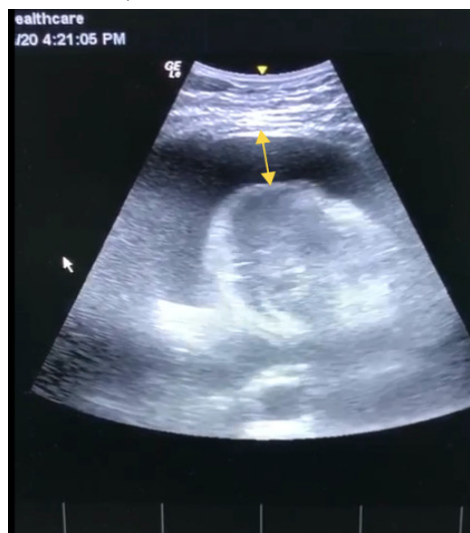

Figure 2: Yellow Arrow: Pericardial Effusion



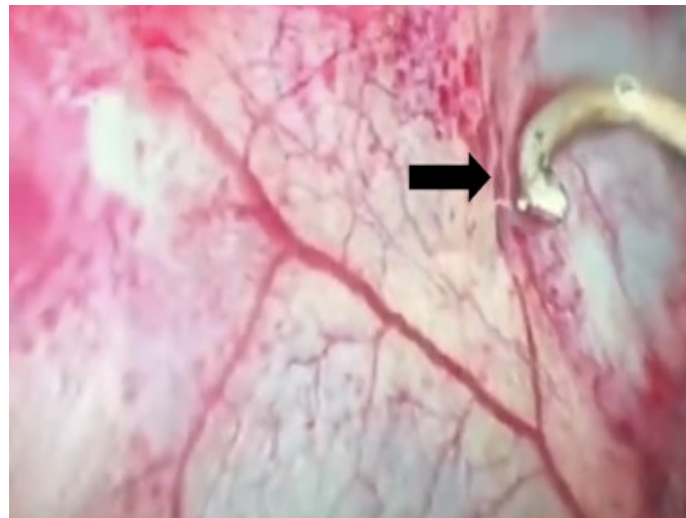


Figure 3: Black Arrow: HOOK forceps in contact with pericardial membrane

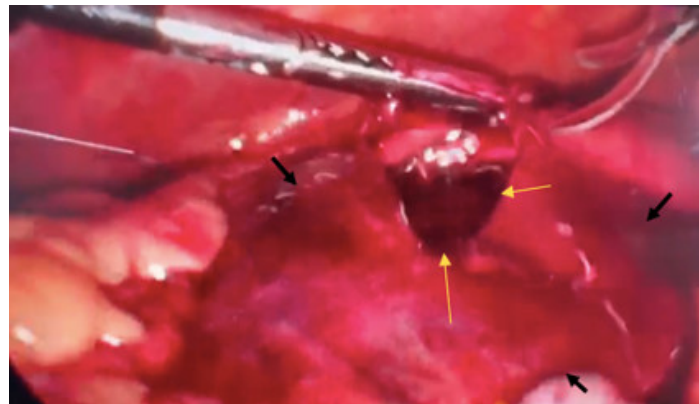


Figure 4: BLACK ARROW: Pericardial sac YELLOW ARROW: Pericardial window

III. DISCUSSION

Malignant tumors represent 32% of the causes of cardiac tamponade [9]. Pericardial metastases have been reported in 15.4% of cases of malignant autopsied tumors, but most are asymptomatic and rarely cause clinical repercussions [10]. According to Oliver et al. [11], the main primary malignant tumors with pericardial metastasis are lung cancer 36.5%, breast cancer 22.3%, leukemia and malignant lymphoma 17.2% and renal cancer 1.9%. As a metastatic route for pericardial metastases, it is speculated that it is done by retrograde lymphatic transit [12].

In the period from 1935 to 1998, there were only 131 cases of cardiac tamponade as an initial manifestation of underlying malignancy. The main primary cancers causing effusion were: lung (52 cases), lymphomas and leukemias (17 and 19 cases respectively). Only one case of renal cell cancer was reported during this period [6]. A study carried out between January 1, 1999 and January 31, 2003 evaluated 219 patients with pericardial effusion, 96 patients had the disease related to malignancy, only one positive case for renal cell cytology (table 1). [13]



Table 1: Underlying Malignancy among 96 Patients with Cancer-Related Pericardial Effusion

Site	Patients	
	No.	%
Lung	33	34.4
Breast	16	16.7
Leukemia/myelodysplastic syndrome	9	9.4
Cancer of unknown primary	8	8.3
Esophagus	5	5.2
Sarcoma	5	5.2
Mesothelioma	4	4.2
Lymphoma/lymphoproliferative disorder	4	4.2
Colorectal	4	4.2
Other*	8	8.3
Total	96	100.0

*Other malignancies: cervical (2), head/neck, eccrine gland, nerve sheath, ovarian, prostate, renal cell. [8]

The frequency of cardiac tamponade as the initial manifestation of malignant effusion is highly variable and depends on the rate of fluid accumulation, fluid volume and underlying cardiac function. The pericardium can be stretched for a period to accommodate a large volume of fluid before the clinical appearance of the tamponade. The signs and symptoms of cardiac tamponade include dyspnea, orthopnea, low output (peripheral vasoconstriction, cold and wet extremities, poor capillary filling and diaphoresis), jugular venous distention, muffled heart sounds, paradoxical pulse and reduced pulse pressure. Even with cancerous pericarditis, in the case of kidney cancer, performing pericardiocentesis not only reduces symptoms, improving heart failure, but also prolongs the period of survival. The median overall survival of patients with malignant pericardial effusion is less than 6 months [14].

In the present case report, we narrate a case of clear cell renal cell carcinoma, the first symptoms presented by the patient were cough and dyspnea, although the first echocardiogram did not show significant changes and the patient had a previous COPD to clarify, the treatment established for COPD and HF were not effective. The symptoms presumably were due to the ongoing pericardial effusion. One week after CT showing bilateral pleural effusion and small pericardial effusion, with the exacerbation of cardiac symptoms, ultrasound at the bedside was performed, which showed an important pericardial effusion with cardiac tamponade.

Videoracoscopy and pericardiectomy were indicated by the surgical team. Videothoracoscopy was chosen because it is less invasive than open thoracotomy, the pericardial approach through electrocauterization could be performed by a previous study via POCUS, better viewed in the lower left parasternal window. Approximately 550 ml of hematic pericardial content was aspirated, with instant improvement in hemodynamic parameters.

Although simple pericardiocentesis can save lives in cases of cardiac tamponade, this procedure alone is rarely an adequate therapy due to the high rate of fluid buildup. To avoid recurrence, the patient received immunotherapeutic treatment and pericardiectomy was performed against urgent pericardiocentesis, provided by the shunt in the pericardial window in the case confirmed by the pathology of clear renal cell metastasis. Clear cell renal cell carcinoma that presents as cardiac tamponade is rare in the literature. The case also emphasizes the importance of a complete review of the history, physical examination and complementary examination, in addition to exposing the need to perform a resolute surgical procedure.

REFERENCES RÉFÉRENCES REFERENCIAS

1. Wünsch-Filho, V. (2002). Insights on diagnosis, prognosis and screening of renal cell carcinoma. *Sao Paulo Medical Journal*, 120(6), 163-164.
2. Barbosa, G. D. S., Lima, R. D., & Guimarães, R. M. (2012). Série histórica de mortalidade por neoplasias renais no Brasil (1996-2010). *Cadernos Saúde Coletiva*, 20(4), 537-540.
3. Bao, C., Yang, X., Xu, W., Luo, H., Xu, Z., Su, C., & Qi, X. (2013). Diabetes mellitus and incidence and mortality of kidney cancer: a meta-analysis. *Journal of diabetes and its complications*, 27(4), 357-364.
4. Leibovich, B. C., Lohse, C. M., Crispen, P. L., Boorjian, S. A., Thompson, R. H., Blute, M. L., & Chevillet, J. C. (2010). Histological subtype is an independent predictor of outcome for patients with renal cell carcinoma. *The Journal of urology*, 183(4), 1309-1316.
5. Alghamdi, A., & Tam, J. (2006). Cardiac metastasis from a renal cell carcinoma. *Canadian Journal of Cardiology*, 22 (14), 1231-1232.
6. Islam, N., & Ahmedani, M. Y. (1998). Renal carcinoma presenting as cardiac tamponade: a

- case report and review of literature. *International journal of cardiology*, 64(2), 207-211.
7. Hattori, S., Miyajima, A., Maeda, T., Takeda, T., Morita, S., Kosaka, T.,... & Oya, M. (2012). Metastatic urothelial carcinoma to pericardium manifested by dyspnea from cardiac tamponade during systemic chemotherapy: case report and literature review. *Canadian Urological Association Journal*, 6(5), E184.
 8. Refaat, M. M., & Katz, W. E. (2011). Neoplastic pericardial effusion. *Clinical cardiology*, 34(10), 593-598.
 9. Guberman, B. A., Fowler, N. O., Engel, P. J., Gueron, M., & Allen, J. M. (1981). Cardiac tamponade in medical patients. *Circulation*, 64(3), 633-640.
 10. Ueda, N., Arai, Y., Matsuzaki, K., Yamamoto, Y., Takeda, K., Nakata, W., ... & Nishimura, K. (2012). Cardiac tamponade due to pericardial metastasis from renal cell carcinoma: a case report. *Hinyokikakiyo. Acta urologica Japonica*, 58(9), 491-494.
 11. Press, O. W., & Livingston, R. (1987). Management of malignant pericardial effusion and tamponade. *JAMA*, 257(8), 1088-1092.
 12. Fraser, R. S., Vilorio, J. B., & Wang, N. S. (1980). Cardiac tamponade as a presentation of extracardiac malignancy. *Cancer*, 45(7), 1697-1704.
 13. Gornik, H. L., Gerhard-Herman, M., & Beckman, J. A. (2005). Abnormal cytology predicts poor prognosis in cancer patients with pericardial effusion. *Journal of clinical oncology*, 23(22), 5211-5216.
 14. DeVita Junior, V., Hellman, S., & Rosenberg, S. A. (2001). *Cancer: principles and practice of oncology*. In *Cancer: principles and practice of Oncology* (pp. 1518-1518).

