



GLOBAL JOURNAL OF MEDICAL RESEARCH: J
DENTISTRY & OTOLARYNGOLOGY
Volume 21 Issue 1 Version 1.0 Year 2021
Type: Double Blind Peer Reviewed International Research Journal
Publisher: Global Journals
Online ISSN: 2249-4618 & Print ISSN: 0975-5888

Immediate Functional Loading - Evaluation of Bi-Cortical Screw Implants

By Dunkudu Nikhil, Gaddipati Rajasekhar, G.V.S. Sudhakar,
Ramishetty Sudhir & Beeram Ratna Kumari

Abstract- Bi-cortical screw implant (BCS) also known as strategic implant, is contemporary implantology system which is uniquely made to utilize the cortical bone of jaws. The aim of the study was to analyze osseo-fixed immediately loaded basal implants and also to determine patient satisfaction. Not even a single patient was rejected neither for “lack of the bone” (all kinds of bone atrophy and trauma to the jaw which damages not only the teeth but also the alveolar bone) nor for “many diseases are carried”. All the patients were immediately restored with interim prosthesis within three hours and replaced with functional loading fixed prosthesis within seven days after bending up to 15 degrees of Implant abutment. Basal Cortical Screw (BCS) implant is a definitive option for the rehabilitation of missing teeth of patients regardless of the available alveolar bone without additional augmentation (grafts) procedures. Immediate functional loading using Osseo-fixed BCS implants shows a high implant survival rate without any infection; 'Peri-implantitis' and have a positive impact on oral health and highly increased patient satisfaction.

Keywords: immediate functional loading, Bi-cortical screw implant (BCS), Osseo-fixation, basal implantology, bendable implants.

GJMR-J Classification: NLMC Code: WU 640



Strictly as per the compliance and regulations of:



© 2021. Dunkudu Nikhil, Gaddipati Rajasekhar, G.V.S. Sudhakar, Ramishetty Sudhir & Beeram Ratna Kumari. This is a research/review paper, distributed under the terms of the Creative Commons Attribution-Noncommercial 3.0 Unported License <http://creativecommons.org/licenses/by-nc/3.0/>), permitting all non-commercial use, distribution, and reproduction in any medium, provided the original work is properly cited.

Immediate Functional Loading - Evaluation of Bi-Cortical Screw Implants

Dunkudu Nikhil ^α, Gaddipati Rajasekhara ^ο, G.V.S. Sudhakar ^ρ, Ramishetty Sudhir ^ω
& Beeram Ratna Kumari [¥]

Abstract- Bi-cortical screw implant (BCS) also known as strategic implant, is contemporary implantology system which is uniquely made to utilize the cortical bone of jaws. The aim of the study was to analyze osseo-fixed immediately loaded basal implants and also to determine patient satisfaction. Not even a single patient was rejected neither for "lack of the bone" (all kinds of bone atrophy and trauma to the jaw which damages not only the teeth but also the alveolar bone) nor for "many diseases are carried". All the patients were immediately restored with interim prosthesis within three hours and replaced with functional loading fixed prosthesis within seven days after bending up to 15 degrees of Implant abutment. Basal Cortical Screw (BCS) implant is a definitive option for the rehabilitation of missing teeth of patients regardless of the available alveolar bone without additional augmentation (grafts) procedures. Immediate functional loading using Osseo-fixed BCS implants shows a high implant survival rate without any infection; 'Peri-implantitis' and have a positive impact on oral health and highly increased patient satisfaction.

Keywords: immediate functional loading, Bi-cortical screw implant (BCS), Osseo-fixation, basal implantology, bendable implants.

I. INTRODUCTION

Bi-cortical screw implant also known as strategic implant is a contemporary implantology system that is uniquely made to utilize the cortical bone of jaws for the retention of dental implants¹.

Nowadays, patients desire to eliminate waiting periods and multiple appointments, discomfort associated with basic dental implantology. Bi-cortical screw implants provide fixed prosthesis in a short duration of time within seven days of implant placement and avoid healing periods associated with conventional implantology.

The theory behind the Strategic implants (bi-cortical implantology) is similar to the treatment concepts performed during osteosynthesis, maxillofacial traumatology, and Orthopedic surgery. The Bi-cortical

screw (BCS) implants are placed cortically, and the process to initiate this anchorage has been referred to as Osseo-fixation. Secondary Osseointegration occurs through the vertical shaft of the implants, and is expected to happen in any case later².

As BCS implants gain anchorage by utilizing the cortical bone of the Mandible, wall of the Sinus, Nasal floor and the tubero-ptyergoid region³ (Figure.2&3), a thorough knowledge of maxillofacial anatomy is needed for implant placement. These anatomic structures facilitate placement of BCS implants regardless of the type of alveolar bone, because they do not require any bone graft and bone augmentation procedures.

The success of the BCS implants depends on the macro-mechanic anchorage (Osseo-fixation) in the 2nd or 3rd cortical and secondary stability come after Osseointegration.

Bending areas in the vertical shaft of bi-cortical screw implants was first introduced by Dr. Stefan Idhe. Bending of implants can align abutment in the desired direction for placement of prosthesis and also exhibits more even stress dissemination along the implant shaft region than a machine-angulated implant abutment. Therefore, bendable abutment of BCS implants resists masticatory forces greater than pre angulated or straight implant abutment⁴.

II. TYPE OF BASAL IMPLANTS

1. BOI (Basal Osseo-Integrated Implant) (Figure.1)
2. BCS (Bi-Cortical Screw Implant) (Figure.1)

These two types of basal implants can be differentiated by not only having self cutting threads in BCS, but also by the way how they are placed. Immediate functional loading on single- piece implants had gained demand and accepted treatment option for fixed restorations of missing teeth⁵.

These uniquely designed BCS implants have self-cutting threads, the smooth surface vertical shaft of BCS implants create a non-infectable connection with the prosthesis and prevent peri-implantitis.

BCS implants have proven to be successful for patients even in lack of alveolar bone (limiting treatment) so there is no rejection in treatment of implant placement in such patients.

Corresponding Author α: Department of oral and maxillofacial surgery, Mamata dental college and hospital, Khammam, Giriprasad nagar, PIN CODE: 507002, Telangana (state), India.
e-mail: nikhil777dad@gmail.com

Author α ρ ω ¥: Department of oral and maxillofacial surgery, Mamata dental college and hospital, Khammam, Giriprasad nagar, PIN CODE: 507002, Telangana (state), India.

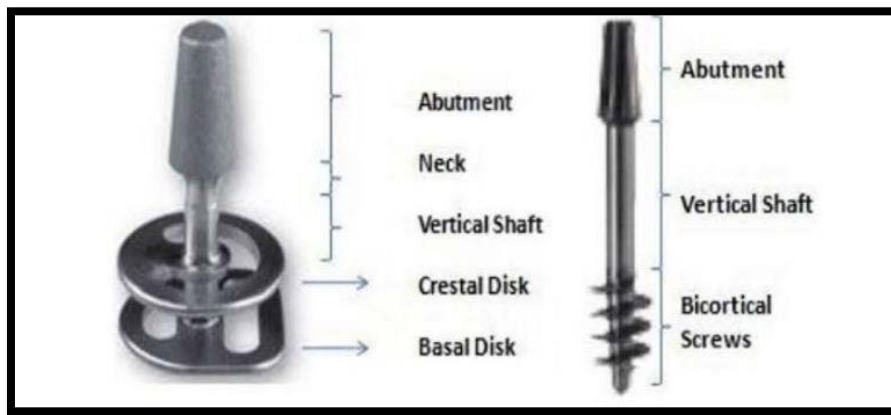


Figure 1: Schematic overview of types of basal implants

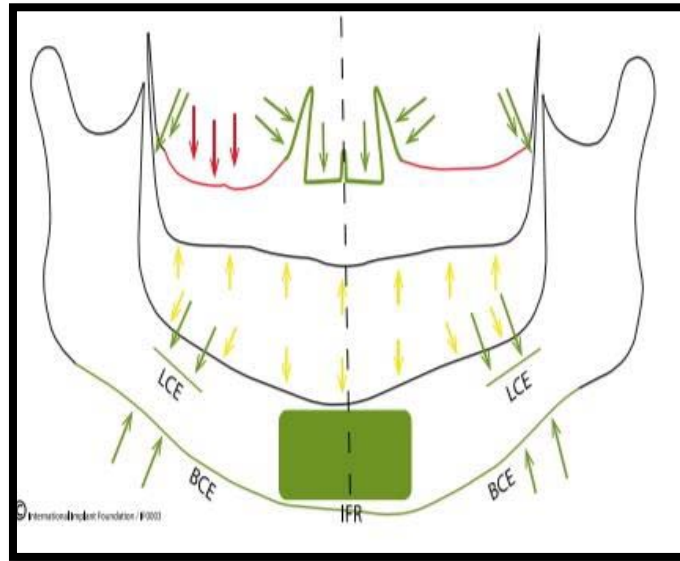


Figure 2: Schematic overview on the corticals for anchorage in the maxilla and mandible

Yellow: 1st cortical, Green arrows in mandible mark 2nd cortical.

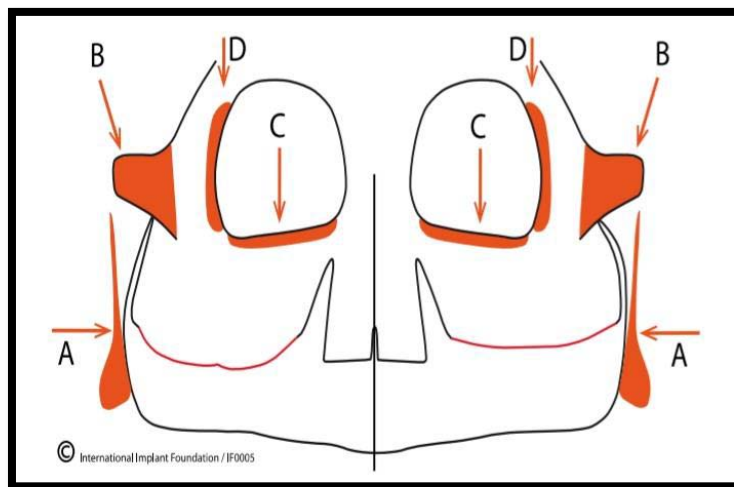


Figure 3: Schematic overview on cortical in the midface available for oral implant anchorage. Red: 3rd cortical A: Pterygoid plate of the sphenoid bone. B: Body of the zygomatic bone. C: Infra-orbital rim. These areas are used in cases with defects in the midface. D: Lateral vestibular rim of the orbital: This region may be used for epithesis anchorage, especially for eye replacement

III. AIM OF THE STUDY

The study was aimed to analyze clinically and radiographically for six months of Osseo-fixed immediately loaded basal implants and also to determine the patient satisfaction for these basal cortical screw implants.

IV. MATERIALS AND METHODS

A prospective cohort study was conducted on fifteen basal Bi-Cortical Screw Implants placed in ten adult patients in the department of oral and maxillofacial surgery, Mamata Dental College and Hospital, Khammam, Telangana between 2019-2020. Ethical clearance was obtained and all patients were informed about the implant placement procedure, and informed consent was taken from patients participating in the study.

a) Inclusion and Exclusion Criteria

Not even a single patient was rejected neither for "lack of the bone" (i.e.) All kinds of bone atrophy and trauma to the jaw, which damages not only the teeth but also the alveolar bone nor for "any diseases (i.e, the untreated periodontal disease, especially in people with diabetics will resorb the available bone and hypertension) that they carried." Expect patients on current Radiotherapy (or) chemotherapy and IV-bisphosphonate treatment.

b) Surgical Technique

BCS implants have a different surgical technique that is easy and simple to execute. Under all aseptic conditions, implants were placed in the extraction sockets and edentulous bone site (depending on implant site needed). Using a pilot pathfinder drill and a manual drill, a controlled osteotomy was prepared till second cortical bone was reached which was adequate for Osseo-fixation of implant. The implants were then placed in place, where the abutment threads were parallelized through bending up to 15 degrees of implant abutment.

c) Post-operative criteria for evaluation of basal cortical Screw implants

1. Evaluation of the time duration to give prosthesis.
2. Pain -Visual along the scale (1-10).
3. Primary implant stability /mobility of Implant-Absent/present (A/P). *
4. Infection/periapical radiolucency- Absent/present (A/P). *
5. Radiographic successful Implant- IOPA, orthopantomogram (OPG).
6. Patient Satisfaction-Grade (1 to 4).

The following observations were drawn on x-rays

- The radiographic observation for formation of the bone sockets containing implants.

- The marginal bone levels of the implants were measured mesial and distal on the IOPA.
- Place of insertion in the target cortical (i.e, second Cortical) on orthopantomogram.

d) Results

Results have been described in Table 1-2 and Graphs 1-6.

All patients were clinically and radiographically followed-up for six months. In a total of 15 Bi-cortical screw implants 14 of 3.6mm and 1 of 4.6 mm in diameter with 6 of 20mm, 1 of 12mm, 4 of 17mm, 3 of 23mm in length were placed in mandible and maxilla. (Table 1)

Interim prosthesis was restored in all the patients immediately within three hours post-operatively with only 3 implants were restored after 24 hours and replaced with functional loading fixed prosthesis within seven days after Implant placement.

The loading time varied between patients due to their unavailability at certain times with a mean variation of 10 days with a standard deviation (SD) of 7.36 days. (Graph1).

The pain had maximum pain on day one (mean value of 1) and decreased significantly finally no pain (mean value of 0) follow-up period with Friedman's test of P-value 0.0, which is statistically not significant (NS). (Graph 2)

Primary stability and periapical radiolucency had been absent in 15 of 15 implants placed during the study period. (Table 2)

Around the region of self-cutting threads of implant radiolucency was not seen. The bone loss is seen around the vertical shaft of the BCS implants but is insignificant as there is no role for Osseo-Integration in basal implantology as it is Osseo-fixed. Near to 100 percent bone formation was established around the vertical shaft at the end of six months follow-up (Graph 3).

The dual process of healing around the BCS Implant by Osseo-Integration happening in any case later (a process that takes part approximately after weeks) the mean marginal bone loss around the implants is measured at the end of six months after implant placement with the mean value 0.04mm on mesial and 0.05mm distal side of Implant of P-value 0.164 (NS) and 0.290 (NS) on mesial and distally which statistical not significant (NS) indicating no 'peri-implantitis' by using ANOVA one-way test of statistical analysis. (Graph 4,5).

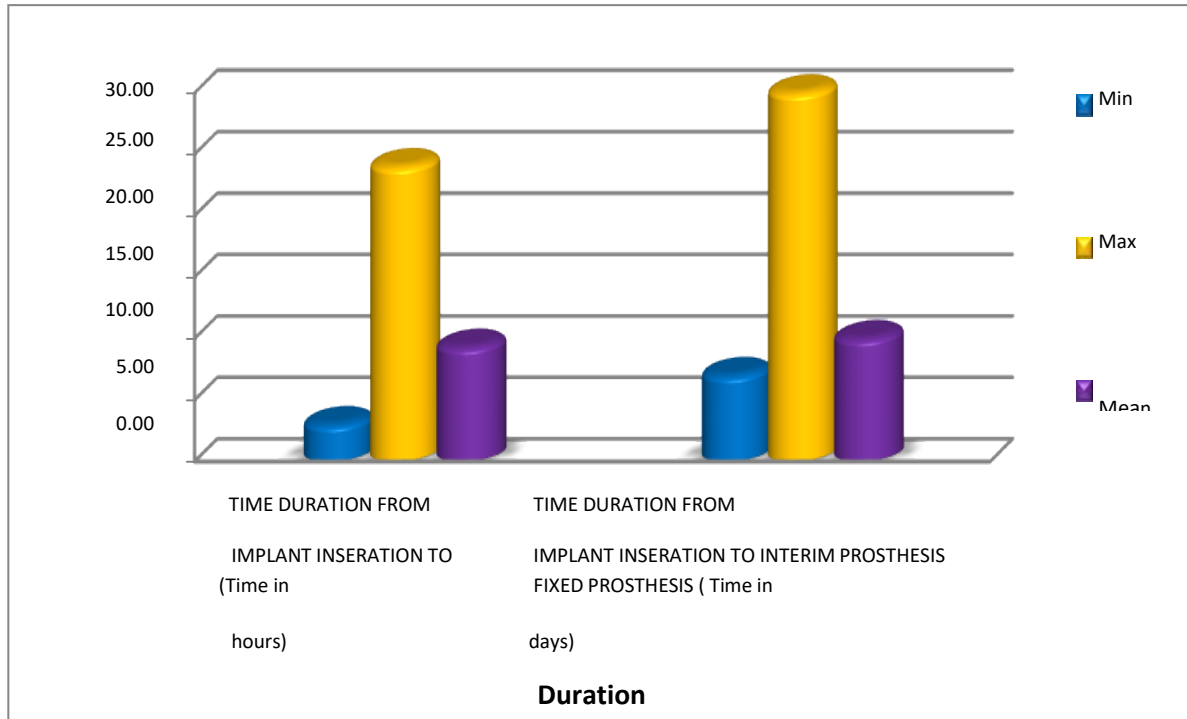
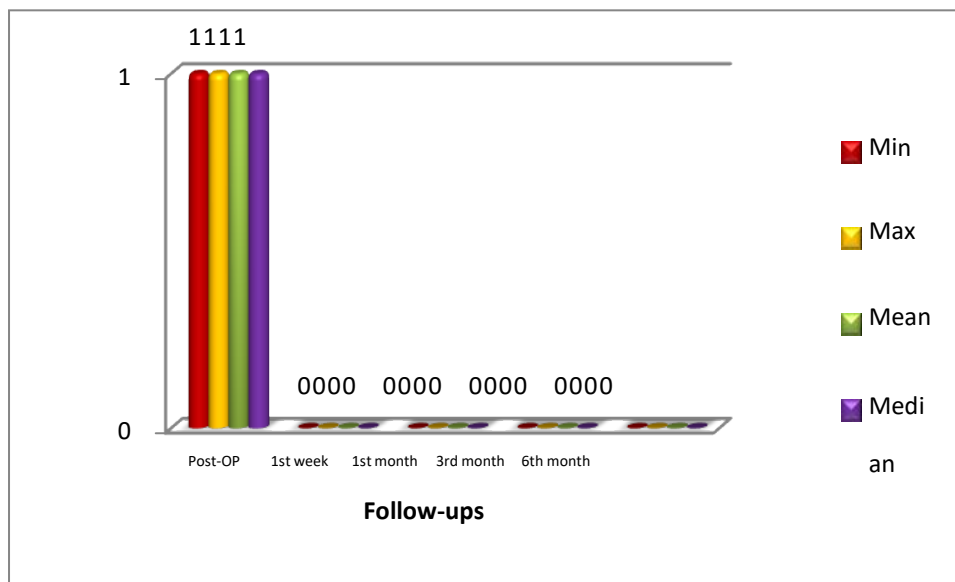
Overall, patient's satisfaction with implant placement was good and satisfied with the mean value 1.10 and standard deviation (SD) of 0.32 (Graph 6).

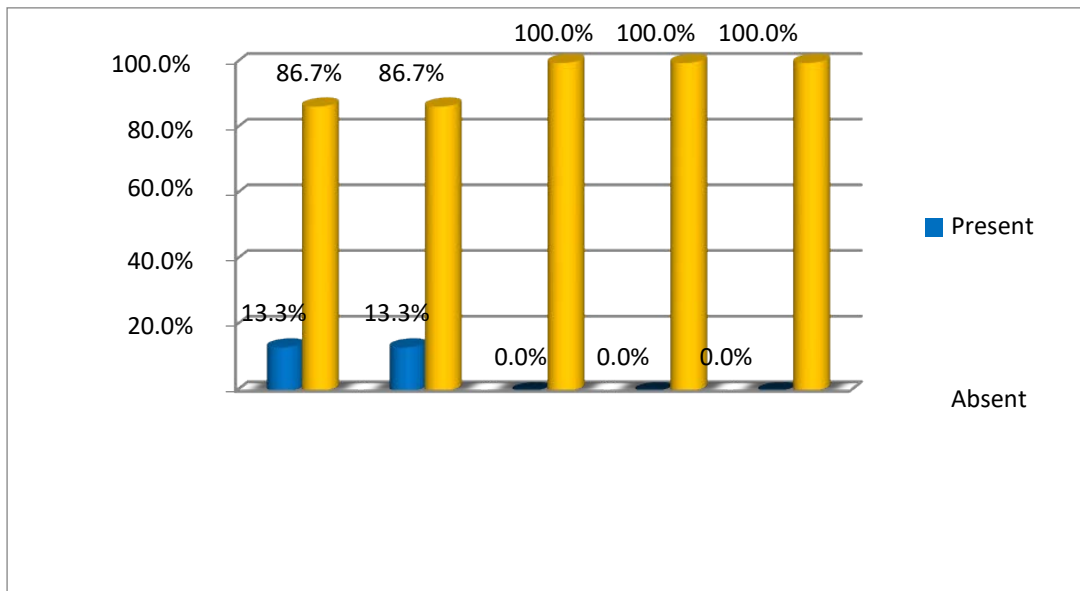
Table 1: Place of Osseo-fixation of implants placed within this study

Place of Osseo-fixation in the second cortical	Implants(n) %
Nasal floor	9 (60%)
Palatine bone and wall of sinus	1 (6.6%)
Mandible interforaminal anchorage	5 (33.3%)

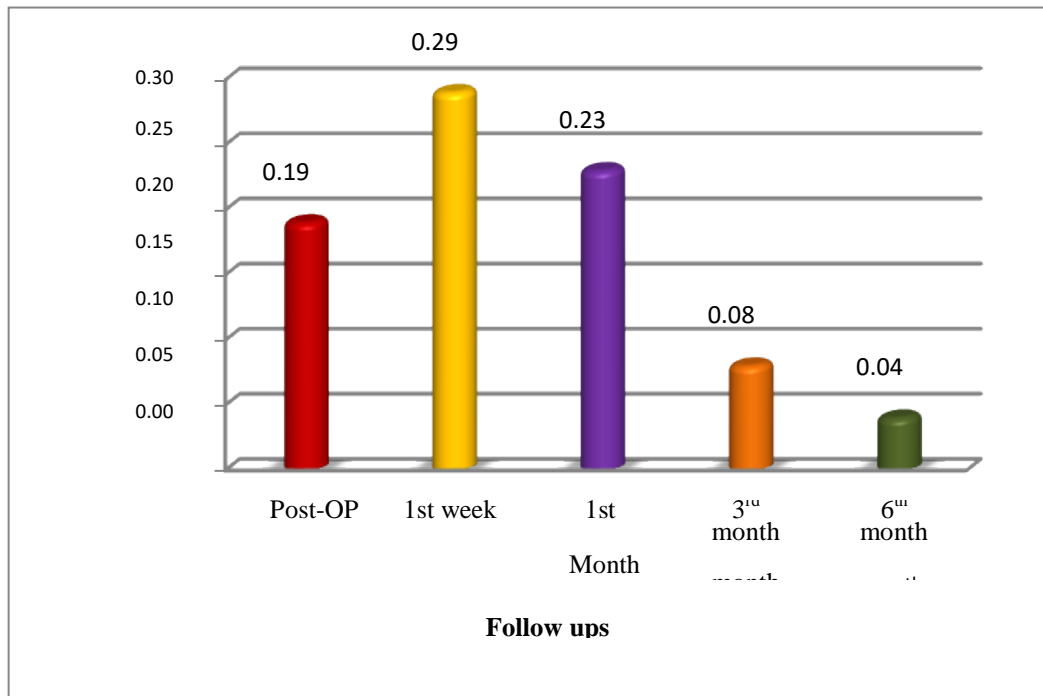
Table 2: Postoperative follow-up

Parameters	Absent/Present	Implants(n) %
Primary stability/mobility of implant	Absent	15 (100%)
Infection/periapical radiolucency	Absent	15 (100%)

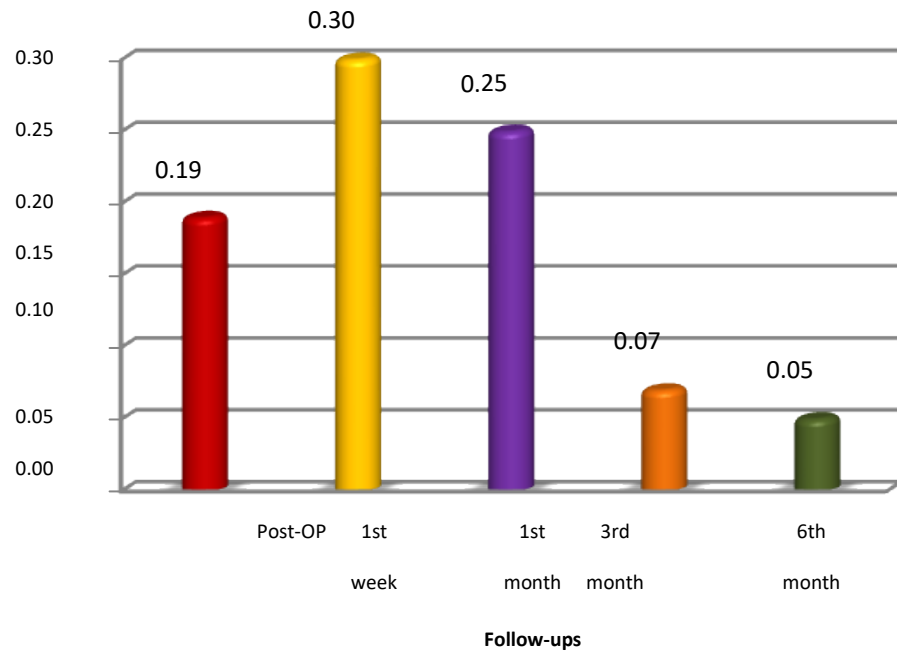
*Graph 1:* Duration of prosthesis restored.*Graph 2:* Pain (VAS) score at different periods of follow ups



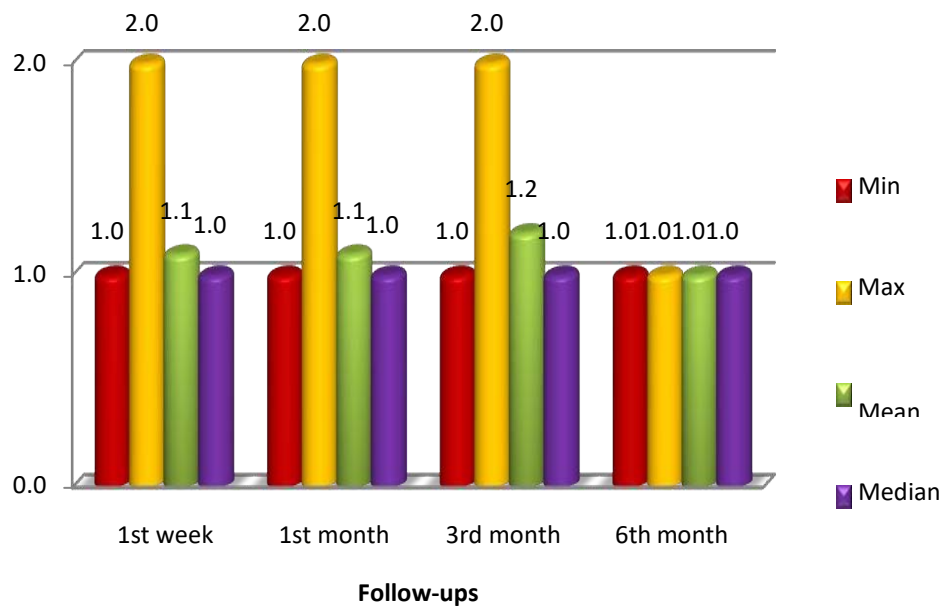
Graph 3: Peri-implant radiolucency



Graph 4: Marginal bone levels (in mm) at Mesial side

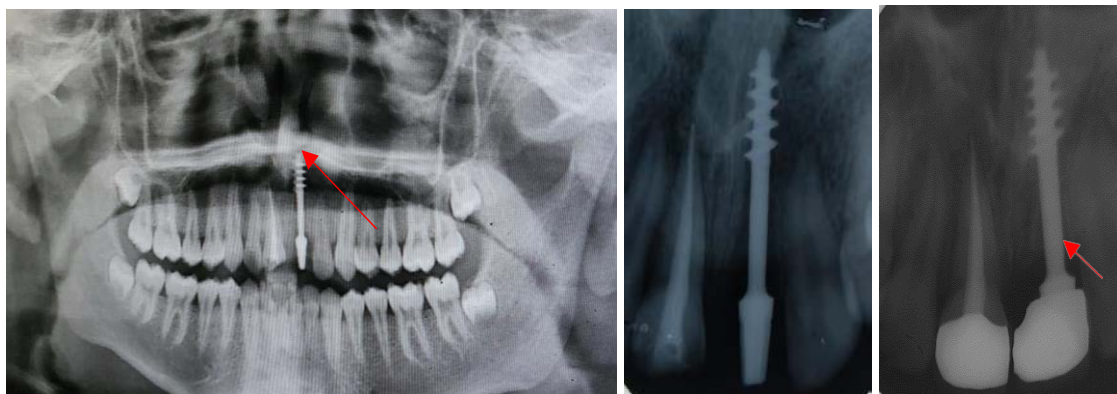


Graph 5: Marginal bone levels (in mm) at Distal side



Graph 6: Patient satisfaction at follow ups

ON X - RAYS



Target cortical fixation of BCS implant (OPG)

Formation of bone after 6 months (IOPA)

V. DISCUSSION

Over the past decades, two different techniques were developed regarding the implantology (i.e, conventional dental implantology and Bicortical-basal Implantology both techniques) work on different principles by Osseo-Integration and later by Osseofixation in a stable cortical bone⁶.

Cortical Implantology, similar to the concepts of orthopedics and traumatology principles used in fracture treatment with the plates and screws are bicortical engagement with screws and immediate splinting of screws with plate and early functional mobilization. Similar in cortical Implantology BCS implants are engaged in cortical bones. They are splinted with immediate loaded fixed prosthesis. In our study, according to these concepts, Basal screw implants are immediately loaded with fixed prosthesis within seven days of Implant placement, save time and cost considerably⁷.

In conventional implantology, the amount of alveolar bone height and width is essential. In Bicortical implantology availability of cortical bone 2nd cortical is important where Implant is Osseo-fixed⁴.

Neither patient selection was made regarding the available alveolar bone height and width at all it must be pointed out, that all patients were treated due to "lack of the bone", nor were any, additional augmentation surgical procedures performed.

In our present study, surgical procedure was invasive not associated with post-operative swelling and healing was rapid and often additional surgical risks and complications were reduced.

The two factors that establish the success of immediately functional loaded implants is the proper Osseofixation into the cortical bone with good implant primary stability and prevention of overloading at the interface of the bone-implant during six months of the bone healing⁸.

Clinically lack of mobility implant does not always coincide with bone-implant interface. However,

when clinically noticed, lack of implant mobility usually means that at least implant portion is direct contact (Osseo-fixed) with bone, although the percentage of bone contact cannot be specified⁹.

In the present study, nearly 100% of bone levels were attained at the end of the follow-up period. This increased bone levels is due to the special dual process of healing around the BCS Implants by Osseofixation.

Grandi et al, concluded that if high primary stability is present during the implant placement immediately functional loading implants had the same success rate with delayed loading¹⁰.

In the present study, there was no mobility of implants during the follow-up period, and primary stability achieved was similar to the study done by Ihde and Palka on BCS implants which had no mobility after two years follow-up.

Specific conventional implant surfaces are assumed to be better than other in the concept of Osseofixation as the assumption that some specific implant surface works better than polished smooth surface Titanium is not justified by science⁶.

Similarly, specific implant surface has no importance for the faster Osseofixation of the implant. Hence BCS implants are immediately functional loaded with prosthesis utilizing cortical for Osseofixation in the concept of the Bicortical-basal implantology instead of waiting towards Osseofixation.

BCS Implants have an advantage is associated with thin and smooth polished implant surface makes it effectively difficult for bacterial establishment and migration along the implant portion in 2nd cortical. The mechanical masticatory forces hit the bone away from the crestal bone (i.e, 1st cortical the zone of bacterial attack). Such implants show no pockets around the mucosal penetration areas, nor has predictable vertical bone loss ever been described for these Implant designs¹¹.

The present study results were also in accordance with the study conducted by Aleksandra Lazarov (2019), where in the study period of 12-57 months and 5100 implants were placed, proclaim that signs of peri-implantitis was not establish around BCS Implants at all¹².

The BCS Implants appear to be resistant and avoid 'peri-implantitis' most prevalent problem related to two-piece implantology and foremost to implant failure.

Basal Cortical Screw (BCS) implants, is a definitive option for the rehabilitation of missing teeth of patients with regardless of the available alveolar bone without additional augmentation (grafts) procedures. Immediate functional loading using Osseo-fixed BCS implants shows a high implant survival rate without any infection, 'Peri-implantitis' and have a positive impact on oral health and highly increase patient satisfaction.

Hence it can be concluded that however the conventional implantology contraindications for implant placement do not apply for Bi-cortical Screw basal implantology.

Advantage of study

1. Rehabilitation of missing tooth within minimal time frame with fixed prosthesis.
2. Minimal cost (no graft's) with Osseo-fixed cortically by simple surgical technique.

Limitation of the study

Longer follow-up and further studies including an increased number of patients, are needed to assess the long-term success of BCS Implants.

REFERENCES RÉFÉRENCES REFERENCIAS

1. Yadav RS, Sangur R, et al. An alternative to conventional dental implants: Basal implants. Rama Univ J Dent Sci 2015; 2:22-8.
2. Ihde S. Indications and treatment modalities with corticobasal jaw implants. Ann Maxillofac Surg 2019; 9:379-86.
3. Ihde et al. New Systematic Terminology of Cortical Bone Areas for Osseo-Fixated Implants in Strategic Oral Implantology. J J Anatomy. 2016, 1(2): 007.
4. Goldmann t, ihde s, kuzelka j, himmlova I. Bendable vs. Angulated dental implants: consideration of elastic and plastic material properties based on experimental implant material data and fea. Biomed papmed fac univ palacky olomouc czech repub. 2008; 152:309-16.
5. Sohaib syed aleemuddin shahed et al. Basal implants: a breakthrough for atrophic ridges. journal of applied dental and medical sciences 4(1), 20187.
6. Ihde S, Sipic O. Functional and esthetic indication for dental implant treatment and immediate loading (2) Case report and considerations: Typical attitudes of dentists (and their unions) toward tooth

- extractions and the prevention of early, effective, and helpful dental implant treatment in the European union. Ann Maxillofac Surg 2019; 9:470-4.
7. Dr. KS Manjunath et al. International Journal of Applied Dental Sciences 2020; IJADS 2020; 6(3): 411-414
8. Oleg D, Alexander L, Vitomir KS, et al. Immediate-functional loading concept with one-piece implants (BECES/BECES N /KOS/ BOI) in the mandible and maxilla- a multi-center retrospective clinical study. J. Evolution Med. Dent. Sci. 2019;8(05):306-315, DOI: 10.14260/jemds/2019/67
9. Ihde s. Principles of BOI Heidelberg/Germany: springer 2005:27
10. Tommaso Grandi et al. Survival and Success Rates of Immediately and Early Loaded Implants: 12-Month Results From a Multicentric Randomized Clinical Study, DOI: 10.1563/AAID-JOI-D-10-00149
11. Parel and Schow. One-Piece Implant System in Single Tooth Sites. J Oral Maxillofac Surg 2005. DOI:10.1016/j.joms.2005.05.150
12. Lazarov A. Immediate functional loading: Results for the concept of the strategic implant®. Ann Maxillofac Surg 2019; 9:78-88. DOI: 10.4103/ams.ams_250_18