



GLOBAL JOURNAL OF MEDICAL RESEARCH: H
ORTHOPEDIC AND MUSCULOSKELETAL SYSTEM
Volume 21 Issue 2 Version 1.0 Year 2021
Type: Double Blind Peer Reviewed International Research Journal
Publisher: Global Journals Inc. (USA)
Online ISSN: 2249-4618 & Print ISSN: 0975-5888

Acrometastasis: A Rare Entity. A Proximal Radius Case

By Holgado-Moreno Esperanza, Cabezuelo-Díaz-Miguel Eduardo,
Sánchez-Sánchez Félix, Alarma-Barcia Leticia & Guijarro-Leo Sandra

Abstract- Bone metastases under de knee and elbow (acrometastasis) are rare. We present the case of a patient diagnosed with lung adenocarcinoma, with a lesion in the right proximal radius. Radiological imaging through CT and MR suggested metastatic lesion, which anatomopathological results confirmed. As the presence of these markers provides a poor outlook, radiotherapy was initially considered. However, given the clinical stability of the patient and the limited amelioration observed, surgical treatment was finally conducted.

Keywords: *acrometastasis, lung, radio, surgery.*

GJMR-H Classification: *NLMC Code: WE 168*



Strictly as per the compliance and regulations of:



© 2021. Holgado-Moreno Esperanza, Cabezuelo-Díaz-Miguel Eduardo, Sánchez-Sánchez Félix, Alarma-Barcia Leticia & Guijarro-Leo Sandra. This research/review article is distributed under the terms of the Attribution-NonCommercial-NoDerivatives 4.0 International (CC BY-NC-ND 4.0). You must give appropriate credit to authors and reference this article if parts of the article are reproduced in any manner. Applicable licensing terms are at <https://creativecommons.org/licenses/by-nc-nd/4.0/>.

Acrometastasis: A Rare Entity. A Proximal Radius Case

Holgado-Moreno Esperanza ^α, Cabezuelo-Díaz-Miguel Eduardo ^σ, Sánchez-Sánchez Félix ^ρ,
Alarma-Barcia Leticia ^ω & Guijarro-Leo Sandra [¥]

Abstract- Bone metastases under de knee and elbow (acrometastasis) are rare. We present the case of a patient diagnosed with lung adenocarcinoma, with a lesion in the right proximal radius. Radiological imaging through CT and MR suggested metastatic lesion, which anatomopathological results confirmed. As the presence of these markers provides a poor outlook, radiotherapy was initially considered. However, given the clinical stability of the patient and the limited amelioration observed, surgical treatment was finally conducted.

Keywords: acrometastasis, lung, radio, surgery.

I. INTRODUCTION

Bone metastatic disease is the most common malignant neoplasia of the bone. The term acrometastasis refers to the metastases produced in the distal extremities under knee and elbow. They represent 0,1% of all bone metastases¹having a greater incidence in males².The metastases in these regions usually indicate a worse outlook. Most of these metastases are produced by bronchopulmonary and renal tumors, where pulmonary origin represents nearly half of these cases³, with greater incidence in the upper extremities.

Although most metastatic lesions appear during disease, occasionally they appear as the first symptom, in up to 10% of cases⁴⁻⁵.

Patients with distal bone metastasis have a poor outlook and, those in which these are the first signs of the disease have worse survival prospects, with a median of 3 to 9 months⁵⁻⁶

II. CASE REPORT

We present the case of a 65 years old male with a pulmonary adenocarcinoma diagnosed, T4N2M0, IIIB stage, ROS1, and no ALK translocation, non-mutated EGFR, negative BRAF, PDL1 positive (1%). Ex-smoker for 14 years of a packet a day since age 15. The patient received chemotherapy (CBP/Alimta) + concomitant thoracic radiotherapy and is currently in maintenance treatment with Durvalumab.

The patient came to the emergency room of our hospital with pain in the proximal third of his right forearm, which had been ongoing for approximately one month and a half, with no record of previous trauma.

During the physical examination, he presented pain in the proximal third of the right radius and the anterolateral side of his forearm, accompanied by a loss of strength in the wrist. The supination ability was limited to 20°, with complete pronation and flexion and extension. Neurovascular distal exploration preserved.

In further tests, the following could be observed: Forearm RX: moth-eaten lytic lesion, poorly defined with cortical destruction of the proximal third with no evidence of associated fracture, compatible with bone metastasis. (Figure 1).

Author ^α ^p ^ω [¥]: Department of Orthopedic surgery, Hospital Universitario de Toledo. Toledo. e-mail: eholgadomoreno@gmail.com

Author ^σ: Deparment of Orthopedic surgery, Hospital La Mancha Centro. Alcázar de San Juan.

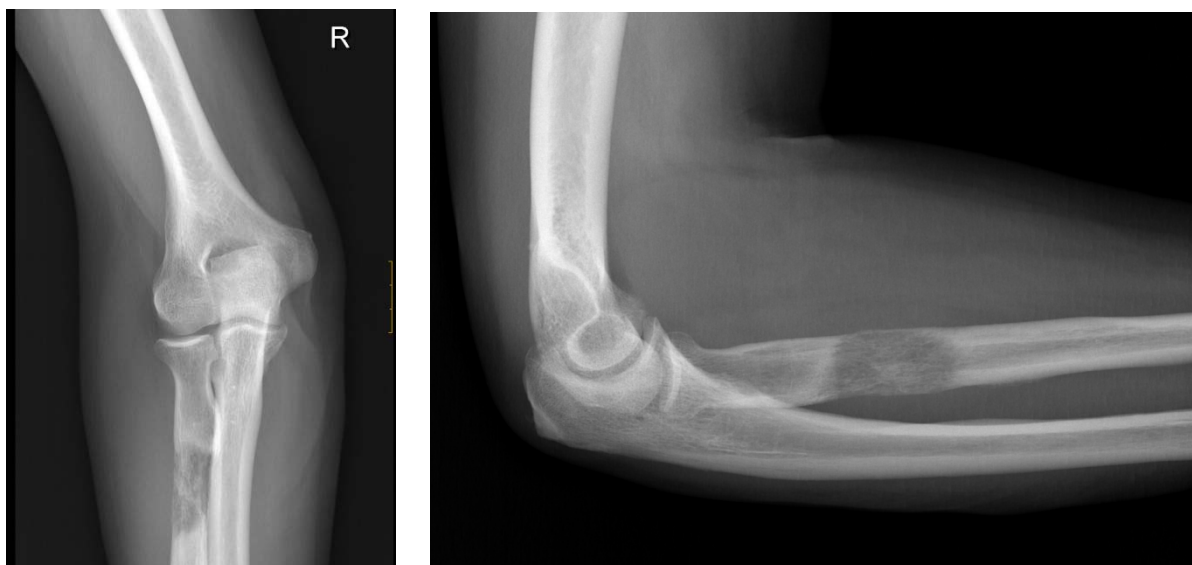


Figure 1: Radiological imaging AP (A) and lateral (B) of the right elbow where almost complete destruction of the proximal radius can be observed.

Subsequently, the study is extended with an MRI (Figure 2) showing a lytic lesion with cortical invasion and soft-tissue mass in the proximal radius

compatible with bone metastasis, invading the supine muscle and probably the extensor digitorum muscle as well as the distal insertion of the biceps tendon.

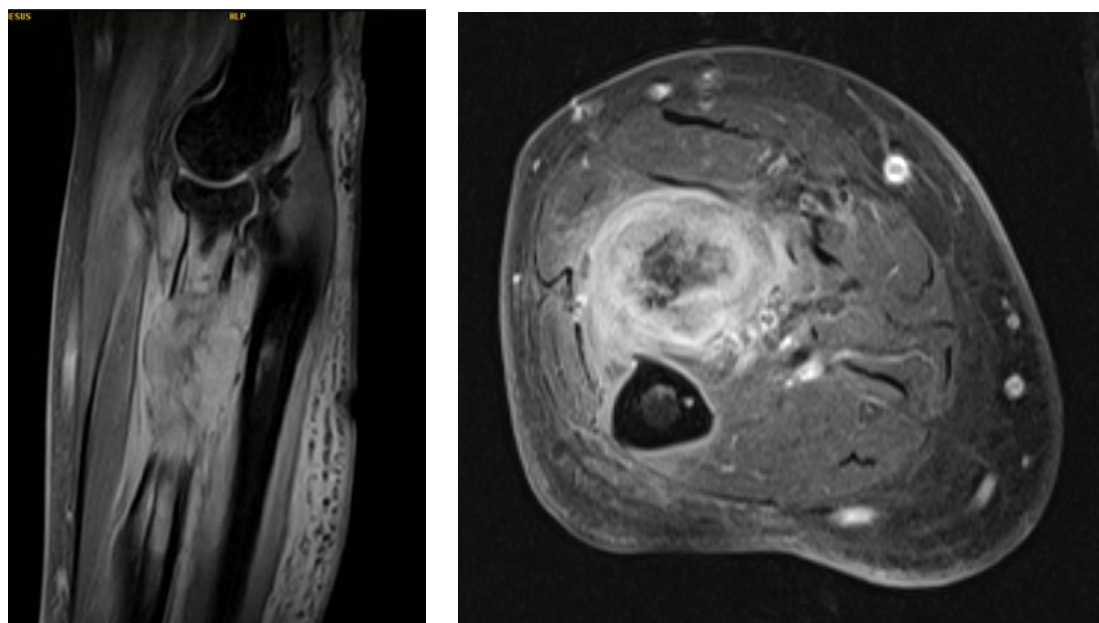


Figure 2: Sagittal image (A) and axial (B) of the pre-operative MR of the right elbow, which shows bone invasion and the extension of the associated soft-tissue mass.

With these findings, the medical oncology service requests a PET CT scan (figure 3) which shows the lesion in the right proximal radius and a partial improvement of the known pulmonary masses alongside a complete response of the bilateral hilar and mediastinal adenopathies.

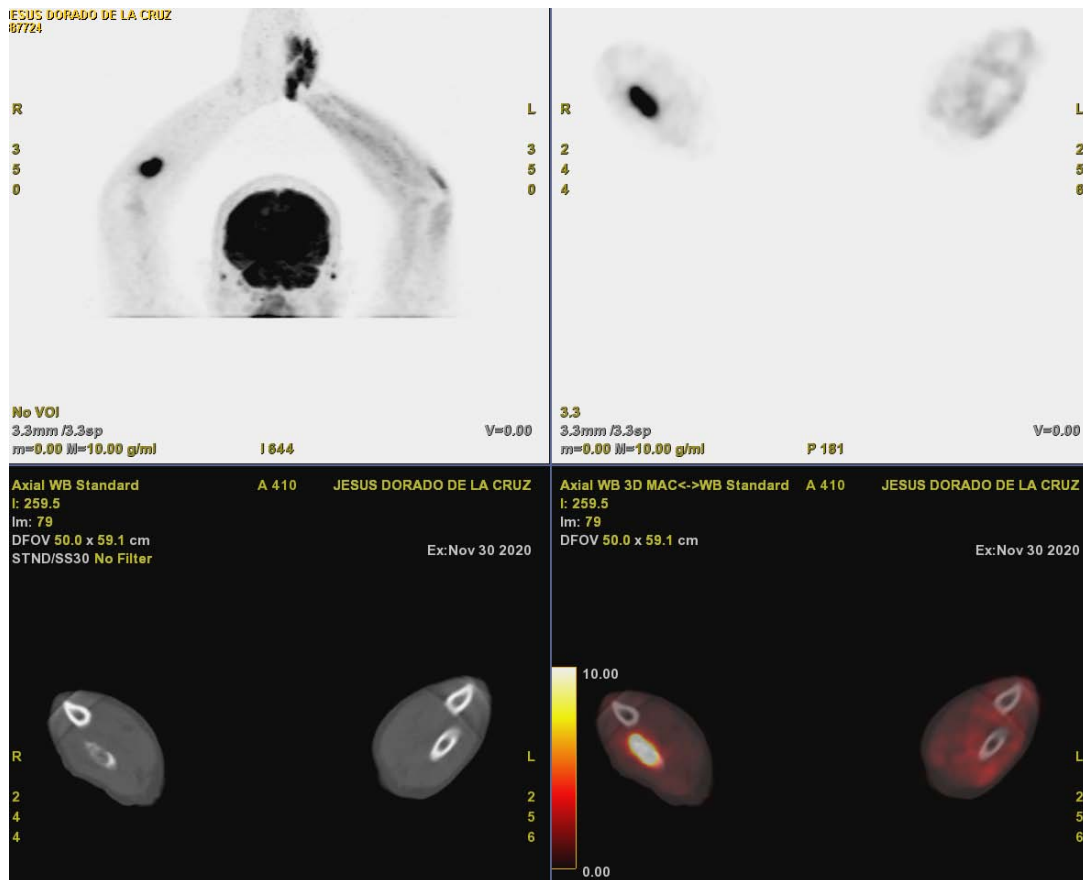
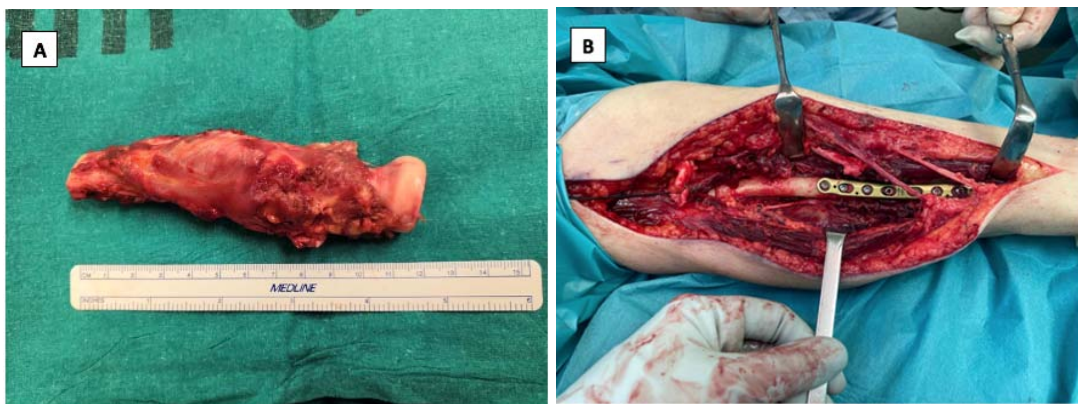


Figure 3: PET TAC image showing an intense increase in metabolic activity in a lytic lesion in the right proximal radius (SUV max 17.8)

Due to the radiological findings alongside the location and extension of the lesion, a palliative radiotherapy treatment is initiated. Six weeks after the radiotherapy treatment has ended, the patient attends a check-up, claiming to feel better despite ongoing pain

and limited functioning. A new MR of the right elbow is conducted finding a progression in the bone lesion. This motivates surgical treatment through ample resection and reconstruction with structural bone allografts from a bone bank. (Figure 4).



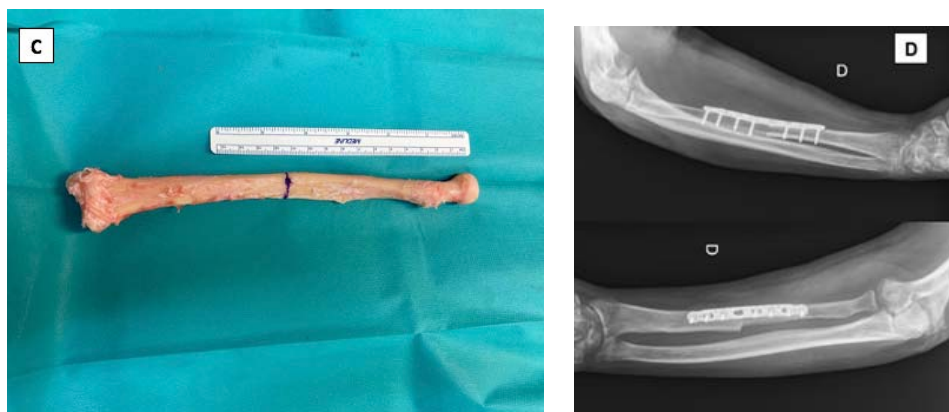


Figure 4

- A. Tumor resection of the proximal radius with soft-tissue mass.
- B. Bone bank allografts used for bone reconstruction of the post-resection defect.
- C. Intraoperative image after reconstruction and osteosynthesis.
- D. Postoperative AP and LAT Radiological image of the right elbow.

After surgery, a nerve paresis was observed of the radial nerve, which the patient has partially recovered with the help of rehabilitation. Clinically, the patient is no pain and has a mobility limitation of approximately 20° for supination and 10° for the extension.

III. DISCUSSION

Bone metastases can constitute the first symptom of a neoplastic process still unknown or appear concomitantly within an already diagnosed condition. The most important primary tumors of bone metastasis are prostate, breast, pulmonary, renal, and thyroid. Of these, prostate, breast, and lung constitute over 65% of all bone metastases⁷.

Clinically, the patient presents localized pain, progressive, which does not lessen at night nor improve with rest. Occasionally, it can be accompanied by soft-tissue mass⁸, which depending on location and size, can require clinical practice due to the compression of neighboring structures.

Radiologically, we find lesions that are typically lytic, with a varying pattern of bone destruction but typically geographic with cortical affectation, without periosteal reaction in most cases, and occasionally with an associated element of soft-tissue mass. In fact, given its clinical and radiological characteristics, they can imitate those of an infection or other non-neoplastic processes such as inflammatory or rheumatoid arthritis⁴, producing a delay in obtaining a definite diagnosis, mainly in patients without a known primary tumour. As a result, inadequate treatment is likely to take place.

The process by which bone metastases appear is still not well defined, but it could be due to a diffusion system in the blood flow different from habitual lymphatic media, thus explaining the tumors cells' preference for distal regions which are richly

vascularised³. Libson and col. show how the location of the metastasis depends on the venous system which different affected organs drain to Hence, malignant neoplasm located at a supradiaphragmatic level such as the lung, tends to produce metastasis under the elbow, in contrast, subdiaphragmatic neoplasm as the colon, urothelial, uterus, and prostate tend to make metastasis under the knee^{5,8,9}.

Currently the survival of cancer patients has increased to a great extent because of the improvement of oncological treatment, enabling the survival of patients with metastatic disease. This improvement in survival, at times, makes us reconsider, as surgeons, our therapeutic performance.

This increase in survival means pain control is frequently the main goal when treating these patients. The general state, the location of the lesion, and the type of primary cancer help establish the treatment which the surgeon must use¹⁰.

Due to the fact that acrometastases constitute a rare entity, no treatment protocol has been established. Each case must be examined separately in order to establish the best treatment according to the needs of each patient. In general terms, treatment tends to be palliative, including an adequate resection of the tumor, enabling pain relief and allowing fast recovery while preserving the maximal functional performance of the affected extremities.

Within the different treatments used, we mainly find radiotherapy, the tumor resection, and the combination of both^{3,11}.

IV. CONCLUSION

In conclusion, acrometastasis is an infrequent entity. However, due to the advance in the medical treatment of cancer, hence higher life expectancy of

patients, there also exists a significant increase in the diagnoses of metastatic bone lesions.

In patients with a history of cancer, those with unusual symptoms, or those who do not respond to certain standard treatments, a differential diagnosis must be established, which includes bone metastasis diagnosis.

REFERENCES RÉFÉRENCES REFERENCIAS

1. Kerin R. Metastatic tumors of the hand. A review of the literature. *J Bone Joint Surg Am.* 1983 Dec; 65(9): 1331-5. PMID: 6654944.
2. Flynn CJ, Danjoux C, Wong J, Christakis M, Rubenstein J, Yee A, Yip D, Chow E. Two cases of acrometastasis to the hands and review of the literature. *Curr Oncol.* 2008 Oct; 15(5):51-8. doi: 10.3747/co.v15i5.189. PMID: 19008991; PMCID: PMC2582515.
3. Asencio G, Hafdi C, Pujol H, Allieu Y. Osseous metastases in the hand. A general review of three cases. *Ann Chir Main.* 1982; 1(2): 137-45. English, French. doi: 10.1016/s0753-9053(82)80069-0. PMID: 6927376.
4. Abrahams TG. Occult malignancy presenting as metastatic disease to the hand and wrist. *Skeletal Radiol.* 1995 Feb; 24(2): 135-7. doi: 10.1007/BF00198077. PMID: 7747180.
5. Long LS, Brickner L, Helfend L, Wong T, Kubota D. Lung cancer presenting as acrometastasis to the finger: a case report. *Case Rep Med.* 2010; 2010: 234289. doi:10.1155/2010/234289
6. Libson E, Bloom RA, Husband JE, Stoker DJ. Metastatic tumours of bones of the hand and foot. A comparative review and report of 43 additional cases. *Skeletal Radiol.* 1987; 16(5): 387-92. doi: 10.1007/BF00350965. PMID: 3306939.
7. Fraguas a, Portabella F, Minguell J, Guerra E. Diagnóstico y tratamiento de las metástasis óseas. Editorial Panamericana. 2021
8. Leeson MC, Makley JT, Carter JR. Metastatic skeletal disease distal to the elbow and knee. *Clin OrthopRelat Res.* 1986 May; (206): 94-9. PMID: 3708998.
9. Bahrabadi M, Otoukesh B, Moghtadaei M, Hoseinzadeh S, Amiri S. Foot Metastasis: Review of 38 Cases. *Arch Bone Jt Surg.* 2021 Jan; 9(1): 122-125. doi: 10.22038/abjs.2020.49792.2474. PMID: 33778125; PMCID: PMC7957098.
10. Ratasvuori M, Wedin R, Keller J, Nottrott M, Zaikova O, Bergh P, Kalen A, Nilsson J, Jonsson H, Laitinen M. Insight opinion to surgically treated metastatic bone disease: Scandinavian Sarcoma Group Skeletal Metastasis Registry report of 1195 operated skeletal metastasis. *Surg Oncol.* 2013 Jun; 22(2): 132-8. doi: 10.1016/j.suronc.2013.02.008. Epub 2013 Apr 4. PMID: 23562148.
11. Mavrogenis AF, Mimidis G, Kokkalis ZT, Karampi ES, Karampela I, Papagelopoulos PJ, Armaganidis A. Acrometastases. *Eur J Orthop Surg Traumatol.* 2014 Apr; 24(3): 279-83. doi: 10.1007/s00590-013-1311-1. Epub 2013 Sep 8. PMID: 24013815.

Credit authorship contribution statement

All authors have contributed significantly, and all authors are in agreement with the content of the manuscript.

Funding

This research did not receive any specific grant from funding agencies in the public, commercial, or not-for-profit sectors.

Ethical approval

Written informed consent was obtained from the patient for publication of this case report and accompanying images. A copy of the written consent is available for review from the Editor-in-Chief of this journal on request.

Conflict of interest

All authors disclose any financial and personal relationships with other people or organizations that could inappropriately influence our work.