



GLOBAL JOURNAL OF MEDICAL RESEARCH: F
DISEASES

Volume 21 Issue 5 Version 1.0 Year 2021

Type: Double Blind Peer Reviewed International Research Journal

Publisher: Global Journals

Online ISSN: 2249-4618 & Print ISSN: 0975-5888

A Rare Case of Purtscher's Retinopathy Seen in RTA Patient

By Aye Myat Mon, Yogita Rajbhandari, Sudeep Rajbhandari
& Sanyam Bajimaya

Introduction- Purtscher's retinopathy was described by German Ophthalmologist Otmar Purtscher in 1910. It is an occlusive microvascular retinopathy caused by trauma such as head injury, thoracic compressive injury or long bone fractures.¹ Without history of trauma, it can also be due to systemic disease like acute pancreatitis, renal failure, lymphoproliferative disorder, valsalva maneuver, fat embolism syndrome or autoimmune diseases and they present with similar retinal findings and it is called Purtscher like retinopathy.²

Patients usually come with reduced visual acuity following injury. Clinical findings commonly seen in retina include cotton wool spots, retinal haemorrhage, areas of retina whitening (Purtscher flecken) or optic disc oedema. And 60% of cases have bilateral involvement.³ Purtscher flecken, pathognomonic of Purtscher's retinopathy, are typically seen in posterior pole sparing the perivascular areas.^{4,5}

GJMR-F Classification: NLMC Code: WW 270, WW 168



ARARECASEDFPURTSCHERSRETINOPATHYSEENINRTAPATIENT

Strictly as per the compliance and regulations of:



RESEARCH | DIVERSITY | ETHICS

© 2021. Aye Myat Mon, Yogita Rajbhandari, Sudeep Rajbhandari & Sanyam Bajimaya. This is a research/review paper, distributed under the terms of the Creative Commons Attribution-Noncommercial 3.0 Unported License (<http://creativecommons.org/licenses/by-nc/3.0/>), permitting all non-commercial use, distribution, and reproduction in any medium, provided the original work is properly cited.

A Rare Case of Purtscher's Retinopathy Seen in RTA Patient

Aye Myat Mon ^α, Yogita Rajbhandari ^σ, Sudeep Rajbhandari ^ρ & Sanyam Bajimaya ^ω

I. INTRODUCTION

Purtscher's retinopathy was described by German Ophthalmologist Otmar Purtscher in 1910. It is an occlusive microvascular retinopathy caused by trauma such as head injury, thoracic compressive injury or long bone fractures.¹ Without history of trauma, it can also be due to systemic disease like acute pancreatitis, renal failure, lymphoproliferative disorder, valsalva maneuver, fat embolism syndrome or autoimmune diseases and they present with similar retinal findings and it is called Purtscher like retinopathy.²

Patients usually come with reduced visual acuity following injury. Clinical findings commonly seen in retina include cotton wool spots, retinal haemorrhage, areas of retina whitening (Purtscher flecken) or optic disc oedema. And 60% of cases have bilateral involvement.³ Purtscher flecken, pathognomonic of Purtscher's retinopathy, are typically seen in posterior pole sparing the perivascular areas.^{4,5}

We report a case of Purtscher's retinopathy following Road Traffic Accident (RTA).

II. CASE PRESENTATION

A 35 year old male patient came with chief complaint of painless diminution of vision in both eyes for 10 days following road traffic accident (RTA). He had history of loss of consciousness for 1 hour but he denied any history of nausea, vomiting or bleeding from nose and ears. He was admitted in a general hospital where he underwent repair of his lip laceration and open reduction and internal fixation of his both upper limbs. He was discharged from the hospital after nine days stay.

Regarding his general examination, he was well oriented but ill-appearing. The sutures were noted on his lip. There was POP cast with arm slings on his both upper limbs. On ocular examination, his unaided visual acuity was 6/24 in right eye and counting fingers at 3m in left eye. Extraocular motility was full in both duction and version movements. Lid and adnexa were normal in both eyes. Anterior segment examination revealed sub-conjunctival haemorrhage in RE. Cornea was clear in both eyes. Anterior chamber was normal in depth and was quiet. The pupillary reaction was sluggish in both eyes and relative afferent pupillary defect (RAPD) could not be properly accessed. Lens was clear in both eyes.

On dilated fundus examination with clear vitreous media, optic disc was pink with well-defined margin and cup disc ratio of 0.3 with healthy neuroretinal rim in both eyes. There were multiple cotton wool spots around peripapillary region, few Purtscher fleckens and sub-retinal haemorrhage in BE while macula was healthy. Intraocular pressure was 12 mm Hg in both eyes.

Provisional diagnosis of BE Purtscher's retinopathy with traumatic optic neuropathy was made. Color vision, Humphrey 30-2 visual field test and macula OCT were sent to confirm the diagnosis. He was started on oral prednisolone 60mg (1mg/kg BW) OD for 1 week, oral Pantoprazole 40mg OD for 1 week and topical Ketorolac QID for 2 weeks and was called for follow-up with reports.

His color vision was normal in RE but abnormal in LE and visual field deficit in HVF 30-2 was detected in LE. Macula OCT was normal in both eyes.

The final diagnosis was made as BE Purtscher's retinopathy with LE traumatic optic neuropathy. Patient was asked to continue oral prednisolone in tapering dose and was called for follow up in one month.

At 1month follow-up, his unaided visual acuity was 6/6 in RE and 6/24 in LE. Sub-conjunctival haemorrhage had resolved. On dilated fundus examination with clear vitreous media, optic disc of RE was normal in appearance while mild temporal pallor of disc was noted in LE. About 50% of cotton wool spots had resolved in BE.

Regarding treatment, oral prednisolone was continued along with a multivitamin capsule. Patient was advised to follow up in 1 month.

III. DISCUSSION

Pathogenesis of Purtscher's retinopathy has been assumed due to microembolization of retinal vessels either from fat emboli in patient with long bone fractures or disseminated pancreatic proteases in acute pancreatitis. The possible emboli in Purtscher's retinopathy may include air, fat, leucocyte aggregates, platelets and fibrin. It causes arteriolar precapillary occlusion and retinal nerve fiber layer infarction presenting with cotton-wool spots.^{4,6} In other words, it is a kind of retinal vasculitis induced by lipase after systemic injury which leads to thrombosis and vascular occlusion.⁴ The pathognomonic sign is Purtscher

Author: e-mail: poe.t.clown@gmail.com

flecken and they can be found in inner retina between the retinal arterioles and venules. And the reason why Purtscher flecken were confined to the posterior pole can be explained because it is prone to get embolic occlusion due to less anastomoses and less arterioles in that area.^{4,5} In our case, the patient had fractures in both upper limbs, making fat emboli a likely cause.

The commonest clinical signs of the disease mentioned in one study were cotton wool spots (93%), retinal haemorrhages (65%) and Purtscher flecken (63%).² It was relevant with our case because there were all three significant clinical signs in BE. In 4% of patients with long bone fracture, there may be only cotton-wool spots and retinal haemorrhages but not Purtscher flecken.⁴ Other ocular findings which can be seen are optic atrophy, decreased color vision, RPE changes and dilated and tortuous retinal vessels.

Few diagnostic criteria for Purtscher retinopathy have been defined in literatures. Our diagnosis was based on criteria given by Miguel et al² who had defined it with presence of at least three of the following criteria: Purtscher flecken, cotton-wool spots confined to the posterior pole, retinal haemorrhage, relevant etiology and complementary investigations compatible with diagnosis.

There is no standard treatment mentioned in the literatures. Most of the patients recover without any treatment.⁷ But the vision improvement was well noted in some studies after giving intravenous methyl prednisolone and oral prednisolone after initial trauma. In the study by Atabay et al⁸, intravenous methyl prednisolone was given to a Purtscher's retinopathy patient 3 weeks after the initial trauma but visual acuity improved by more than 3 lines after 3 months. In Wang et al⁹, the patient with the history of trauma received 1 g of intravenous methylprednisolone for 3 days followed by oral steroids for 3 weeks and the improvement of vision from CF to 6/12 was noted. Normalization of fundus was 40% after 2 months in Miguel's study.² In our case, visual acuity improved from CF3m to 6/24 with oral prednisolone (1mg/kg) at 1 month follow up.

IV. CONCLUSION

Purtscher's retinopathy is a rare condition in our practice but it can be diagnosed clinically with its significant clinical signs and the relevant history of trauma or other associated diseases. And treatment with oral corticosteroid can improve the visual acuity.

Consent

The patient has no objection to use his photos in academic and research work.

Source of funding

None.

Conflict of interest

None.

REFERENCES RÉFÉRENCES REFERENCIAS

1. P. Noch unbekannte befunde nach schadeltrauma. Ber Dtsch Ophthalmol Ges. 1910; 36: 294–301.
2. Miguel a IM, Henriques F, Azevedo LFR, Loureiro a JR, Maberley D a L. Systematic review of Purtscher's and Purtscher-like retinopathies. Eye (Lond). 2013; 27(1): 1–13. doi: 10.1038/eye. 2012. 222.
3. Agrawal A, McKibbin M. Purtscher's retinopathy: epidemiology, clinical features and outcome. Br J Ophthalmol. 2007; 91(11): 1456–9. doi: 10.1136/bjo. 2007.117408.
4. Agrawal A, McKibbin MA. Purtscher's and Purtscher-like retinopathies: a review. Surv Ophthalmol. 2006; 51(2): 129–36. doi: 10.1016/j. survophthal.2005.12.003.
5. Michaelson IC CA. The anatomy of the finer retinal vessels. Trans Ophthalmol Soc UK. 1940; 60: 71–111.
6. Kincaid MC, Green WR, Knox DL, Mohler C. A clinicopathological case report of retinopathy of pancreatitis. Br J Ophthalmol. 1982; 66(4): 219–26.
7. Rancone D. Purtscher's retinopathy. Optometry 2002; 73(3): 166-72.
8. Atabay C, Kansu T, Nurlu G. Late visual recovery after intravenous methylprednisolone treatment of Purtscher's retinopathy. Ann Ophthalmol. 1993; 25(9): 330–333.
9. Wang AG, Yen MY, Liu JH: Pathogenesis and neuroprotective treatment in Purtscher's retinopathy. Jpn J Ophthalmol 42:318-22, 1988.

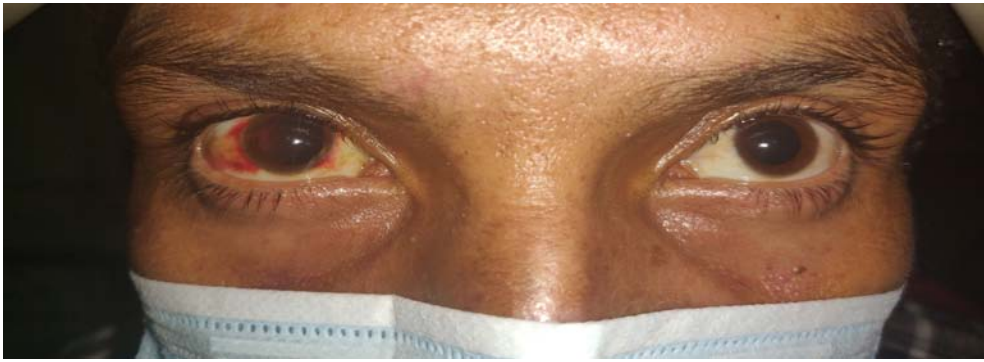


Figure 1: Photo showing RE subconjunctival hemorrhage

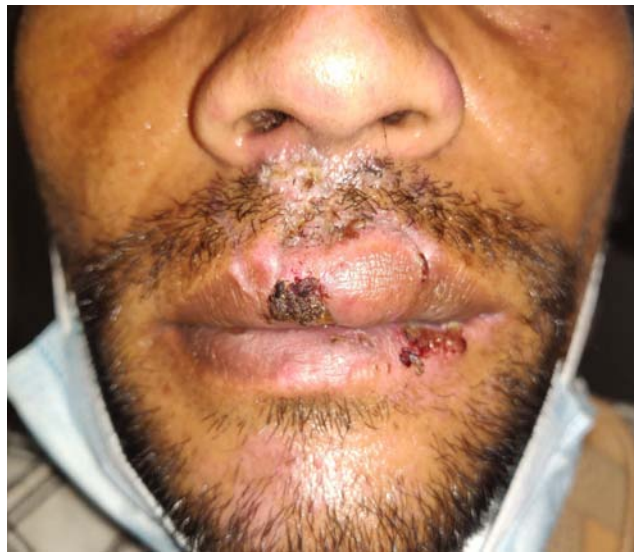

Figure 2: Photo showing facial injury

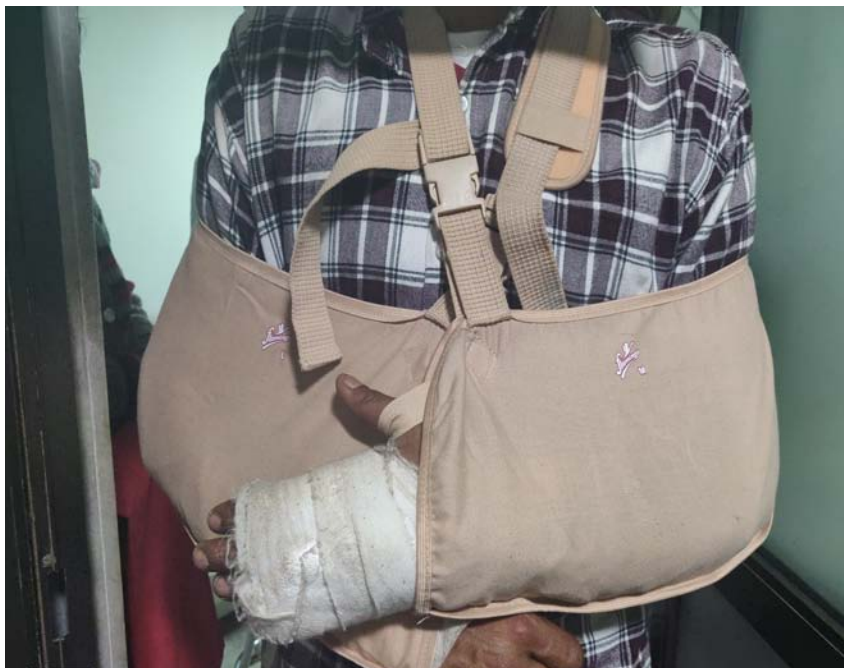

Figure 3: Patient presenting with arm slings after surgery of bilateral forehands fracture



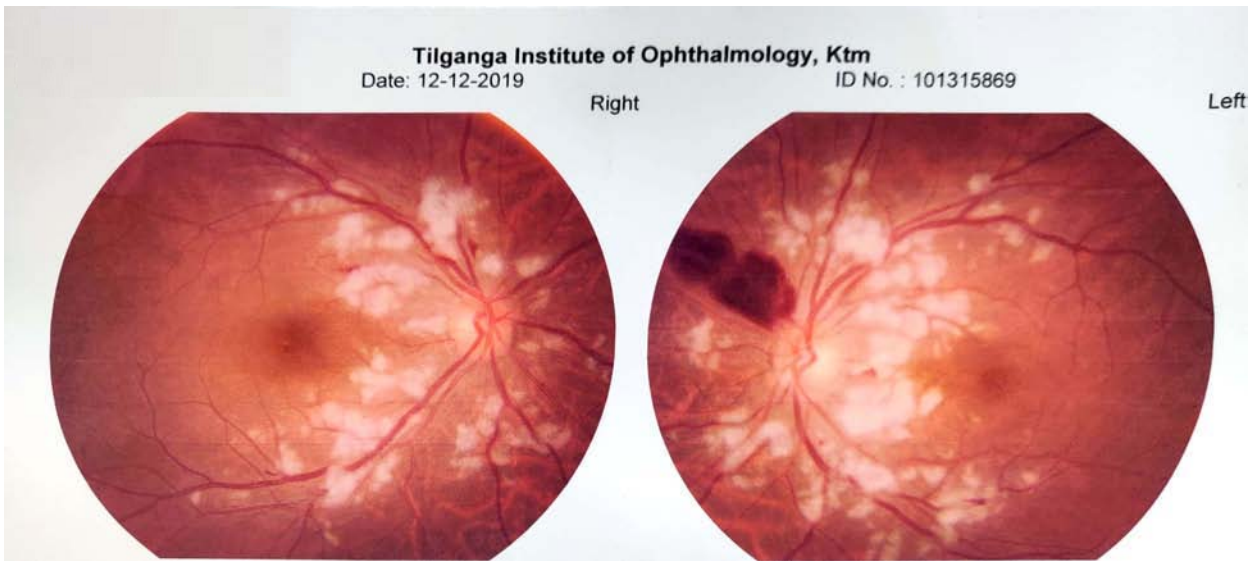


Figure 4: Fundus photo of both eyes at the time of presentation showing cotton wool spots, Purtscher's flecken and retinal hemorrhages

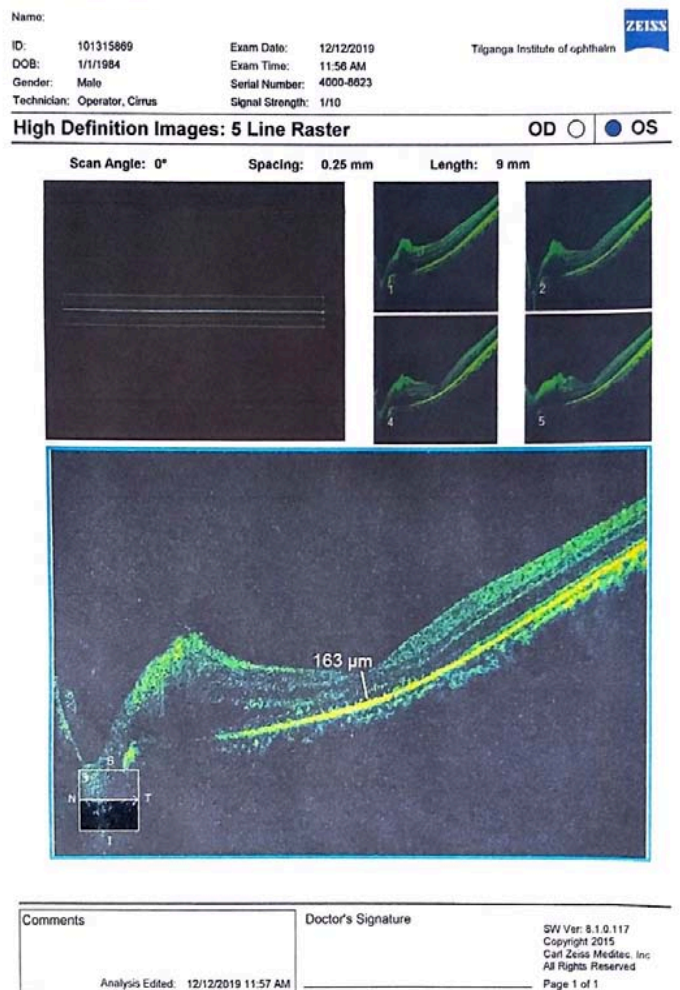
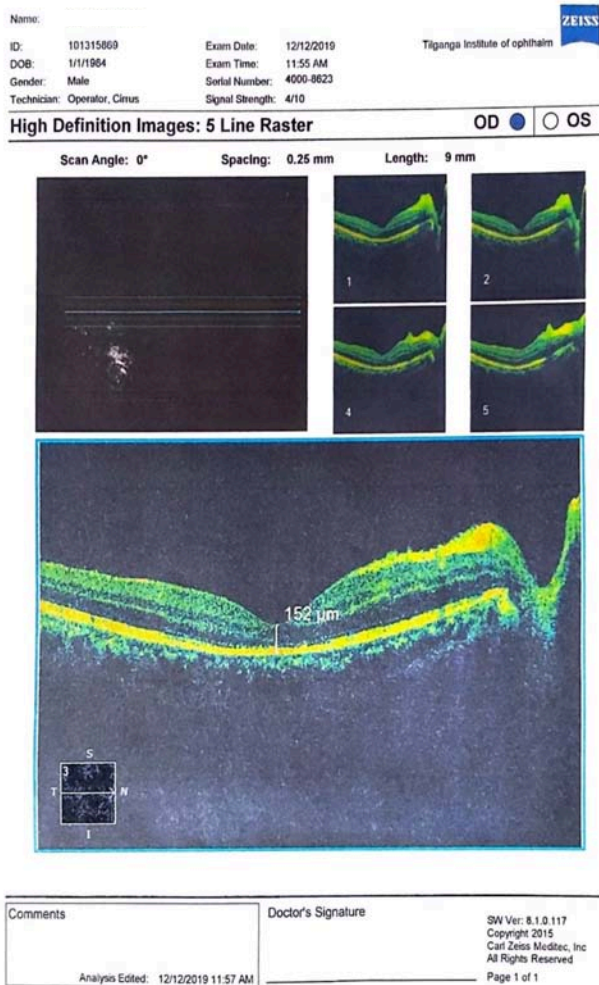


Figure 5: Macula OCT of both eyes showing normal macula contour