



GLOBAL JOURNAL OF MEDICAL RESEARCH: E
GYNECOLOGY AND OBSTETRICS
Volume 22 Issue 3 Version 1.0 Year 2022
Type: Double Blind Peer Reviewed International Research Journal
Publisher: Global Journals
Online ISSN: 2249-4618 & Print ISSN: 0975-5888

Fractional CO2 Laser in the Treatment of Post-Menopausal Vaginal Atrophy

By Honório Sampaio Menezes, Elaine Sangalli Mallmann, João Evangelista Sampaio Menezes, Rodrigo Cadore Mafaldo, Roberto Chacur, Danuza Dias Alves, Nivea Maria Bordin da Silva Chacur, Vincenzo Stein de Vargas, Leandro Dias Gomes, Gisele dos Santos Barreto & Gabriella Andressa Marchesin de Castro

Abstract- Introduction: Similarly to other parts of the body, the vagina changes over time, and vaginal atrophy is a common condition in women between 45 and 55 years of age. It causes discomfort and psychological suffering, in addition to being the main cause of pain during sexual intercourse.

Objective: This study aimed to evaluate the use of intravaginal fractional CO2 laser in the treatment of atrophy of the vaginal mucosa, as well as its effect on symptoms such as itching, irritation, pain, dyspareunia, urinary incontinence, dryness, and loss of mucosal elasticity.

Methods: This is a prospective cohort of 14 menopausal women with vulvovaginal symptoms who were evaluated pre- and post-procedure with CO2 laser treatment using the Monalisa Touch® technique. Cytological examination and validated questionnaires were used in the assessment.

Keywords: vaginal atrophy, vaginal rejuvenation, fractional CO2 laser.

GJMR-E Classification: DDC Code: 600 LCC Code: T47



Strictly as per the compliance and regulations of:



© 2022. Honório Sampaio Menezes, Elaine Sangalli Mallmann, João Evangelista Sampaio Menezes, Rodrigo Cadore Mafaldo, Roberto Chacur, Danuza Dias Alves, Nivea Maria Bordin da Silva Chacur, Vincenzo Stein de Vargas, Leandro Dias Gomes, Gisele dos Santos Barreto & Gabriella Andressa Marchesin de Castro. This research/review article is distributed under the terms of the Attribution-NonCommercial-NoDerivatives 4.0 International (CC BY-NC-ND 4.0). You must give appropriate credit to authors and reference this article if parts of the article are reproduced in any manner. Applicable licensing terms are at <https://creativecommons.org/licenses/by-nc-nd/4.0/>.

Fractional CO2 Laser in the Treatment of Post-Menopausal Vaginal Atrophy

Fractional CO2 Laser in Post-Menopausal Women

Honório Sampaio Menezes ^α, Elaine Sangalli Mallmann ^σ, João Evangelista Sampaio Menezes ^ρ, Rodrigo Cadore Mafaldo ^ω, Roberto Chacur [¥], Danuza Dias Alves [§], Nivea Maria Bordin da Silva Chacur ^χ, Vincenzo Stein de Vargas ^ν, Leandro Dias Gomes ^θ, Gisele dos Santos Barreto ^ζ & Gabriella Andressa Marchesin de Castro [£]

Abstract- Introduction: Similarly to other parts of the body, the vagina changes over time, and vaginal atrophy is a common condition in women between 45 and 55 years of age. It causes discomfort and psychological suffering, in addition to being the main cause of pain during sexual intercourse.

Objective: This study aimed to evaluate the use of intravaginal fractional CO2 laser in the treatment of atrophy of the vaginal mucosa, as well as its effect on symptoms such as itching, irritation, pain, dyspareunia, urinary incontinence, dryness, and loss of mucosal elasticity.

Methods: This is a prospective cohort of 14 menopausal women with vulvovaginal symptoms who were evaluated pre- and post-procedure with CO2 laser treatment using the Monalisa Touch® technique. Cytological examination and validated questionnaires were used in the assessment.

Results: The mean (standard deviation) age of the patients was 58.1 (8.5), ranging from 46 to 78. The analysis of the Bachmann vaginal health index (VHI) showed a statistically significant difference ($p < 0.005$) between pre- and post-procedure, suggesting a substantial improvement in vaginal health. There was a significant increase in vaginal epithelial cells ($p < 0.05$). No side effects were reported.

Conclusion: In addition to objectively demonstrating the improvement of vaginal cellularity, the results of the present study corroborate the physical, psychological, and social benefits of intravaginal CO2 laser technology for menopausal women in terms of quality of life.

Keywords: vaginal atrophy, vaginal rejuvenation, fractional CO2 laser.

I. INTRODUCTION

Not long ago, the decline in sexual interest among women started before menopause, a period when estrogen production decreases gradually until the loss of libido and the appearance of uncomfortable symptoms in the perineal region. In a study published in 2014, Filippini stated that this painful and debilitating condition is often associated with psychological suffering and has a negative impact on women's lives. In addition to pain in the region, many

women suffer from symptoms related to vaginal atrophy. These begin to appear between the ages of 45 and 55 and usually persist or even worsen over time. "This condition may cause dryness, irritation, burning, or pain during intercourse, affecting 40% of postmenopausal women"¹.

Salvatore, a pioneer in the application of *Monalisa Touch*® fractional CO2 laser, has published several studies assessing the effectiveness of this treatment in improving the symptoms of vaginal atrophy, and these have shown significant improvement in the physical and mental quality of life of the evaluated women².

According to Filippini¹ (2017), a clinical and histological study on the effectiveness of the *Monalisa Touch*® CO2 laser treatment in the restoration of the vaginal mucosa and lower urinary tract was presented at the 20th World Congress of the International Federation of Gynecology and Obstetrics (FIGO) held in Rome. Based on this study, the author has published several works confirming how promising the use of the *Monalisa Touch*®³ has been.

In a study on a 12-week treatment with the *Monalisa Touch*® fractional CO2 laser, Salvatore et al. evaluated 50 women aged between 59.6 and 65.4 years who were dissatisfied with their previous local estrogen therapies. After three laser applications throughout the treatment, 42 women (84%) reported being satisfied with the procedure and experiencing minimal discomfort due to the insertion and movements of the probe during the first application. Data concerning the patients' physical and mental quality of life showed significant improvement².

After analyzing such positive data regarding the *Monalisa Touch*® treatment in women in Europe, the present study was designed to confirm those data and evaluate objectively (by histological examination) and subjectively the effects of the procedure on the vaginal mucosa.

Author ¥: Avenida das Américas, 3301 – Bloco 4 – Sala 301 – Barra da Tijuca – Rio de Janeiro/RJ – Brasil.
e-mail: nucleodepesquisa@clinicaleger.com.br

II. METHODOLOGY

This is a prospective cohort study of 14 menopausal women with vulvovaginal symptoms (vaginal dryness, irritation, soreness, or dyspareunia). The patient enrollment required sexual activity at least once a month, no menstrual cycle for at least 12 months, and symptoms not alleviated by previous local estrogen therapy. Systemic or topical hormone replacement therapies within the past 6 months, acute or recurrent urinary tract infections, active genital infections, prolapse stage \geq II according to the pelvic organ prolapse quantification (ICS-POP-Q) system, and smoking constitute exclusion criteria.

a) Study Protocol and Procedure

The study was a prospective, outpatient setting. Prior to treatment, a complete gynecological exam was performed. The patients were recommended to avoid sexual activity for 3 days from each laser treatment session (mild inflammatory reaction may occur up to 48 hours).

In this study, a fractional microablative CO₂ laser system (Rentall Medical Brazil, SmartXide2, *Monalisa Touch*®, DEKA Laser, Florence, Italy) was applied twice time using dot spacing 1,000, dwell time 1,000, dot power 30 W, and 360° tip. Laser energy was transmitted through an intravaginal probe inserted into the vaginal canal (up to 12 cm).

b) Data Collection

Demographic data of the study population were gathered using a questionnaire applied before the first laser treatment.

Patients were evaluated before and after intravaginal CO₂ laser treatment (*Monalisa Touch*®, SmartXide2, DEKA Laser, Florence, Italy). Two questionnaires were administered to assess vulvovaginal atrophy (VVA) symptoms using a visual analog scale (VAS) and the Bachmann vaginal health index (VHI). These were applied pre-treatment and 30 to 40 days after the second and third laser applications. The VAS scores were classified into three groups: mild (0-2), moderate (3-7), and severe (8-9).

Bachmann's VHI measures elasticity, secretion volume, vaginal pH, and epithelial integrity. The scale was used to assess vaginal itching, vaginal burning, pain during intercourse, vaginal dryness, and difficulty urinating or dysuria and categorize these symptoms into mild (0-2), moderate (3-7), and severe (8-9).

In order to observe vaginal cellularity, cytopathology samples were collected pre-treatment and 30 to 40 days after the last laser application.

c) Data Analysis

The collected data were reported as mean (standard deviation), median, and percentage (%). Analyzes were performed using the SPSS software

version 25.0 (SPSS Science, Chicago, IL, USA). The paired-samples t-test and the signed-rank test were used to analyze continuous variables at a significance level of 0.05, corresponding to a 95% confidence interval.

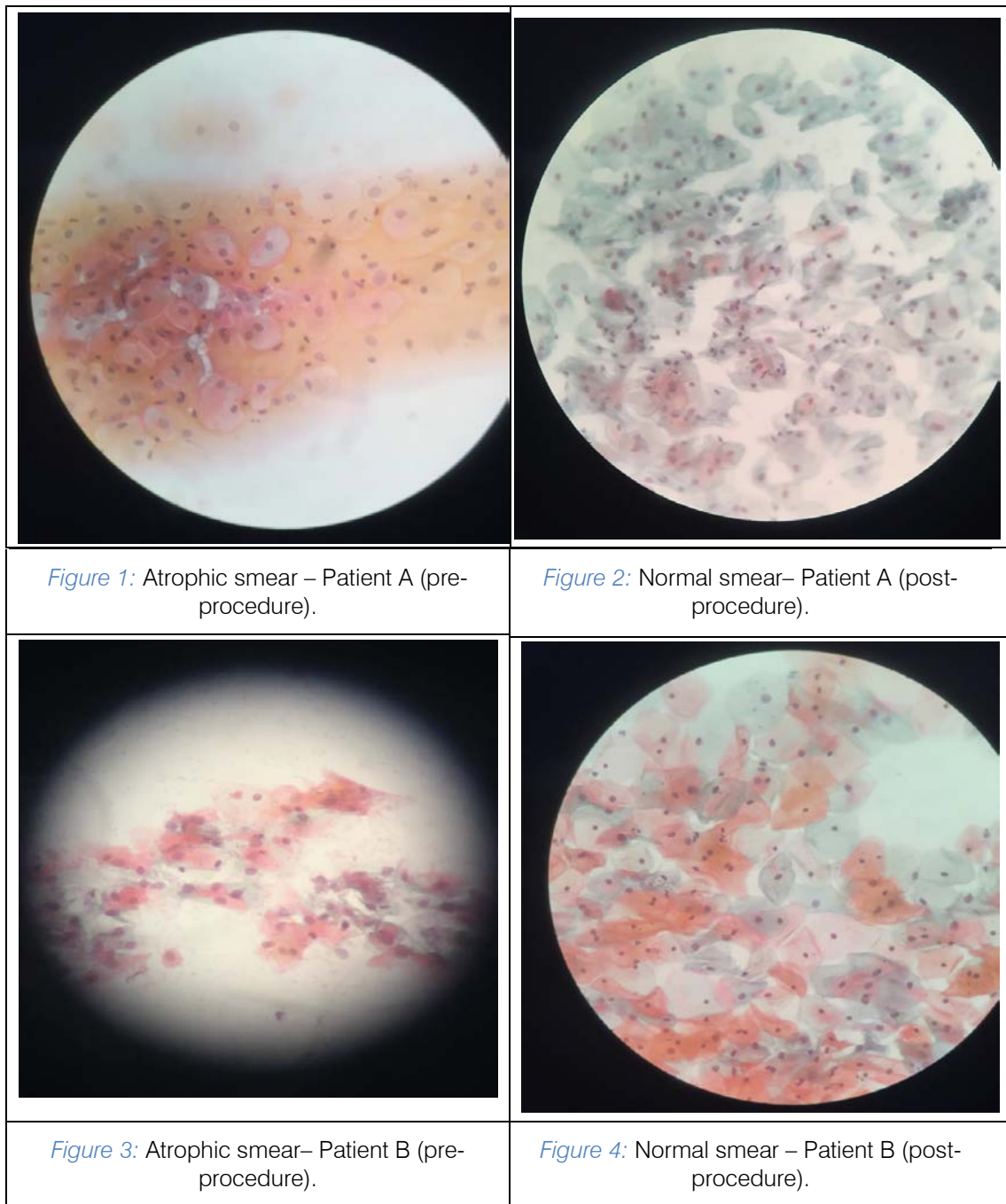
III. RESULTS

The mean (standard deviation) age was 58.1 (8.5), ranging from 46 to 78 years.

The analysis of the Bachmann vaginal health index (VHI), which measures elasticity, secretion volume, vaginal pH, epithelial integrity, and lubrication, showed a statistically significant difference ($p < 0.005$) between pre- and post-procedure, suggesting a substantial improvement in vaginal health.

The data from the VAS regarding VVA symptoms showed overall improvement. When considering vaginal itching, nine patients (64.29%) reported that the condition improved, and five (35.71%), that it remained the same (without pruritus). The seven patients (50%) who had vaginal burning indicated improvement, while the rest of them did not have it. Pain during sexual intercourse improved for nine patients (64.28) but did not improve for one (7.14%); three (21.42%) remained abstinent and one (7.14%) did not feel pain. Regarding vaginal dryness, 11 patients (78.57%) reported improvement, two (14.28%) did not have this symptom, and one (7.14%) did not mention improvement. Difficulty urinating or dysuria affected seven (50%) patients; for six (42.86%) of them, it improved, and for one (7.14%), it remained the same. The mean time between applications was 116 days SD=66 (59-265).

There was a significant increase in vaginal epithelial cells ($p < 0.05$).



Figures 1 and 3 show pre-procedure images of vaginal epithelial cells with severe atrophy and low cellularity. Figures 2 and 4 show smears demonstrating post-procedure recovery of vaginal cellularity and normal epithelium.

IV. DISCUSSION

In recent years, there has been a greater demand for safe, effective, and long-term treatments of the deeper layers of the vaginal mucosa and the epithelium.

Non-invasive treatments for vulvovaginal atrophy (VVA) symptoms are being researched, such as

carboxytherapy and radiofrequency, in addition we also have fractional CO₂ laser as a recent treatment option.

Relief of symptoms of vaginal atrophy can be achieved by non-surgical therapies, including fractional CO₂ laser⁵. This type of laser produces rapid transient changes in cellular metabolism. The local production of collagen synthesis, induction, coordination and expression of growth factors are induced by the acute thermos-ablative damage produced by the laser⁶.

As reported by Enemchukwu, the CO₂ fractional laser application is an effective way for the relief of symptoms in vaginal atrophy, even one year after the procedure⁵.

Significant improvement in VVA symptoms after three sessions of fractional CO₂ laser and improvement in quality of life were reported by Perino et al.⁶ 30 days after the last laser application. These finding could be corroborated by the present study, even after only two applications of fractional CO₂ laser. Our study showed significant improvement in VVA symptoms after a month of follow-up fractional CO₂ laser therapy.

VVA symptoms in 28 healthy post-menopausal women undergoing treatment with 3 sessions of intravaginal fractional CO₂ laser was evaluated one, 3 and 6 months post-laser; in this study Eder et al (2018)⁷ showed improvement in VVA symptoms and an increase in the Female Sexual Functioning Index (FSFI) from one month after the first treatment. This same finding had already been reported by Salvatore et al⁸, in 2015, where the FSFI improved in the first 12 weeks after intravaginal CO₂ laser application.

The VHI, studied by Arroyo (2017) showed improvement up to the eighth month after CO₂ laser treatment⁹.

According to Filippini & Farinelli, the Monalisa Touch® is an innovative CO₂ laser treatment developed by DEKA which gently acts on the vaginal tissues to stimulate collagen production, improve the functionality of the treated area, and restore the proper mucosal trophic balance. In another study, the author used the same method to treat postpartum dyspareunia. A significant improvement in symptoms could be observed in 5 to 6 patients, especially regarding dryness, dyspareunia, and pain in the vulval-perineal region. It is also noteworthy that most of these patients tried, without success, alternative therapies such as physical therapy, perineal massage, and tranquilizers¹.

Arroyo⁹ performed a clinical and histopathological evaluation, as suggested by Salvatore et al⁸, and found improvement in elasticity, secretion, epithelial integrity, lubrication and histopathological aspects, without reporting side effects.

Tahereh et al. (2020) compared intravaginal CO₂ laser and the application of hormone therapy with Premarin vaginal cream. They demonstrated how the laser was better at improving sexual desire, orgasms, and sexual satisfaction, and at decreasing pain during intercourse and overall sexual function in menopausal women. In the present study, no comparison was made with another treatment¹⁰.

In a recent study, Macrene et al. (2021) demonstrated persistent positive effects in vulvovaginal treatment after one year of postmenopausal fractional CO₂ laser treatment¹¹. The limitation of their study was the use of a small sample; however, the statistical significance found indicates that it did not affect the results.

Our study has the particularity of evaluating the cellular changes of the vaginal mucosa, objectively proving its improvement and recovery after the

application of fractional CO₂ laser. Furthermore, a significant improvement in objective signs and symptoms of genital function could also be seen.

V. CONCLUSION

In addition to objectively demonstrating the improvement of vaginal cellularity, the results of the present study corroborate the physical, psychological, and social benefits of the Monalisa Touch® fractional CO₂ laser technology for menopausal women in terms of quality of life.

Ethical Considerations

This study was approved by the Research Ethics Committee of the Moinhos de Vento Hospital under protocol number 81915417.0.0000.5330. All participants signed a written informed consent form. The study was conducted according to the guidelines of the Declaration of Helsinki.

Conflict of Interests

The authors declare no conflict of interest.

ACKNOWLEDGMENT

We thank Augusta Ketzer Menezes for the English assistance.

REFERENCES RÉFÉRENCES REFERENCIAS

1. Filippini M, Farinelli M. Use of the Monalisa Touch treatment for Post-Partum Dyspareunia. A Pilot Study. Gynaecological Endoscopy Functional Unit of the Republic of San Marino State Hospital. December 2014.
2. Salvatore S, Nappi RE, Zerbinati N, Calligaro A, Ferrero S, Origoni M, Candiani M, Leone Roberti Maggiore U. A 12-week treatment with fractional CO₂ laser for vulvovaginal atrophy: a pilot study. *Climacteric*. 2014 Aug; 17(4): 363-9. Doi: 10.3109/13697137.2014.899347. Epub 2014 Jun 5. PMID: 24605832.
3. Filippini M, Farinelli M. Preliminary results after four years of Monalisa Touch treatments on subjects with Genitourinary Syndrome of Menopause (GSM). Gynaecological Endoscopy Functional Unit of the Republic of San Marino State Hospital. May 2017.
4. Pinheiro NM, Crema VO, Millan BM, Carvalho FA, Mendonça AC. Comparison of the effects of carboxytherapy and radiofrequency on skin rejuvenation. *J Cosmet Laser Ther*. 2015 Jun; 17(3): 156-61. Doi: 10.3109/14764172.2014.1003238. Epub 2015 Jan 30. PMID: 25549818.
5. Enemchukwu EA. CO₂ Laser Treatment is Effective for Symptoms of Vaginal Atrophy: No. *J Urol*. 2017 Dec; 198(6): 1228-1229. Doi: 10.1016/j.juro.2017.09.004. Epub 2017 Oct 21. PMID: 29061288.
6. Perino A, Calligaro A, Forlani F, Tiberio C, Cucinella G, Svelato A, Saitta S, Calagna G. Vulvo-vaginal

- atrophy: a new treatment modality using thermo-ablative fractional CO₂ laser. *Maturitas*. 2015 Mar; 80(3): 296-301. Doi: 10.1016/j.maturitas.2014.12.006. Epub 2014 Dec 25. PMID: 25596815.
7. Eder SE. Early effect of fractional CO₂ laser treatment in Post-menopausal women with vaginal atrophy. *Laser Ther*. 2018 Mar 31;27(1):41-47. Doi: 10.5978/islsm.18-OR-04. PMID: 29795970; PMCID: PMC5958234.
 8. Salvatore S, Athanasiou S, Candiani M. The use of pulsed CO₂ lasers for the treatment of vulvovaginal atrophy. *Curr Opin Obstet Gynecol*. 2015 Dec; 27(6): 504-8. Doi: 10.1097/GCO.0000000000000230. Erratum in: *Curr Opin Obstet Gynecol*. 2017 Aug; 29(4): 282. PMID: 26536212.
 9. Arroyo C. Fractional CO₂ laser treatment for vulvovaginal atrophy symptoms and vaginal rejuvenation in perimenopausal women. *Int J Womens Health*. 2017 Aug 28; 9: 591-595. Doi: 10.2147/IJWH.S136857. PMID: 28894392; PMCID: PMC5584900.
 10. Eftekhari T, Forooghifar T, Khalili T, Shariat M, Haghollahi F. The Effect of the CO₂ Fractional Laser or Premarin Vaginal Cream on Improving Sexual Function in Menopausal Women: A Randomized Controlled Trial. *J Lasers Med Sci*. 2020 Summer; 11(3): 292-298. Doi: 10.34172/jlms.2020.49. Epub 2020 Jun 21. PMID: 32802290; PMCID: PMC7369558.
 11. Alexiades MR. Fractional CO₂ Laser Treatment of the Vulva and Vagina and the Effect of Postmenopausal Duration on Efficacy. *Lasers in Surgery and Medicine*. 2021; 53: 185–198. DOI: 10.1002/SM.23247

