



GLOBAL JOURNAL OF MEDICAL RESEARCH: D  
RADIOLOGY, DIAGNOSTIC AND INSTRUMENTATION  
Volume 24 Issue 1 Version 1.0 Year 2024  
Type: Double Blind Peer Reviewed International Research Journal  
Publisher: Global Journals  
Online ISSN: 2249-4618 & Print ISSN: 0975-5888

## Unusual Case of Large Conglomerate Mass in Abdomen

By Sajanakan Sriselvakumar

*Abstract-* Testicular seminoma commonly occurs in young men aged between 15 and 45 years old. Those with testicular cancer may present with a lump or swelling in the testicle. If treated and managed early, patients can expect a greater than 90% success rate. However, advanced stages of testicular seminoma can lead to eventual metastasis. We present a 45-year-old male patient with a prior history of testicular seminoma who was admitted to the emergency department with abdominal distension and mild abdominal pain. The CT identified a rather sizable abdominal mass and the biopsy report confirmed metastatic testicular seminoma. This patient is currently on active chemotherapy with bleomycin, cisplatin, and etoposide.

*Keywords:* metastatic testicular seminoma; abdominal pain; abdominal distention.

*GJMR-D Classification:* FOR Code: 1112



*Strictly as per the compliance and regulations of:*



# Unusual Case of Large Conglomerate Mass in Abdomen

Sajanakan Sriselvakumar

**Abstract-** Testicular seminoma commonly occurs in young men aged between 15 and 45 years old. Those with testicular cancer may present with a lump or swelling in the testicle. If treated and managed early, patients can expect a greater than 90% success rate. However, advanced stages of testicular seminoma can lead to eventual metastasis. We present a 45-year-old male patient with a prior history of testicular seminoma who was admitted to the emergency department with abdominal distension and mild abdominal pain. The CT identified a rather sizable abdominal mass and the biopsy report confirmed metastatic testicular seminoma. This patient is currently on active chemotherapy with bleomycin, cisplatin, and etoposide.

**Keywords:** metastatic testicular seminoma; abdominal pain; abdominal distention.

## I. INTRODUCTION

Testicular cancer represents 1% of male tumors and 5% of urological cancers (1) and predominantly affects young males between the ages of 15 and 45 years old (2). With early diagnosis and intervention, the prognosis is promising with greater than 90% cure rate and 95% five-year survival rate (1). There is a multitude of factors that can cause testicular cancer including cryptorchidism (2-4-fold increased risk) (3), family history of testicular cancer (6-10% fold increased risk) (4), prior history of testicular cancer (1), sexually transmitted infections (5), testicular trauma (6), and potentially elevated maternal estrogen levels (7). There may be no prominent symptomology for patients with testicular cancer (8). However, some patients may experience painless swelling and other less common symptoms such as back pain, enlargement or tenderness of breast tissue and pain in the lower abdomen (8).

### Case Report

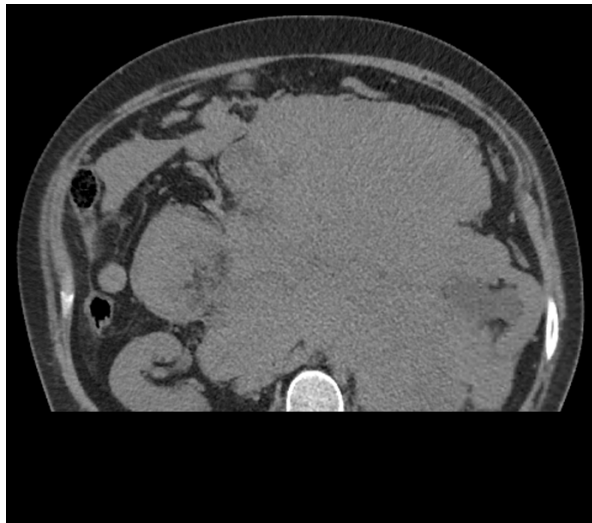
A 45-year-old man with prior medical history of testicular cancer and left orchiectomy in 2021 was admitted to the emergency room with mild abdominal pain, distention, and vomiting. Our patient reported missed outpatient attendance following their orchidectomy in 2021. He had no known testicular cancer in his family history. Additionally, there is no medical history of cryptorchidism. On initial presentation, his heart rate was 130, blood pressure

was 130/70, respiratory rate of 16, oxygen saturation was 98% and he was afebrile. His tachycardia improved with fluid resuscitation. On physical examination, a large, distended abdomen and generalized abdominal tenderness was noted. His bowel sounds were present, and previous surgical scars healed well.

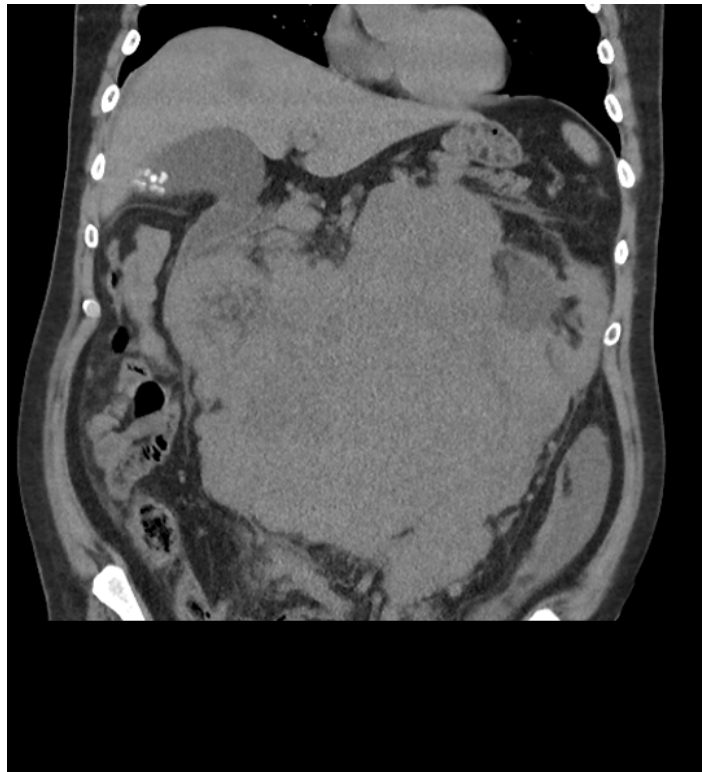
The abdominal and pelvic CT in *Figure 1* and *Figure 2* revealed a large undifferentiated mass localized throughout the abdomen and pelvis (transverse dimensions: 25.4 x 22.8 cm). The CT scan in *Figure 1* also demonstrated left kidney displacement and encasement of the abdominal aorta, visceral branches, and inferior vena cava. There is also encasement of the small and large bowel loops in the upper abdomen and this mass extends into the central pelvis. The liver in *Figure 2* also highlights one of the many multiple solid lesions spread throughout both hepatic lobes and is mainly right-sided. The largest solid lesions in segment 6 and 4A are respectively measuring up to 3.2 cm and 2.9 cm. Our patient proceeded to have further staging scans which did not reveal any metastatic depositions to the chest, head, and neck.

**Author:** MBBS, Master of Traumatology (MoT), Emergency Department, Mater Public Hospital, Raymond Terrace, South Brisbane, Australia.  
e-mail: sajansri12@gmail.com





*Figure 1:* Axial slice of the abdomen noting large conglomerate mass located centrally with significant displacement of the left kidney and the small bowels. This mass measures up to 25.4 x 22.8cm in transverse directions



*Figure 2:* Coronal slice of the abdomen noting same mass with significant displacement of the bowels. A hypodense lesion can be visualised on the liver

Histopathology presented sheets of polygonal cells with substantial clear cytoplasm and vesicular nuclei, with dispersed lymphocyte-rich septa. Immunohistochemistry revealed that the tumor cells are positive for PLAP, OCT3/4 and CD117 and negative for SOX10. Hence, this histologic evaluation was deemed to be consistent with the diagnosis of metastatic seminoma for our patient.

The current oncologic diagnosis of this patient is stage IIIc seminoma. The oncologic history is pure

seminoma PT1bNx with left orchiectomy in 2021. The tumor markers for this admission are alpha-fetoprotein (AFP) at 4.4, Lactate dehydrogenase (LDH) at 1230, and beta-human chorionic gonadotropin ( $\beta$ -hCG) at 38. He was admitted under the oncology team and started chemotherapy. He has been scheduled for 4 cycles of chemotherapy and is currently on bleomycin, etoposide, and platinum (BEP) therapy.

## II. DISCUSSION

This is a unique case of a patient presenting with abdominal distension. Abdominal distension is a common presentation to the emergency department and has a wide range of differentials (9). It is important to obtain a thorough medical history and physical examination of the patients before requesting an investigation. This patient had a left orchiectomy in 2021 and was noted to miss most of his follow-up appointments. It is important to consider imaging of these subset of patients with oncological history and has been more routinely performed in the emergency department in recent years.

Seminomas are germ cell tumors that account for up to 50% of all testicular tumors (10). These tumors metastasize within the lymphatic system with the retroperitoneal lymph nodes being the most common sites (10). The risk factors for seminomas are cryptorchidism (3), family history of testicular cancer (4), prior history of testicular cancer (1) and testicular trauma (6). This patient has a prior history of testicular cancer. His AFP was within normal levels, which is consistent with seminoma. His LDH was 1230 which is 2.5-fold above the upper normal limit for LDH.

One third of seminoma patients present with metastatic disease (10). There are different chemotherapy medications and regimens currently in use to manage this condition. This patient is currently on treatment with BEP. BEP was studied in a randomized control trial in 1980 against cisplatin, vinblastine, and bleomycin (PVB) (11). This study had a total of 244 patients, with 121 patients treated with BEP compared to 123 in PVB. 74% of patients with PVB became disease-free compared to 83% with BEP therapy. Neuromuscular toxicity was significantly less in BEP than that of PVB, favoring BEP therapy.

The results from the Internationalgerm-cell cancer collaborative group (IGCCG) compared the current data to that of original data from the 1980s for metastatic seminoma (10). The progression free survival rate (PFS) has improved from 82 to 89% with a 95% confidence interval between 87 to 90% with BEP therapy in favor of the current data. The 5-year overall survival rate in the modern series is 95% to that of 86% in the 1980s with confidence interval between 94 to 96% in patients with a good prognosis. For intermediate prognosis, the overall survival has improved from 72% to 88% with 95% confidence interval between 80-93%.

LDH has been recommended for assessment of the prognostic factor for seminoma cancer. Patients with good prognosis with LDH 2.5-fold above the normal limit had a 3-year progression free survival rate of 80% and overall survival of 92%. Patients with lower LDH level are noted to have a progression free survival rate of 92% and overall survival of 97% (10). This patient will be classed poor prognosis given the abdominal metastasis

with LDH levels 2.5-fold above the normal upper limit. His current estimated 2-year survival rate is 36% with 95% confidence interval between 12-60%.

Most testicular cancers exist as a mass localized to the testicle and thereby presents as a painless testicular mass which can progress to a significant size. With early diagnosis and effective management, patients can expect to lead a good quality of life following treatment. However, this patient reported poor attendance in follow up consultations after their testicular cancer diagnosis and orchidectomy in 2021. This resulted in a significant palpable metastatic mass present in their abdominal region as the initial manifestation from testicular seminoma confirmed via CT scan and histological assessment. This patient is currently on bleomycin, etoposide, and platinum (BEP) therapy and is scheduled for four cycles of chemotherapy.

## III. CONCLUSION

Testicular seminoma is a common malignancy amongst young men between the ages of 15 and 45 years old (2). Most patients will not experience obvious symptoms. However, there may be a subset of patients experiencing less common symptomatology such as abdominal and back pain. Perhaps young men experiencing regular, painful bouts of abdominal pain should also be considered for testicular cancer especially if the patient has a history of testicular malignancy.

## ACKNOWLEDGEMENT

### *Funding Statement*

This research received no specific grant from any funding agency in the public, commercial, or not-for-profit sectors.

### *Conflict of Interest*

The authors declare no conflict of interest in preparing this article.

## REFERENCES RÉFÉRENCES REFERENCIAS

- Gaddam SJ, Chesnut GT. Testicle Cancer. Stat Pearls. Treasure Island (FL): StatPearls Publishing Copyright © 2023, Stat Pearls Publishing LLC.; 2023.
- Park JS, Kim J, Elghiaty A, Ham WS. Recent global trends in testicular cancer incidence and mortality. *Medicine (Baltimore)*. 2018;97(37):e12390.
- Ferguson L, Agoulnik AI. Testicular cancer and cryptorchidism. *Front Endocrinol (Lausanne)*. 2013;4:32.
- Del RiscoKollerud R, Ruud E, Haugnes HS, Cannon-Albright LA, Thoresen M, Nafstad P, et al. Family history of cancer and risk of paediatric and

- young adult's testicular cancer: A Norwegian cohort study. *Br J Cancer*. 2019;120(10):1007-14.
5. Garolla A, Vitagliano A, Muscianisi F, Valente U, Ghezzi M, Andrisani A, et al. Role of Viral Infections in Testicular Cancer Etiology: Evidence From a Systematic Review and Meta-Analysis. *Front Endocrinol (Lausanne)*. 2019;10:355.
  6. Haughey BP, Graham S, Brasure J, Zielezny M, Sufrin G, Burnett WS. The epidemiology of testicular cancer in upstate New York. *Am J Epidemiol*. 1989;130(1):25-36.
  7. Depue RH, Pike MC, Henderson BE. Estrogen exposure during gestation and risk of testicular cancer. *J Natl Cancer Inst*. 1983;71(6):1151-5.
  8. Testicular cancer: Causes, symptoms & treatments [Internet]. [cited 2023 May 26]. Available from: <https://www.cancer.org.au/cancer-information/types-of-cancer/testicular-cancer>
  9. Mari A, Abu Backer F, Mahamid M, Amara H, Carter D, Boltin D, et al. Bloating and Abdominal Distension: Clinical Approach and Management. *Adv Ther*. 2019;36(5):1075-84.
  10. Beyer J, Collette L, Sauvé N, Daugaard G, Feldman DR, Tandstad T, et al. Survival and New Prognosticators in Metastatic Seminoma: Results From the IGCCCG-Update Consortium. *J Clin Oncol*. 2021;39(14):1553-62.
  11. Williams S D, Birch R, Irwin L, Greco A, Loehrer P J, Einhorn L H. *N Engl J Med*. 1987;316:1435–1440.